

## An 'early repolarisation' challenge

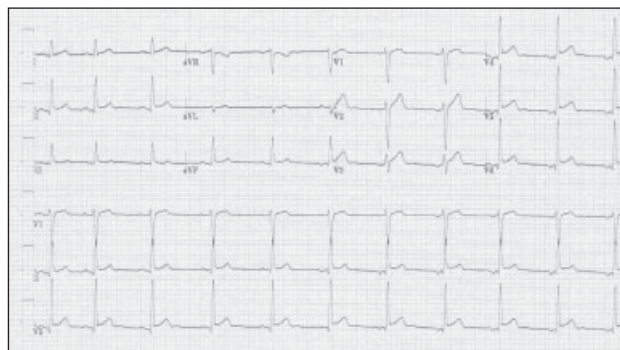
A 21-year-old male presented to the cardiology out-patient department with a 2-day history of non-radiating, stabbing pain in the left inframammary zone that started while he was cutting down a tree. The patient had no significant medical history, smoked 15 cigarettes per day, and had no other cardiovascular risk.

On arrival, the patient's blood pressure was 120/72 mm Hg with a pulse of 64 beats per minute. The pain was still sharp, had the same location, and was made worse by palpation and by abduction of the left arm. Changing posture had no effect: in particular, his symptoms were no worse in a supine position. The physical examination was otherwise unremarkable.

An electrocardiogram (ECG) displayed sinus arrhythmia and diffuse ST elevation, more evident in the inferior limb leads and precordial leads V4 through V6 (Fig). Acute coronary syndrome was unlikely in the presence of this type of chest pain. The presence of diffuse, concave ST elevation also made the diagnosis of acute myocardial infarction unlikely. Acute pericarditis was excluded on the grounds that pain was restricted to the left inframammary zone, was associated with vigorous physical activity, did not worsen in a recumbent position, and that on the ECG there was no depression of the PR segment (below the TP segment). After considering all these options, the patient was diagnosed with early ST segment repolarisation with musculoskeletal chest pain.

Early repolarisation of the ST segment is an electrocardiographic variant with a benign long-term prognosis.<sup>1</sup> Its prevalence has been estimated at between 1 and 5% of healthy adults<sup>2</sup> and it is more common in young athletic men.<sup>3</sup> The mechanism of early repolarisation is not completely understood; although accumulating evidence suggests a vagal origin.<sup>2,4</sup>

Closer examination of the rhythm strip from lead II of our patient (Fig) revealed that during sinus arrhythmia, as the heart rate slowed, the P waves became gradually inverted. The PR interval was 0.18 second with the upright P wave, shortened to 0.12 second with the inverted P wave. This phasic variation in cycle length with a varying P wave contour suggested a shift in pacemaker site and is characteristic of a wandering pacemaker, a normal phenomenon that often occurs in young people,



**Fig. The electrocardiogram shows sinus arrhythmia with a rate of about 64 beats per minute and diffuse ST elevation**

particularly athletes, presumably due to augmented vagal tone.<sup>5</sup>

No other investigations were performed. The patient was prescribed a 3-day course of acetaminophen and diclofenac, and the pain slowly improved. An ECG performed 1 month later was unchanged.

L Mascitelli, MD  
(e-mail: lumasci@libero.it)  
Sanitary Service  
Comando Brigata alpina "Julia", Udine, Italy  
F Pezzetta, MD  
Cardiology Service  
Ospedale di S. Vito al Tagliamento  
S. Vito al Tagliamento, Italy

### References

1. Klatsky AL, Oehm R, Cooper RA, Udaltsova N, Armstrong MA. The early repolarization normal variant electrocardiogram: correlates and consequences. *Am J Med* 2003;115:171-7.
2. Mehta MC, Jain AC. Early repolarization on scalar electrocardiogram. *Am J Med Sci* 1995;309:305-11.
3. Bjornstad H, Storstein L, Meen HD, Hals O. Electrocardiographic findings of repolarization in athletic students and control subjects. *Cardiology* 1994;84:51-60.
4. Haydar ZR, Brantley DA, Gittings NS, Wright JG, Fleg JL. Early repolarization: an electrocardiographic predictor of enhanced aerobic fitness. *Am J Cardiol* 2000;85:264-6.
5. Olgin JE, Zipes DP. Specific arrhythmias: diagnosis and treatment. In: Braunwald E, Zipes DP, Libby P, editors. *Heart disease. A textbook of cardiovascular medicine*. 6th ed. Philadelphia, Pennsylvania: WB Saunders; 2001:815-89.