

SF Hon 韓溯飛  
 GKC Wong 黃國柱  
 XL Zhu 朱獻倫  
 HK Ng 吳浩強  
 NC Sin 冼藝泉  
 WS Poon 潘偉生

## Surgical treatment of a neonate with refractory seizures secondary to congenital giant cell astrocytoma: case report and literature review

### 以手術治療一名因先天巨型星細胞瘤引致頑固癲癇症的初生嬰兒：病例報告及文獻回顧

Congenital brain tumours are rare. They account for 0.5% to 1.9% of intracranial tumours in childhood and have an incidence of 0.34 per million live births. Most congenital brain tumours are neuro-ectodermal tumours and medulloblastomas; giant cell astrocytoma and other tuberous sclerosis-related tumours are rare. We report on a neonate who developed seizures that were refractory to medical treatment. Imaging studies revealed a right frontal calcified tumour. Surgical resection was performed successfully and pathology revealed the tumour to be a giant cell astrocytoma. The child was seizure-free afterwards.

先天性腦腫瘤是十分罕見的疾病，只佔兒童顱腫瘤的0.5%至1.9%，每一百萬名初生嬰兒中只有0.34宗。大部分的先天腦腫瘤屬於神經表皮細胞瘤和髓質腦細胞瘤，而巨型星細胞瘤和其他結節性硬化瘤出現的可能性很低。本文報告一名初生嬰兒患上藥物無法治療的癲癇症，造影檢查發現其右前額有鈣化瘤，後來以手術成功切除該瘤，而病理學檢驗發現其為一個巨型星細胞瘤。手術後該嬰兒不再出現癲癇徵狀。

#### Key words:

*Astrocytoma;*  
*Infant, newborn;*  
*Seizures;*  
*Tuberous sclerosis*

#### 關鍵詞：

星細胞瘤；  
 嬰兒，新生；  
 癲癇；  
 結節性硬化

*Hong Kong Med J 2006;12:222-4*

The Chinese University of Hong Kong,  
 Prince of Wales Hospital, Shatin, Hong  
 Kong:

#### Division of Neurosurgery

SF Hon, MB, ChB  
 GKC Wong, FRCS (Edin)  
 XL Zhu, FRCS (Edin)  
 WS Poon, FRCS (Glasg)

#### Department of Anatomical and Cellular Pathology

HK Ng, FRCPath

#### Department of Paediatrics

NC Sin, MRCPaed

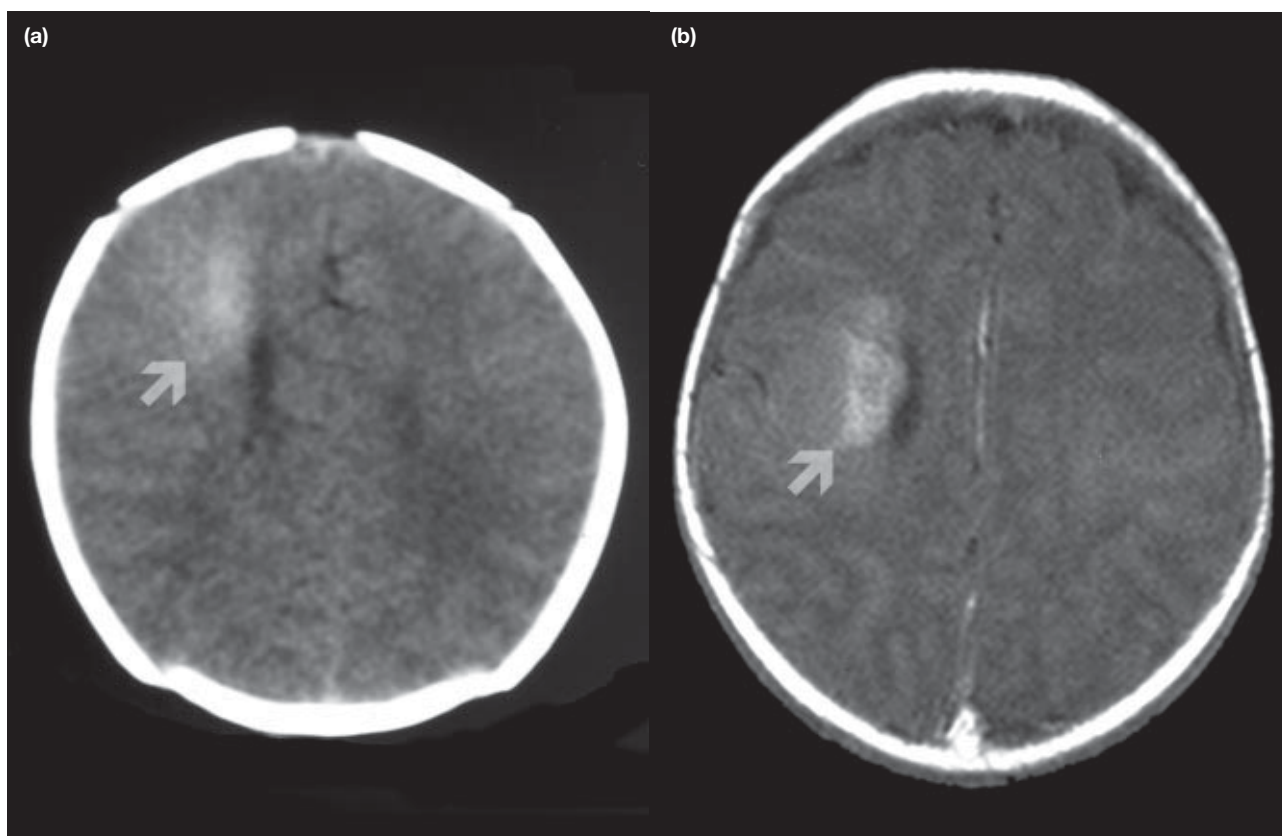
Correspondence to: Prof WS Poon  
 (e-mail: wpoon@surgery.cuhk.edu.hk)

#### Introduction

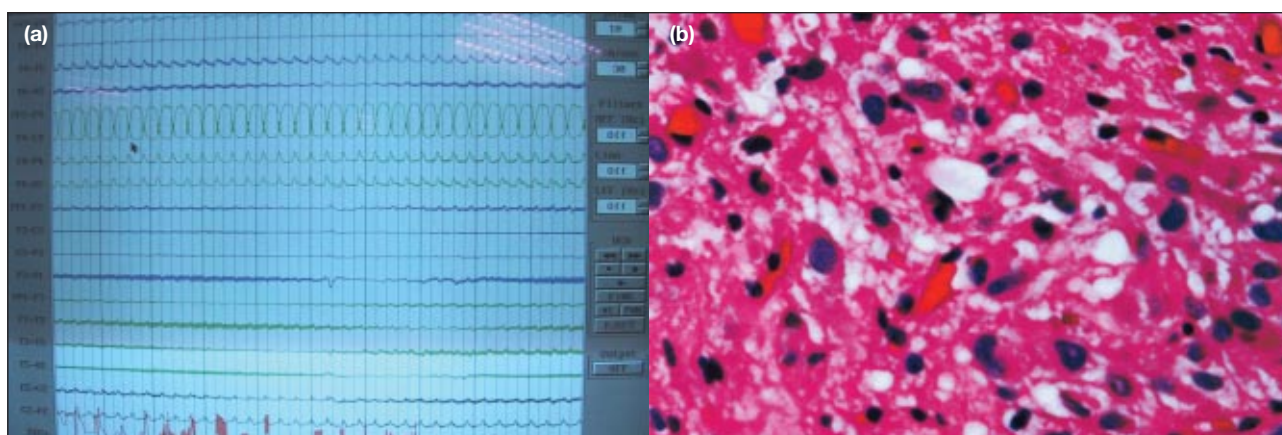
Giant cell astrocytoma is a benign tumour and one of the primary features of tuberous sclerosis. Neonatal presentation is rare. We report the management of a neonate with seizures that commenced on day 1 after birth and were refractory to medical treatment.

#### Case report

The female neonate was delivered at full term by Caesarian section under spinal anaesthesia in October 2002. She was the second child of the family and weighed 2.65 kg. There was no maternal history of drugs, smoking, alcohol, or teratogenic exposure. No dysmorphic features or dermatological stigmata were found. The patient developed the first seizure 6 hours after delivery. Most seizures began with bilateral clonic movements of the upper limbs that spread to involve the lower limbs. They were difficult to categorise but were generalised seizures. They occurred daily in the first 5 weeks of life and developed into status epilepticus at 5 weeks of age. Urgent computed tomographic brain imaging on day 1 after birth revealed a wedge-shaped right fronto-parietal hyperdense lesion without mass effect or perifocal oedema and with normal ventricles (Fig 1a). Magnetic resonance imaging (MRI) of the brain on day 3 showed a T1 hyperintense lesion, and T2 hypointense lesion at the same region with no significant enhancement, and negative for haemosiderin (Fig 1b). An electroencephalogram demonstrated epileptic discharges over the corresponding area (Fig 2a). A tumour mass with calcification foci was suspected. She was anaesthetised with intravenous thiopentone (7 mg/kg per day) at 5 weeks of age when she developed status epilepticus. Seizures had previously been unsuccessfully



**Fig 1. (a) Plain computed tomogram showing right frontal hyperintensity (arrow); and (b) magnetic resonance image showing non-enhancing right frontal lesion and with no evidence of haemorrhage (arrow)**



**Fig 2. (a) Ictal electroencephalogram and (b) section of tumour showing numerous large astrocytes, occasionally binucleated, with glassy eosinophilic cytoplasm and coarse fibres; dystrophic calcification was seen in the neuropil (H&E, x 150)**

managed with phenobarbitone 7 mg/kg per day and carbamazepine 17 mg/kg per day. The electroencephalogram showed a burst suppression pattern with occasional seizures, although there were no further clinical seizures. In view of the intractable nature of the seizures despite maximal antiepileptic medication, and the difficulty of diagnosis, elective surgery was performed at 6 weeks of age for seizure control and pathological diagnosis. Her condition on thiopentone was stable. She was intubated

and ventilated, and treated empirically for sepsis. There was no evidence of pneumonia. A right fronto-parietal craniotomy was performed and the area of the lesion was located by ultrasound. Epileptic activity was recorded over and around the lesion using strip electrode electrocorticography (ECoG). The tumour-associated gyrus and peri-lesional tissue were excised under ECoG guidance. The excision margin was grossly clear. The pathological diagnosis was a right frontal giant cell astrocytoma.

Microscopic examination revealed that the tumour had apparently arisen from large clusters of highly dysplastic cells in the cortex. The tumour was not a subependymal giant cell astrocytoma (SGCA) and not considered tuberous sclerosis-related since it was close to the ventricle but did not protrude into the lumen. The World Health Organization grading was grade I (Fig 2b).

Her postoperative recovery was uneventful. One episode of seizure was detected on day 15 postoperatively but none thereafter. She continued receiving maintenance doses of lamotrigine, tegretol, and phenobarbitone. A postoperative MRI of the brain showed no residual or recurrent tumour with global cerebral atrophy. She was discharged from hospital 2 months after surgery and referred for special training and assessment. She was nearly 3 years of age (2 years 11 months) at the last follow-up and weighed 10 kg. Maintenance therapy consisted of lamotrigine 10 mg every morning and 15 mg at night. She had experienced only one breakthrough seizure in the prior 6 months. She had spastic tetraparesis. She could turn but was unable to sit unsupported. She could make verbal responses but demonstrated no visual fixation. Marked visual impairment was suspected.

## Discussion

Congenital brain tumours are rare. They account for 0.5% to 1.9% of intracranial tumours in childhood with an incidence of 0.34 per million live births.<sup>1</sup> The majority of such tumours are neuro-ectodermal tumours and medulloblastomas; giant cell astrocytoma or other tuberous sclerosis-related tumours are rare. Maternal exposure to teratogens during gestation (such as radiation and drugs) is a major risk factor for congenital brain tumours. In more than half of all cases, the clinical presentation consists of macrocephaly and symptoms/signs of raised intracranial pressure such as bulging fontanelles. Subependymal giant cell astrocytomas account for 1.5% of paediatric brain tumours.<sup>2</sup> The first two cases of SGCA were reported in 1984 and only 10 cases of neonatal SGCA have since been reported.<sup>3-5</sup> Systematic epidemiological review is thus not possible. Tuberous sclerosis is usually diagnosed in late childhood when most of the cutaneous diagnostic criteria have become evident.<sup>6</sup>

The typical findings of giant cell astrocytoma in tuberous sclerosis on MRI are hypointensity on the T1-weighted image and hyperintensity on the T2-weighted image with contrast enhancement. The lesion usually lies adjacent to the foramen of Monro with heterogeneous calcification and causes obstruction. However, in neonates the findings may be atypical with hyperintensity on the T1 image and hypointensity on the T2 image. Stricker et al<sup>7</sup> suggested that this was due to the higher water concentration in the immature brain, hypercellularity of the tumour,

and calcification. The case presented here differed in the tumour location and the lack of mass effect and preserved ventricles.

Surgery on neonates with brain tumours is a high-risk procedure due to the danger of profuse bleeding from vascular tumours. Patients rarely survive the perioperative period. In five neonates with giant cell astrocytomas who were treated surgically, only two survived and seizures persisted.<sup>2,4,5,8</sup> Global developmental delay may be part of the disease nature of tuberous sclerosis. Nonetheless hypoxic brain damage as a result of recurrent seizures may also have a significant impact.

Surgical excision has been proposed to offer the best seizure control in patients with single tubers.<sup>4,9,10</sup> In a review of 105 patients with tuberous sclerosis, Cuccia et al<sup>11</sup> concluded that seizure and mental retardation could be improved after surgery without significant morbidity. More aggressive and early surgery promoted a long seizure-free survival. Developmental delay was likely to be due to repeated seizures and, later, status epilepticus.

In general, surgery for neonatal brain tumours should be deferred until after the neonatal period to reduce surgical risk. However, in cases such as this one, where seizure control is not possible, earlier surgery is indicated. A much better functional outcome might have resulted.

## References

1. Cavaleiro S, Moron AF, Hisaba W, Dastoli P, Silva NS. Fetal brain tumors. *Childs Nerv Syst* 2003;19:529-36.
2. Shepherd CW, Scheithauer BW, Gomez MR, Altermatt HJ, Katzmann JA. Subependymal giant cell astrocytoma: a clinical, pathological, and flow cytometric study. *Neurosurgery* 1991;28:864-8.
3. Oikawas S, Sakamoto K, Kobayashi N. A neonatal huge subependymal giant cell astrocytoma: case report. *Neurosurgery* 1994;35:748-50.
4. Palmini A, Andermann F, Olivier A, et al. Focal neuronal migration disorders and intractable partial epilepsy: a study of 30 patients. *Ann Neurol* 1991;30:741-9.
5. Ramenghi LA, Verrotti A, Domizio S, Di Rocco C, Morgese G, Sabatino G. Neonatal diagnosis of tuberous sclerosis. *Childs Nerv Syst* 1996;12:121-3.
6. Boessel CP, Paulson GW, Kosnik EJ, Earle KM. Brain hamartomas and tumors associated with tuberous sclerosis. *Neurosurgery* 1979;4:410-7.
7. Stricker T, Zuerrer M, Martin E, Boesch C. MRI of two infants with tuberous sclerosis. *Neuroradiology* 1991;33:175-7.
8. Medhkour A, Traul D, Husain M. Neonatal subependymal giant cell astrocytoma. *Paediatr Neurosurg* 2002;36:271-4.
9. Avellino AM, Berger MS, Rostomily RC, Shaw CM, Ojemann GA. Surgical management and seizure outcome in patients with tuberous sclerosis. *J Neurosurg* 1997;87:391-6.
10. Guerreiro MM, Andermann F, Andermann E, et al. Surgical treatment of epilepsy in tuberous sclerosis: strategies and results in 18 patients. *Neurology* 1998;51:1263-9.
11. Cuccia V, Zuccaro G, Sosa F, Monges J, Lubieniek F, Taratuto AL. Subependymal giant cell astrocytoma in children with tuberous sclerosis. *Childs Nerv Syst* 2003;19:232-43.