

Renal artery pseudoaneurysm following renal transplantation and treatment by percutaneous thrombin injection

A 26-year-old male patient with end-stage renal disease secondary to diabetic nephropathy received his first cadaveric renal transplant in Mainland China in March 2004. The graft renal artery was anastomosed to the right external iliac artery. Prophylactic immunosuppressive therapy consisted of tacrolimus, mycophenolate mofetil, and prednisolone. He experienced no acute rejection that required renal graft biopsy. Nonetheless, renal allograft function was impaired by a combination of pyelonephritis and cytomegalovirus infection. Three months post-transplant, serum creatinine level remained at around 400 $\mu\text{mol/L}$ (reference range, 53-106 $\mu\text{mol/L}$). Doppler study of the graft kidney showed a 1.9-cm cavity with to-and-fro flow near the origin of the renal artery consistent with a pseudoaneurysm. One month later, follow-up ultrasonography (USG) revealed that the pseudoaneurysm had increased to 2.3 cm in size. Subsequent magnetic resonance angiography confirmed the diagnosis of pseudoaneurysm that had continued to enlarge and measured 2.5 cm x 3 cm in cross-section.

Angiogram study just prior to intervention showed a 4-cm bilobed pseudoaneurysm arising from the main trunk of the graft renal artery 3 cm distal to the anastomosis, and just proximal to the pre-polar bifurcation, compressing the segmental branches and the external iliac artery (Figs 1, 2). A 6 mm x 3 cm stainless steel stent (Bridge Assurant; Metronic AVE Inc, Santa Rosa, US) was deployed to the renal artery to improve circulation, and protecting it from a shower of emboli during thrombin injection. The pseudoaneurysm was then approached percutaneously with a 22G Chiba echotip needle under USG guidance. Thrombin was then injected to thrombose the pseudoaneurysm. A total of 0.8 mL of thrombin (500 IU/mL, Tissel Kit; Baxter AG, Vienna, Austria) was administered and complete thrombosis of the pseudoaneurysm achieved (Fig 3). Although the central lumen connecting the pseudoaneurysm to the renal artery was recanalised 1 month later as shown on repeated computed tomographic scan, the periphery of pseudoaneurysm remained thrombosed, protecting it from rupture. Post-intervention serum creatinine level remained stable at approximately 400 $\mu\text{mol/L}$.

Discussion

Post-transplant intrarenal pseudoaneurysms are usually secondary to needle biopsy of the graft kidney. Extrarenal pseudoaneurysms have been attributed to infection or vascular anastomosis defects.¹ The clinical presentation varies from asymptomatic lesions found incidentally

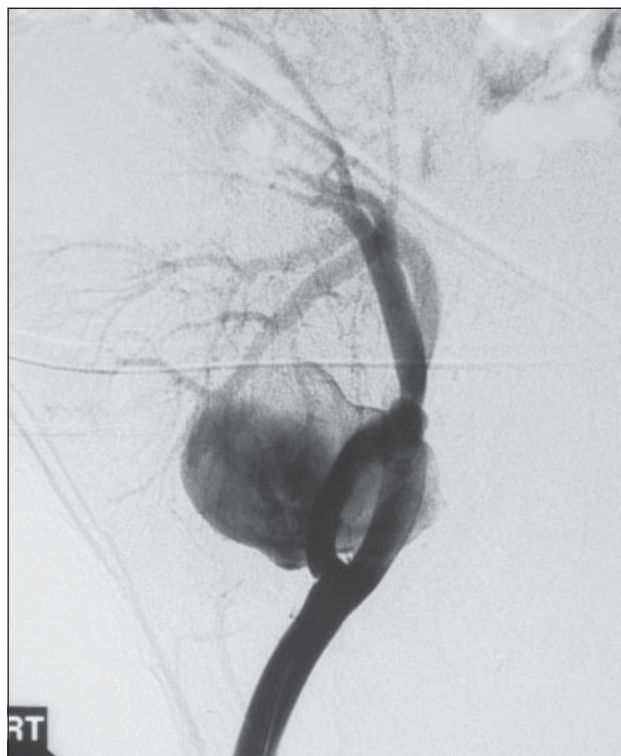


Fig 1. Angiogram of the graft kidney showing a bilobed pseudoaneurysm with the neck 3 cm from the origin of the arterial anastomosis

on imaging study to painful pulsating masses that, if large enough, may cause pressure effects on surrounding structures causing plexopathy, graft hydronephrosis, or even rupture.

Small extrarenal pseudoaneurysms can be managed conservatively while large or progressively enlarging ones, such as that in this patient, require intervention. The outcome for large extrarenal pseudoaneurysms is disappointing. In one study, 28% of patients required graft nephrectomy and 40% resulted in 30% to 50% renal infarction.² In our patient, the use of an endovascular cover-stent graft was not feasible because of an anticipated substantial allograft infarction due to occlusion of the polar arteries. The use of trans-catheter coil embolisation in renal transplant patients has been reported to be associated with high complication rates. Ultrasonography-guided percutaneous needle injection of thrombin (USG-PT) has been used successfully in femoral iatrogenic pseudoaneurysms with a success rate ranging from 97% to 100% for simple lesions to 61% for complex ones.³ Its use in post-renal transplant pseudoaneurysm

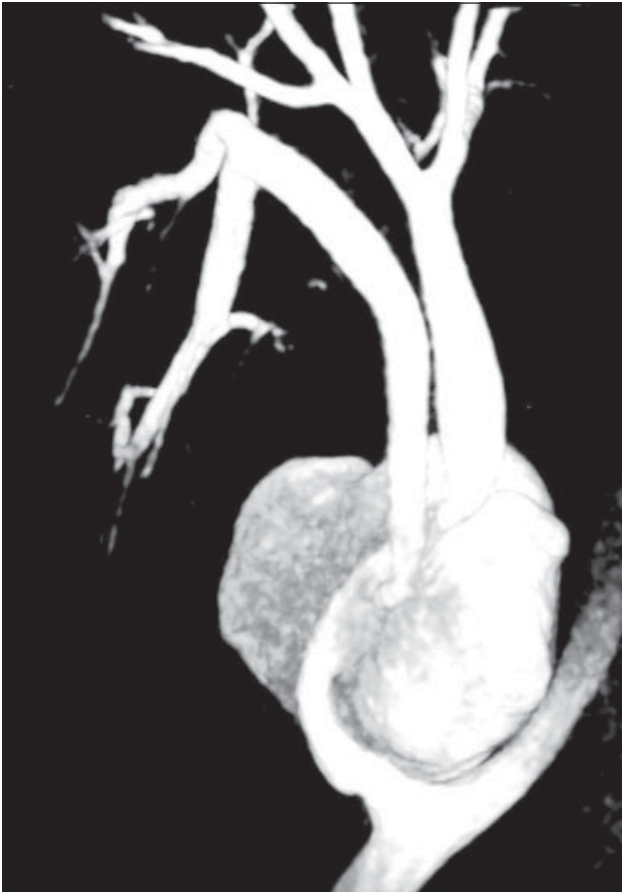

Fig 2. Three-dimensional angiogram with shaded surface display outlining the pseudoaneurysm that was compromising the arterial flow to the renal arterial branches

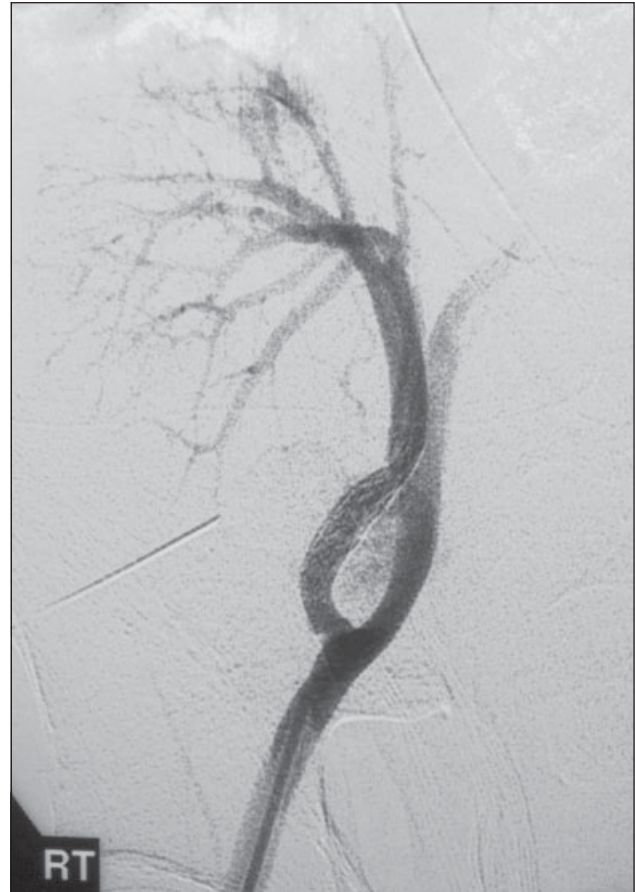


Fig 3. Post-thrombin injection angiogram showing almost complete thrombosis of the pseudoaneurysm

is less well described. This may be related to the consideration of its potential risk of distal embolisation to the graft kidney causing infarction. Nonetheless this hazard can be minimised by careful positioning of the injection needle under adequate colour duplex ultrasonography guidance and injection of small amounts of thrombin during each session.^{1,4}

We demonstrated the successful use of USG-PT in the management of post-renal transplant pseudoaneurysm with maintenance of renal function. This appears to be a safe and effective alternative in the treatment of post-renal transplant pseudoaneurysm.

YP Siu, MRCP, FHKAM (Medicine)
 MKH Tong, MRCP, FHKAM (Medicine)
 (e-mail: khmtong@netvigator.com)
 KT Leung, MRCP, FHKAM (Medicine)
 TH Kwan, FRCP, FHKAM (Medicine)

TC Au, FRCP, FHKAM (Medicine)
 Department of Medicine
 YK Cheung, FRCR, FHKAM (Radiology)
 SH Luk, FRCR, FHKAM (Radiology)
 Department of Radiology
 Tuen Mun Hospital, Tuen Mun, Hong Kong

References

1. Luzzio CC, Waclawik AJ, Gallagher CL, Knechtle SJ. Iliac artery pseudoaneurysm following renal transplantation presenting as lumbosacral plexopathy. *Transplantation* 1999;67:1077-8.
2. Dorffner R, Thurnher S, Prokesch R, et al. Embolization of iatrogenic vascular injuries of renal transplants: immediate and follow-up results. *Cardiovasc Intervent Radiol* 1998;21:129-34.
3. Kruger K, Zahringer M, Sohngen FD, et al. Femoral pseudoaneurysms: management with percutaneous thrombin injections—success rates and effects on systemic coagulation. *Radiology* 2003;226:452-8.
4. Ghersin E, Karram T, Gaitini D, et al. Percutaneous ultrasonographically guided thrombin injection of iatrogenic pseudoaneurysms in unusual sites. *J Ultrasound Med* 2003;22:809-16.