

TS Tse 謝德新
 KL Tsui 徐健霖
 LC Ling 林良釗
 WH Chui 崔永雄
 MC Choi 蔡文俊
 SK Li 李樹堅
 CSW Chiu 趙瑞華

Necrotic cardiac haemangioma masquerading as sepsis with disseminated intravascular coagulation

呈有分散性血管凝固和膿毒症徵狀的壞死心臟血管瘤

Cardiac haemangiomas are exceptionally rare benign vascular tumours. We report a case of cardiac haemangioma presenting with pyrexia of unknown origin and clinical features simulating sepsis with disseminated intravascular coagulation. The clinical course was complicated by systemic embolism.

心臟血管瘤是一種極為罕見的良性血管腫瘤。本文報告一名心臟血管瘤患者有起因不明的發熱，以及跟分散性血管凝固和膿毒症類似的臨床徵狀，並在治療過程中出現彌漫性動脈栓塞的併發症。

Case report

A 57-year-old man presented with a 2-day history of fever and gastrointestinal symptoms of vomiting and diarrhoea. He had previously enjoyed good health. Three days prior to admission, a finger prick on some fish scales resulted in local inflammation. Physical examination, including cardiovascular and abdominal examination, was otherwise normal. Blood investigations showed an elevated white blood cell count ($12.5 \times 10^9 /L$), and low platelet count ($20 \times 10^9 /L$) with evidence of disseminated intravascular coagulation (prolonged activated partial thromboplastin time and raised D-dimer level). Serum C-reactive protein was markedly elevated (highest level of 144 mg/L). He was treated for sepsis with intravenous ciprofloxacin and penicillin: the regimen was chosen to cover rare fish pathogens. Clotting profile and platelet count improved over the next 6 days, although fever persisted despite 2 weeks of antibiotic therapy. Septic workup including repeated blood and stool cultures was negative.

The patient suffered a minor stroke during his hospital stay. Computed tomography of the brain showed bilateral, multiple hypodensities over the right basal ganglia and left parietal lobe. This suggested a cardiac source of emboli. Transthoracic echocardiogram revealed a 3 x 3 cm polypoid mass occupying the whole left ventricular apex extending towards the left ventricular outflow tract. Computed tomography of the thorax showed a left intraventricular lesion with intralesional calcification. No significant contrast enhancement of the mass was noted. Coronary angiogram, performed to delineate its blood supply, revealed an occluded distal left anterior descending artery with no obvious tumour contrast blush identified (Fig 1).

The patient underwent open-heart surgery. Intra-operative transoesophageal echocardiography showed the left ventricular mass extend-

Key words:

Disseminated intravascular coagulation;
 Heart neoplasms;
 Hemangioma;
 Sepsis

關鍵詞：

分散性血管凝固；
 心臟瘤；
 血管瘤；
 膿毒症

Hong Kong Med J 2005;11:308-10

Department of Medicine, Pamela Youde Nethersole Eastern Hospital, Chai Wan, Hong Kong

TS Tse, MRCP, FHKAM (Medicine)

KL Tsui, FRCP, FHKAM (Medicine)

MC Choi, MB, ChB, MRCP

SK Li, FRCP, FHKAM (Medicine)

Grantham Hospital, 125 Wong Chuk Hang Road, Aberdeen, Hong Kong:

Department of Anaesthesia

LC Ling, FANZCA, FHKAM (Anaesthesiology)

Department of Cardiothoracic Surgery

WH Chui, FRCS (Edin), FHKAM (Surgery)

CSW Chiu, FRCS (Edin), FHKAM (Surgery)

Correspondence to: Dr TS Tse
 (e-mail: tsetaksun@gmail.com)

ing to the aorta during systole (Fig 2a). Through a median sternotomy approach and with the aid of hypothermic cardiopulmonary bypass, the left ventricle was inspected via left atriotomy and transverse aortotomy. A friable and necrotic tumour mass was noted between the two papillary muscle bases (Fig 2b). The area around the papillary muscle and the apex of the left ventricle was firm and appeared infiltrated by the tumour. Only the friable part of the left ventricular tumour was excised. Histological examination disclosed a capillary haemangioma. No bacteria were identified on histology. Broth culture yielded methicillin-sensitive *Staphylococcus aureus* of uncertain clinical relevance. A course of cloxacillin was prescribed and fever gradually subsided over the next few days. The patient's recovery was then uneventful.

Discussion

Haemangiomas are benign vascular tumours composed of blood vessels that can be either small capillary-like vessels (capillary haemangiomas), large cavernous vascular channels (cavernous haemangiomas), or dysplastic malformed arteries and veins (arteriovenous haemangiomas).^{1,2} Their localisation to the heart is extremely rare: they account for only 5% of benign cardiac tumours and 1.7% of all cardiac tumours.³ These tumours can present at any age with a predilection for young adults and equal distribution between the sexes.³ Some tumours are asymptomatic and are discovered accidentally. Others are symptomatic with clinical features often influenced by their location within the heart.² In a review of 23 cases of cardiac haemangioma, Brizard et al¹ reported the most frequent clinical presentation as dyspnoea on exertion (43%), while other less frequent presentations included arrhythmias (17%), pseudoangina (14%), and signs of right heart failure (13%). Rarely, patients may present as pericarditis or pericardial effusion (8%), and failure to thrive (8%).¹ Our patient presented with a clinical picture of sepsis and disseminated intravascular coagulation, which, to the best of our knowledge, has not been previously reported. Systemic embolisation complicating cardiac haemangioma, although rare, has been reported.⁴

Preoperative diagnosis of cardiac haemangiomas is always difficult and could be established in only 34% of a previously reported series.¹ With the availability of new non-invasive imaging techniques, diagnosis of these lesions may now be more frequent. Enhanced contrast computed tomography or magnetic resonance imaging shows the vascular nature of the tumour and allows the physician to consider a diagnosis of cardiac

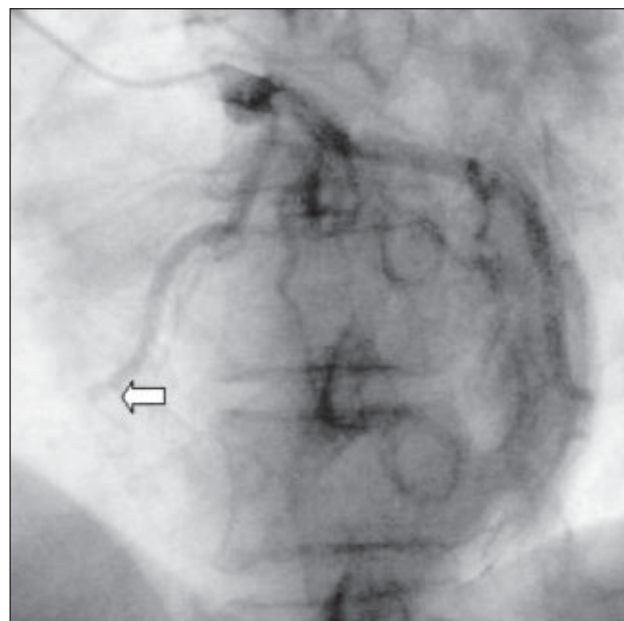


Fig 1. Coronary angiogram showing occlusion of the distal left anterior descending artery (arrow) with no obvious tumour contrast blush identified

haemangioma.¹ It also helps to evaluate the extent of extracardiac invasion and myocardial involvement.^{3,5} Coronary angiography often helps to establish the diagnosis by showing the characteristic tumour blush.⁶ In this patient, preoperative diagnosis was not established because of several atypical features. First, coronary angiography did not demonstrate vascular blush but an occluded distal left anterior descending artery. Second, the tumour did not demonstrate intense central contrast enhancement on computed tomography and this may have implied thrombosis of the haemangioma.

We postulated that the distal left anterior descending artery was the feeding artery to the tumour that was occluded by tumour emboli, concomitant coronary disease, or infiltration of the tumour, resulting in thrombosis of the cardiac haemangioma. This may also have accounted for the tumour necrosis that may have led to the presenting symptoms of fever and disseminated intravascular coagulation, and predisposed to tumour embolism that accounted for gastrointestinal symptoms and cerebrovascular event. An infected left ventricular haemangioma could be another cause of fever and disseminated intravascular coagulation. However, the repeatedly negative blood cultures and absence of identifiable bacteria on tissue made this less likely. Kasabach-Merritt syndrome, which is characterised by systemic haemangiomas associated with recurrent thrombocytopenia and consumptive coagulopathy, is another possible cause of disseminated intravascular coagulation.¹ Cardiac involvement in this syndrome has been reported.⁷

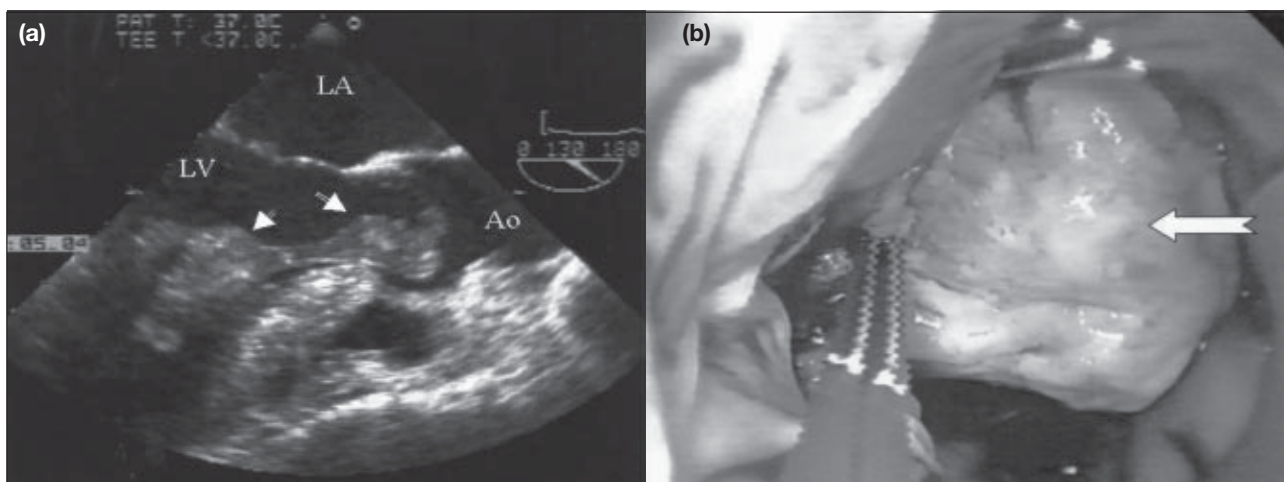


Fig 2. (a) Intra-operative transoesophageal echocardiogram showing a left ventricular mass (arrows) extending to the aorta during systole (Ao: aorta, LA: left atrium, and LV: left ventricle); **(b)** through a median sternotomy approach, the left ventricular mass (arrow) was noted arising between the two papillary muscle bases

The natural history of cardiac haemangiomas is unpredictable. Tumours may regress, cease growing, or proliferate over time.⁸ Complete resection of the tumour is considered curative and recommended,^{4,8} although may not be possible in up to 52% of cases.¹ Prognosis with or without complete tumour resection seems favourable.¹ Spontaneous regression of an unresectable large cavernous haemangioma has been reported.⁹ Regular echocardiographic follow-up examination is recommended to identify any recurrence of this exceedingly rare cardiac tumour.

References

1. Brizard C, Latremouille C, Jebara VA, et al. Cardiac hemangiomas. *Ann Thorac Surg* 1993;56:390-4.
2. Burke A, Johns JP, Virmani R. Hemangiomas of the heart. A clinicopathologic study of ten cases. *Am J Cardiovasc Pathol* 1990;3:283-90.
3. Tillett RL, Jiskoot PM, Glenville BE. Case report: cardiac hemangioma. *Heart Surg Forum* 2001;4:247-50.
4. Kipfer B, Englberger L, Stauffer E, Carrel T. Rare presentation of cardiac hemangiomas. *Ann Thorac Surg* 2000;70:977-9.
5. Manasse E, Nicolini F, Canziani R, Gallotti R. Left ventricular hemangioma. *Eur J Cardiothorac Surg* 1999;15:864-6.
6. Pigato JB, Subramanian VA, McCaba JC. Cardiac hemangioma. A case report and discussion. *Tex Heart Inst J* 1998;25:83-5.
7. Gengenbach S, Ridker PM. Left ventricular hemangioma in Kasabach-Merritt syndrome. *Am Heart J* 1991;121:202-3.
8. Lo LJ, Nucho RC, Allen JW, Rohde RL, Lau FY. Left atrial cardiac hemangioma associated with shortness of breath and palpitations. *Ann Thorac Surg* 2002;73:979-81.
9. Palmer TE, Tresch DD, Bonchek LI. Spontaneous resolution of a large, cavernous hemangioma of the heart. *Am J Cardiol* 1986;58:184-5.

Coming in the October 2005 issue of the *Hong Kong Medical Journal*

- Curative radiotherapy for early cancers of the lip, buccal mucosa, and nose—a simple interstitial brachytherapy technique employing angiocatheters as carriers for Iridium-192 wire implants
- Kawasaki disease in Hong Kong, 1994 to 2000
- The clinical outcome of 137 rape victims in Hong Kong