

SW Wong 王韶宏
 CKC Lai 黎建宗
 KF Lee 李傑輝
 PBS Lai 賴寶山

Granulocytic sarcoma of the small bowel causing intestinal obstruction

小腸的粒細胞肉瘤造成腸阻塞

Granulocytic sarcomas of the small bowel are rare. They are discrete tumours of leukaemic myeloblasts and partially matured granulocytes that form in any part of the body. This disease is infrequently seen in patients with acute myeloid leukaemia, and rarely seen in patients without leukaemia. Here we report a case of small bowel obstruction due to granulocytic sarcoma of mid-ileum in a non-leukaemic patient. We also review the literature on treatment and prognosis of this condition.

小腸長出粒細胞肉瘤是罕見的病例。這種可於身體各處形成的腫瘤，由白血病成髓細胞及半成熟粒細胞組織而成。這種病症並不常見於急性骨髓性白血病患者身上，於非白血病患者身上則更為罕見。本文報告一名非白血病患者因中迴腸長出粒細胞肉瘤引致小腸阻塞的病例，並回顧該病症的治療及預後方法。

Introduction

Granulocytic sarcoma (GS), also known as a chloroma or myeloblastoma, is a discrete tumour of leukaemic myeloblasts and partially matured granulocytes that can form in skin and soft tissue, periosteum, bone, lymph nodes, the gastrointestinal tract, pleura, and other parts of the body. These tumours can develop in patients with acute myeloid leukaemia (AML) or in the accelerated phase of chronic myeloleukaemia and rarely, may be the first manifestation of AML, preceding the onset in marrow and blood by months or years.^{1,2} Isolated involvement of the gastrointestinal tract is uncommon.

Case report

A 36-year-old man with good previous health was admitted to the Prince of Wales Hospital, Hong Kong in August 2003 with recurrent central colicky abdominal pain of 6-month duration. An abdominal X-ray showed dilated small bowel loops, suggestive of subacute intestinal obstruction. The symptoms subsided very soon after admission. Elective colonoscopy detected no abnormalities. Ultrasound of the abdomen showed non-specific thickening of the wall of the small bowel. Further investigation by small bowel enema revealed an obstructive lesion at mid-ileum (Fig 1). In view of these findings, surgical treatment was offered. However, the patient decided to seek a second opinion from the private sector and a computed tomographic scan of the abdomen was subsequently performed. This showed poor passage of oral contrast through the small bowel loops, with irregular small bowel wall thickening. An exploratory laparotomy was eventually performed in October 2003. During laparotomy, a tumour causing obstruction was found at mid-ileum (Fig 2). Multiple enlarged lymph nodes were also noted along the root of the superior mesenteric artery. Segmental resection of the tumour,

Key words:

*Intestinal neoplasms;
 Intestinal obstruction;
 Leukemia, myeloid;
 Sarcoma, granulocytic*

關鍵詞：

腸部腫瘤；
 腸阻塞；
 白血病，骨髓性；
 肉瘤，粒細胞的

Hong Kong Med J 2005;11:204-6

The Chinese University of Hong Kong,
 Prince of Wales Hospital, Shatin,
 Hong Kong:
 Department of Surgery
 SW Wong, MB, ChB
 KF Lee, FRCS (Edin)
 PBS Lai, FRCS (Edin), MD
 Department of Anatomical and Cellular
 Pathology
 CKC Lai, MB, ChB

Correspondence to: Dr PBS Lai
 (e-mail: paullai@cuhk.edu.hk)

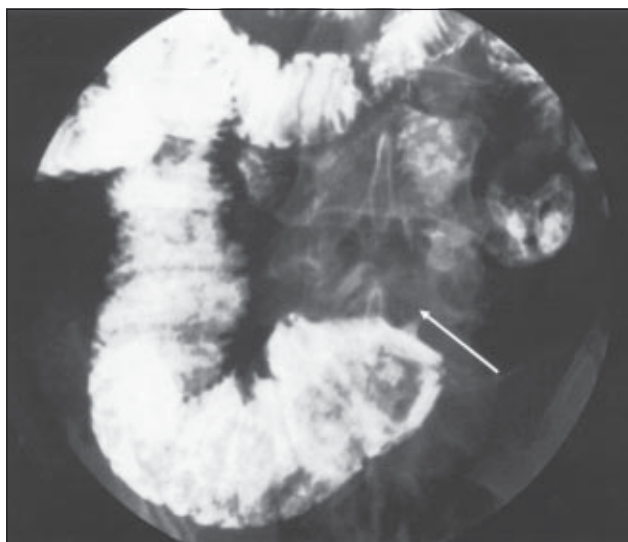


Fig 1. Small bowel enema showing a partially obstructing, annular lesion with bilateral shouldered ends at mid-ileum (arrow)

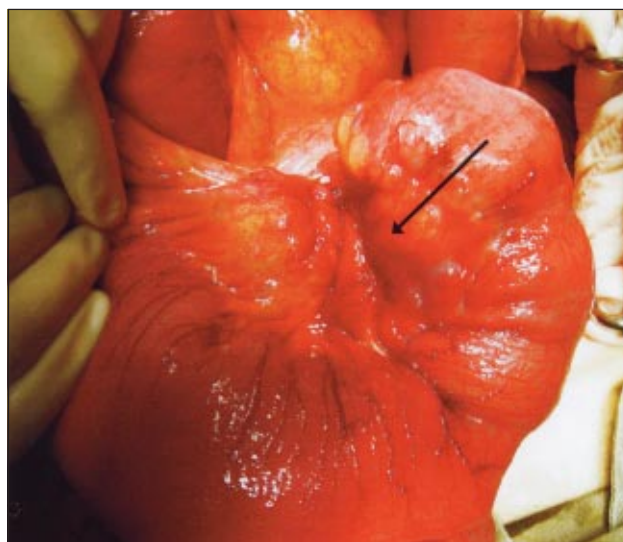


Fig 2. Extensive tumour (arrow) obstructing the small bowel and extending into the small bowel mesentery causing distension of the proximal small bowel

with primary small bowel anastomosis, was performed. The postoperative period was uneventful and the patient was discharged 6 days postoperatively.

Examination of the surgical specimen showed a pale, annular tumour which infiltrated and expanded the submucosa and subserosa. The tumour also extended into the small bowel mesentery directly. Histologically, the mucosa, submucosa, and the subserosa of the small intestine were markedly expanded by extensive infiltration of large, polyhedral tumour cells, with scattered eosinophils seen in the background. Immunohistochemically, the tumour cells were positive for myeloperoxidase (MPO), chloroacetate esterase, and leukocyte common antigen. T-cell markers (CD3, CD4, CD5, CD8), B-cell markers (CD20, CD79a), CD56, CD10, cyclin D1, and epithelial membrane antigen were all negative. The histological features and the immunophenotype indicated a GS. About 25% of the leukaemic cells were immunoreactive for CD68, suggesting partial monocytic differentiation. Cytological examination of the peritoneal fluid revealed the presence of similar atypical cells, with positive MPO immunostaining. There was no evidence of blood or bone marrow involvement to indicate acute leukaemia, because the trephine biopsy and the peripheral blood smear showed no blast cells. All findings were consistent with the diagnosis of non-leukaemic GS of the ileum. Two postoperative courses of daunorubicin and cytarabine were given. There was no evidence of recurrent disease or AML 1 year postoperatively.

Discussion

Granulocytic sarcoma has a long-recognised association with AML.^{1,2} Granulocytic sarcoma is also known as a chloroma because of its greenish hue on gross cut section, due to the presence of MPO within cells. The most common sites of involvement are bone, periosteum, soft tissue, lymph nodes, and skin; but GS can involve any site in the body. The diagnosis of GS depends on the histological features (presence of eosinophilic myelocytes) and immunohistochemical staining.

Isolated GS in the gastro-intestinal tract is extremely rare. Patients may present with epigastric pain, chronic anaemia, and gastrointestinal bleeding.³ Perforation and small bowel obstruction have been reported.^{1,4,5} Sporadic cases of gastrointestinal GS have been reported in the literature.⁶⁻⁹ A larger series of gastrointestinal GS in non-leukaemic patients was reported by Corpechot et al¹ in 1998. In Corpechot's series, the overall prognosis was poor, with four of seven patients developing AML within a median time of 8 months (range, 4-21 months). A large-scale retrospective study by Imrie et al² reported that the median time for patients with isolated GS to develop AML was about 9 months and the median survival was about 22 months. Neither local radiotherapy nor surgery appeared to influence survival.² Patients treated with standard AML-type induction chemotherapy (chemotherapy containing cytarabine) appeared to have a lesser chance of developing AML and a longer survival period was

shown for this group in this and other case series.^{2,10,11} After reviewing 72 cases in the literature, Yamauchi and Yasuda¹¹ concluded that the non-leukaemic period after the diagnosis of GS was significantly longer (median, 12 months) in patients who were treated with systemic chemotherapy, compared with patients who did not receive chemotherapy (median, 3-6 months). They also suggested that an AML-type chemotherapy regimen might lead to a longer non-leukaemic period than treatment with other combinations of chemotherapy.¹¹

Conclusion

Granulocytic sarcoma is a rare disease. Most patients with GS will progress to AML within several months. The overall prognosis is poor. However, AML-type chemotherapy appears to improve survival. Although surgical treatment for the tumour may not influence survival, surgical intervention is indicated when there are tumour-related complications, such as intestinal obstruction or perforation.

References

1. Corpechot C, Lemann M, Brocheriou I, et al. Granulocytic sarcoma of the jejunum: a rare cause of small bowel obstruction. *Am J Gastroenterol* 1998;93:2586-8.
2. Imrie KR, Kovacs MJ, Selby D, et al. Isolated chloroma: the effect of early antileukemic therapy. *Ann Intern Med* 1995; 123:351-3.
3. Saleh HA, Khatib G. Fatal gastrointestinal bleeding as the primary manifestation of granulocytic sarcoma in a patient with myelodysplastic syndrome. *J Fla Med Assoc* 1997;84:111-4.
4. Rodriguez Guerrero JM, Martin Hidalgo JR, Alonso Alejandro E, et al. Granulocytic sarcoma (chloroma) of small bowel: an unfrequent cause of intestinal obstruction [in Spanish]. *Gastroenterol Hepatol* 2003;26:347-50.
5. Zhou W, Vasquez JC, O'Donnell MR, Paz BI. Clinical manifestations of gastrointestinal granulocytic sarcoma requiring surgical treatment. *Am Surg* 2001;67:764-6.
6. Catalano MF, Levin B, Hart RS, Troncso P, DuBrow RA, Estey EH. Granulocytic sarcoma of the colon. *Gastroenterology* 1991;100:555-9.
7. Dabbagh V, Browne G, Parapia LA, Price JJ, Batman PA. Granulocytic sarcoma of the rectum: a rare complication of myelodysplasia. *J Clin Pathol* 1999;52:865-6.
8. Tigges H, Reith HB, Zettl A, Ott G, Thiede A. Myelosarcoma of the proximal jejunum. A rare primary condition of acute myelogenous leukemia [in German]. *Chirurg* 2002;73: 1127-31.
9. Goor O, Goor Y, Konikoff F, Trejo L, Naparstak E. Common malignancies with uncommon sites of presentation: case 3. Epigastric distress caused by a duodenal polyp: a rare presentation of acute leukemia. *J Clin Oncol* 2003;21: 4458-9.
10. Tsimberidou AM, Kantarjian HM, Estey E, et al. Outcome in patients with nonleukemic granulocytic sarcoma treated with chemotherapy with or without radiotherapy. *Leukemia* 2003;17:1100-3.
11. Yamauchi K, Yasuda M. Comparison in treatments of nonleukemic granulocytic sarcoma: report of two cases and a review of 72 cases in the literature. *Cancer* 2002;94:1739-46.

Notice to Trainees

From time to time, the *Hong Kong Medical Journal* receives sponsorship from the drug industry for trainees to receive free subscription to this Journal. If you are a trainee and would like to benefit from such offers, kindly write to the Editorial Office <hkmj@hkam.org.hk> with your full name and address, the date you started training, and the name of the College under which you are being trained.