

Severe right loin pain in a diabetic patient

Quiz

A 48-year-old diabetic woman presented to the United Christian Hospital with fever of acute onset and right loin pain. Physical examination revealed tenderness with a ballotable right kidney. Clinically, the patient was septic with blood pressure on the low side. Laboratory data revealed leukocytosis with a left shift and an elevated creatinine level. A plain kidney, ureter, and bladder (KUB) radiography was obtained upon request (Fig 1). What acute condition was she suffering from?

Comment

Abnormal streaky gas with a localised collection in the upper half of the right kidney was found, and there was a cuff of gas outlining the lateral border of the right kidney signifying perinephric extension. No opaque renal stone was demonstrated. The diagnosis of this patient was emphysematous pyelonephritis (EPN).

Discussion

Gas in the upper urinary tract can be due to a fistula, iatrogenic causes, or gas-forming infection. The gas may be collected in the pelvicalyceal system, within the parenchyma or perinephric space.

Emphysematous pyelonephritis is a severe, fulminant necrotising infection of the renal parenchyma and perinephric tissue which results in the presence of gas within the renal parenchyma, collecting system, or the perinephric tissue.¹ Although uncommonly encountered, it warrants special attention because of its life-threatening potential with mortality rate ranging from 18.8% to 40%. Females are more commonly affected than males, and EPN occurs almost exclusively in patients with diabetes mellitus. Urinary tract obstruction is not an essential prerequisite, with a reported frequency of 5% and 22% in two large series.^{2,3} Urinary stones were found at a frequency of 27%.² *Escherichia coli* and *Klebsiella pneumoniae* together constitute more than 95% of the causative organisms.^{2,3}

A typical clinical scenario is a female patient with diabetes mellitus presenting with fever and loin pain, not different from other upper urinary tract infection. Because EPN runs a fulminating course, it should be

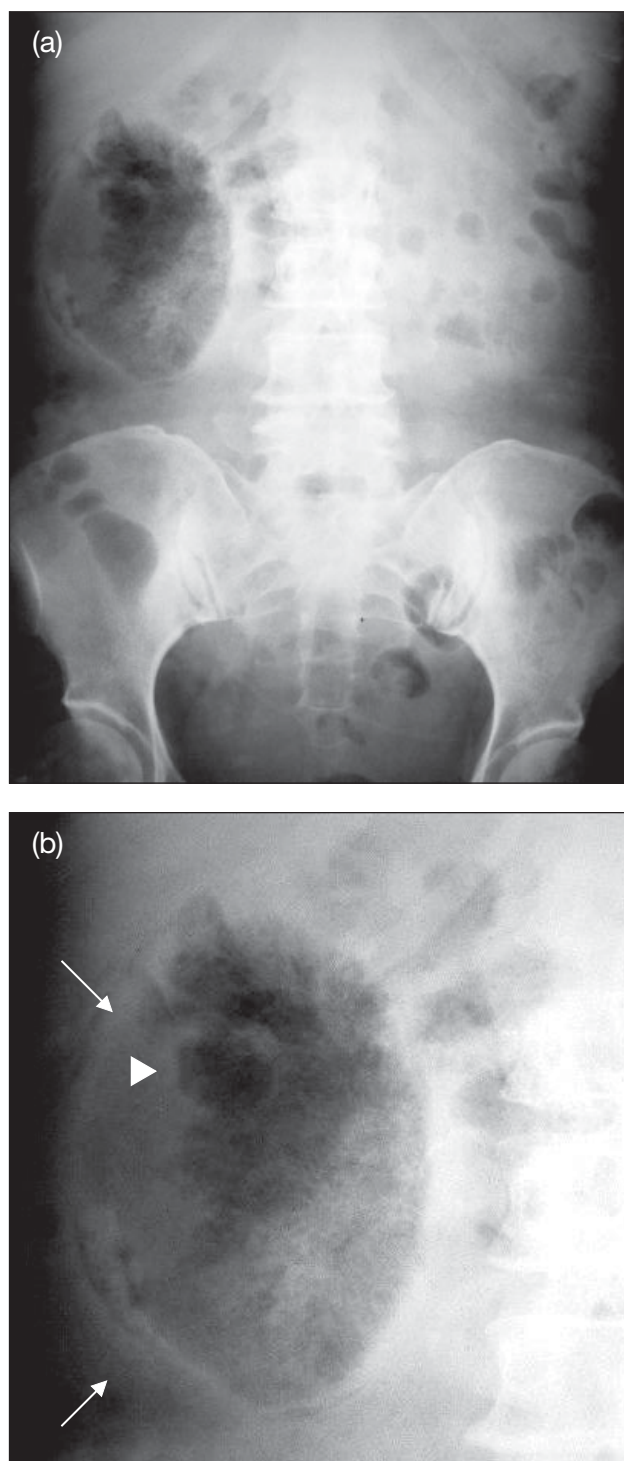


Fig 1. Radiographs of the patient

(a) Abdominal X-ray with right kidney showing abnormal parenchyma and perinephric gas. No opaque renal stone was seen; (b) Magnified view of the right upper quadrant of the abdomen showing a cuff of perinephric gas outlining the lateral border of the right kidney (arrows) and renal parenchymal gas with streaky shadows and a localised collection in the upper half of the right kidney (arrowhead)

suspected if there is continuing clinical downward course, persistence of fever despite appropriate antibiotic treatment, or associated features, such as thrombocytopenia, acute renal impairment, shock, and alteration of the sensorium. The diagnosis of EPN is classically made by demonstrating gas in the kidney or perinephric tissue by plain abdominal X-rays. The intra-parenchymal gas can be streaky, mottling, has a lace-like appearance, or appears as innumerable gas bubbles. Retroperitoneal extension with a cuff of gas surrounding the kidney may be seen in more advanced cases. Computed tomography in the appropriate window setting is more sensitive for detection and evaluation of the extension of gas. It has been used to classify the location of gas to correlate with the clinical outcome and the approach of management of patients.^{2,3} In our patient, there was retroperitoneal gas extension into the anterior pararenal space with the aorta outlined by gas (Fig 2).

Emphysematous pyelonephritis is a life-threatening condition which requires prompt resuscitation. Meticulous control of diabetes, fluid and electrolytes balance, and systemic treatment with antibiotics should be instituted without delay. Nephrectomy was traditionally the treatment of choice in most patients with EPN.²⁻⁴ With the advent of imaging technology, resuscitative and medical management, minimal invasive treatment with percutaneous drainage of obstruction and systemic antibiotics treatment has been tried with success in patients with limited disease (gas confined in the collecting system and renal parenchyma without perinephric extension) and less than two risk factors (thrombocytopenia, acute renal function impairment, disturbance of consciousness, and shock). However, nephrectomy should be promptly attempted for extensive EPN (gas extended beyond the collecting system and renal parenchyma into the perinephric space) with a fulminant course (more than two risk factors) or reserved for patients who do not respond to minimal invasive treatment.³

An emergency total nephrectomy was performed in our patient. At operation, more than half of the kidney was found to be necrotic, and the kidney came out in shreds with large amount of gas bubbles. Subsequent pathology revealed extensive coagulative necrosis and suppurative inflammation in both cortex and papillae with abscess formation. The remaining kidney displayed changes of diabetic glomerulosclerosis.

Conclusion

Emphysematous pyelonephritis can have a non-

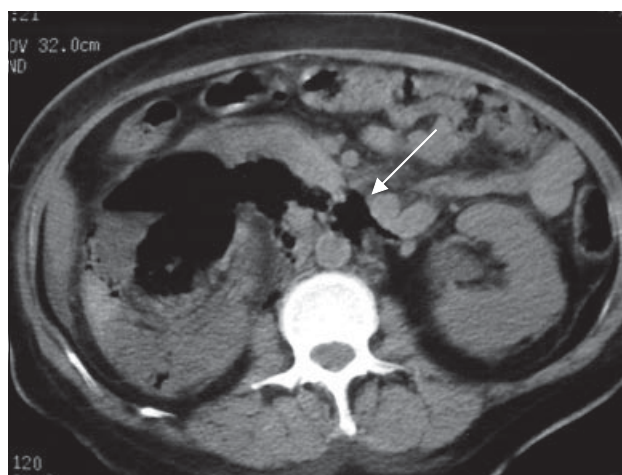


Fig 2. Non-contrast computed tomography of the abdomen at the level of the renal hilum showing gas in the right kidney and retroperitoneum outlining the aorta (arrow)

The renal function of our patient was deranged, computed tomography without the administration of intravenous iodinated contrast medium would suffice to confirm the presence of renal parenchymal gas and to detect the presence of perinephric extension

specific clinical presentation, not different from other upper urinary tract infections, especially in the early clinical course. Plain abdominal X-ray is commonly performed in patients presented with fever and loin pain, often referred to as a "routine KUB". This plain X-ray indeed provides a lot of information, and recognition of intra-parenchymal renal gas is the key to the diagnosis of EPN. A timely diagnosis could be life-saving for this fulminant upper urinary tract infection.

A Li, MB, ChB, FRCR

(e-mail: liallen@yahoo.com)

CC Chan, FRCR, FHKAM (Radiology)

JCS Chan, FRCR, FHKAM (Radiology)

Department of Radiology and Organ Imaging, United Christian Hospital, Kwun Tong, Hong Kong

BWM Que, MB, BS, FHKAM (Surgery)

Lithotripter Centre, St Paul's Hospital, Causeway Bay, Hong Kong

References

1. Lee SE, Yoon DK, Kim YK. Emphysematous pyelonephritis. *J Urol* 1977;118:916-8.
2. Wan YL, Lo SK, Bullard MJ, Chang PL, Lee TY. Predictors of outcome in emphysematous pyelonephritis. *J Urol* 1998; 159:369-73.
3. Huang JJ, Tseng CC. Emphysematous pyelonephritis: clinicoradiological classification, management, prognosis, and pathogenesis. *Arch Intern Med* 2000;160:797-805.
4. Pontin AR, Barnes RD, Joffe J, Kahn D. Emphysematous pyelonephritis in diabetic patients. *Br J Urol* 1995;75:71-4.