

WW Lai 賴維均  
DSC Lam 林順潮

# Chloroquine-induced bull's eye maculopathy

## 氯喹引起的靶心狀黃斑部病變

.....  
We report the case of a 51-year-old woman who presented with bilateral progressive deterioration in vision after taking chloroquine for severe rheumatoid arthritis for 10 years. She was found to have a bull's eye pattern of depigmentation in the macula of both eyes. Despite cessation of chloroquine, her vision did not improve. The clinical presentation of chloroquine retinopathy is discussed, along with the importance of scheduled eye examination for individuals taking chloroquine or hydroxychloroquine.

本報告記錄一位 51 歲女性病人，在服用氯喹治療嚴重風濕性關節炎 10 年後，雙眼的視力日漸變壞，並且在黃斑區出現靶心狀的脫色情況。雖然病人者停服氯喹，但是視力並未有改善。本文亦討論氯喹引起的視網膜病變的臨床症狀，指出服用氯喹或羥氯喹的病人應當定期接受眼科檢查。

### Introduction

Chloroquine is prescribed as an antimalarial, as well as a treatment for inflammatory conditions including rheumatoid arthritis and systemic lupus erythematosus. It has been recognised that prolonged use of chloroquine may result in degeneration of the retinal pigment epithelium and the neurosensory retina, causing a 'bull's eye' pattern of depigmentation of the macula, and subsequent central visual loss.<sup>1,2</sup> We report a case of bull's eye maculopathy developed as a result of chronic use of chloroquine.

### Case report

A 51-year-old woman from Mainland China presented with a history of progressive deterioration in vision in both eyes for 6 months. Her medical history included severe rheumatoid arthritis, for which she had received chloroquine therapy for approximately 10 years. There was no record of the cumulative dosage given. On examination, her visual acuity was 20/100 in both eyes. Slit lamp examination was within normal limits in both eyes. Dilated fundus examination revealed a ring of depigmentation of the retinal pigment epithelium in the macula (Fig). The remainder of the fundus examination was normal. Fluorescein angiography (Fig) was then performed, which showed a bull's eye pattern of granular hyperfluorescence, corresponding to window defects in both eyes. A diagnosis of chloroquine-induced bull's eye maculopathy was made. Following discussion with the patient's physician, chloroquine treatment was discontinued. Azathioprine was substituted as a treatment for her rheumatoid arthritis and she responded well. On follow-up examination 3 months later, the woman's vision remained unchanged.

#### Key words:

Arthritis, rheumatoid;  
Chloroquine;  
Macula lutea;  
Retinal diseases

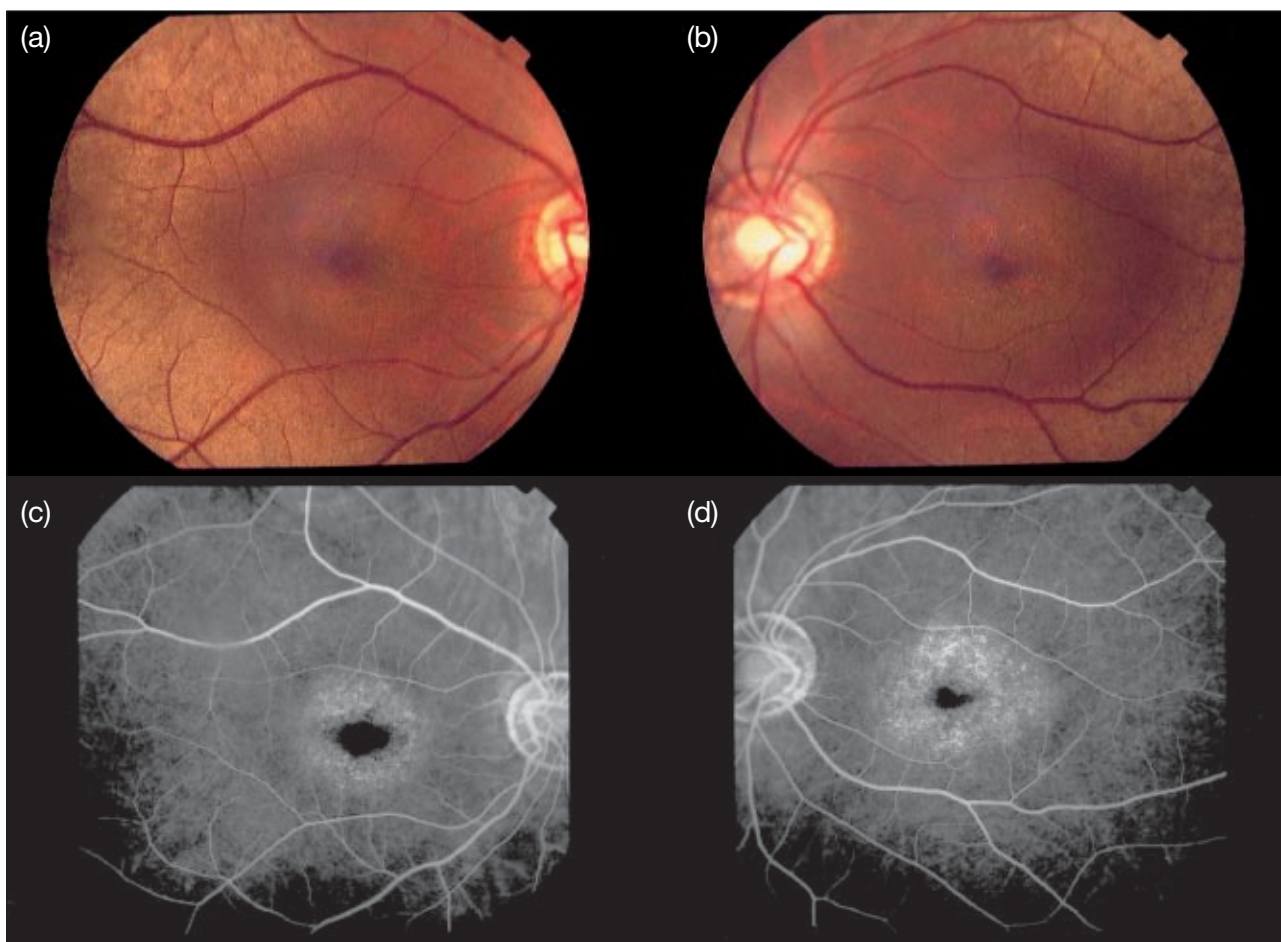
#### 關鍵詞：

關節炎，風濕性；  
氯喹；  
黃斑；  
視網膜病症

*Hong Kong Med J* 2005;11:55-7

Department of Ophthalmology and Visual Sciences, The Chinese University of Hong Kong, Prince of Wales Hospital, Shatin, Hong Kong  
WW Lai, MD  
DSC Lam, FRCS (Edin), FHKAM (Ophthalmology)

Correspondence to: Dr WW Lai  
(e-mail: wicolai@cuhk.edu.hk)



**Fig.** The bull's eye pattern of depigmentation associated with chloroquine maculopathy is evident on fundus photographs and highlighted by fluorescein angiography: photographs of the (a) right eye and (b) left eye; and angiograms of the (c) right eye and (d) left eye

## Discussion

Chloroquine, and to a lesser extent its analogue, hydroxychloroquine, have been used for the treatment of malaria for many years. More recently, they have also been used in the treatment of systemic lupus erythematosus, rheumatoid arthritis, and other inflammatory and dermatologic conditions. Prolonged use of these agents may result in toxicity to the retina. The earliest sign of toxicity is paracentral visual field loss.<sup>1-4</sup> This may occur in advance of any ophthalmoscopic findings. However, many patients may be asymptomatic in the early stages.<sup>1-3</sup> As the condition worsens, alterations in the macula occur, characterised by atrophy of the retinal pigment epithelium in the form of a bull's eye.<sup>1-3</sup> A small, central island of the fovea may be spared initially. The ring of depigmentation may progressively enlarge and affect the foveola, at which time central vision may be affected. The bull's eye pattern of depigmentation may be best appreciated on fluorescein angiography.

The exact mechanism of chloroquine toxicity is not fully understood. Reversal of visual field loss has been documented. However, most cases in which paracentral scotomas have developed or in which bull's eye maculopathy has become evident have not shown any significant recovery of vision.<sup>5</sup>

Most individuals who develop evidence of toxicity have received a cumulative chloroquine dose of 300 g, or a daily dose greater than 3 mg/kg,<sup>3,4</sup> or a daily dose of hydroxychloroquine greater than 6.5 mg/kg.<sup>6</sup> It must be highlighted that although irreversible damage to the retina may occur with these medications, the incidence is very low. During the early stages of use of these medications, toxicity is rare. Most patients who develop loss of vision have used the medication for more than 5 years. The incidence of toxicity increases with higher doses and longer duration of use.<sup>7-10</sup>

Individuals who are taking chloroquine or hydroxychloroquine should undergo periodic and comprehensive eye examinations. The aim of the

**Table. Frequency of comprehensive eye examination recommended by the American Academy of Ophthalmology according to age<sup>10</sup>**

Age (years)	Examination frequency
20-29	At least once during treatment
30-39	At least twice during treatment
40-64	Every 2-4 years
≥65	Every 1-2 years

examination is to allow early identification and minimisation of toxicity. It must be emphasised that there is no established criteria for diagnosing toxicity before a stage where permanent visual loss develops.<sup>9</sup> The examination should include testing of best-corrected visual acuity, as well as slit lamp and dilated fundus examinations. Baseline central visual field testing using the Amsler grid (Keeler, Windsor, United Kingdom) or the automated Humphrey visual field analyser (Humphrey, Dublin, United States) should also be performed. Optional testing, such as assessment of colour vision, fundus photography, fluorescein angiography, and multifocal electroretinography may be considered depending on the presentation.

The frequency of eye examinations is based on the relative risk of developing retinopathy. If a baseline ophthalmologic examination is normal in someone who has just started treatment with chloroquine or hydroxychloroquine, screening during the next 5 years can be done at the same frequency as that recommended by the American Academy of Ophthalmology for regular eye examinations (Table<sup>10</sup>).

Individuals at high risk of developing retinopathy include: those taking more than 3 mg/kg/d of chloroquine, or more than 6.5 mg/kg/d of hydroxychloroquine; those who have used the medication for more than 5 years; individuals with obese body habitus; those with liver or renal disease (because these drugs are dependent on both hepatic and renal clearance); those with pre-existing retinal disease; and those older than 60 years.<sup>9</sup> These high-risk individuals should undergo annual and comprehensive eye examinations. They should be asked to perform regular Amsler grid testing of their central visual field at home and to return promptly for a complete eye examination should there be any changes noted on the examination.

To date, there is no medical treatment for chloroquine and hydroxychloroquine toxicity other than cessation of the medication. Prior to discontinuing the drug, consideration must be given to the management of the underlying systemic condition. Discussion with the rheumatologist or other physician managing treatment is important, because the cessation of the drug may lead to worsening of the systemic disease. Individuals with possible signs of toxicity may be followed closely (eg every 3 months). Those with definite toxicity may have to discontinue the medication immediately. It must be noted that vision loss may continue for several months after discontinuing the drug. Early detection is important because theoretically, some degree of visual recovery is possible at the very early stage of functional loss after cessation of the medication.

## References

- Bernstein H, Zvaifler N, Rubin M, Mansour AM. The ocular deposition of chloroquine. *Invest Ophthalmol* 1963; 2:384-92.
- Henkind P, Rothfield NF. Ocular abnormalities in patients treated with synthetic antimalarial drugs. *N Engl J Med* 1963;269:433-9.
- Elman A, Gullberg R, Nilsson E, Rendahl I, Wachtmeister L. Chloroquine retinopathy in patients with rheumatoid arthritis. *Scand J Rheumatol* 1976;5:161-6.
- Cruess AF, Schachat AP, Nicholl J, Augsburg JJ. Chloroquine retinopathy. Is fluorescein angiography necessary? *Ophthalmology* 1985;92:1127-9.
- Easterbrook M. Long-term course of antimalarial maculopathy after cessation of the treatment. *Can J Ophthalmol* 1992; 27:237-9.
- Tobin DR, Krohel G, Rynes RI. Hydroxychloroquine. Seven-year experience. *Arch Ophthalmol* 1982;100:81-3.
- Mavrikakis M, Papazoglou S, Sfikakis PP, Vaiopoulos G, Rougas K. Retinal toxicity in long term hydroxychloroquine treatment. *Ann Rheum Dis* 1996;55:187-9.
- Levy GD, Munz SJ, Paschal J, Cohen HB, Pince KJ, Peterson T. Incidence of hydroxychloroquine retinopathy in 1207 patients in a large multicenter outpatient practice. *Arthritis Rheum* 1997;40:1482-6.
- Marmor MF, Carr RE, Easterbrook M, Farjo AA, Mieler WF; American Academy of Ophthalmology. Recommendations on screening for chloroquine and hydroxychloroquine retinopathy: a report by the American Academy of Ophthalmology. *Ophthalmology* 2002;109:1377-82.
- American Academy of Ophthalmology. Comprehensive adult medical eye evaluation, Preferred Practice Pattern. San Francisco: American Academy of Ophthalmology; 2000.