

TH Kwan 關子凱
MKH Tong 湯嘉恆
YP Siu 蕭睿邦
KT Leung 梁基泰
HK Lee 李海根
CY Yung 容震宇
TC Au 區德璋

Acute renal failure related to intravenous immunoglobulin infusion in an elderly woman

年老女性出現與靜脈注射免疫球蛋白有關的急性腎衰竭

Intravenous immunoglobulin infusion induces acute renal failure via a mechanism of osmotic nephrosis. Most reported cases are related to the use of sucrose-based intravenous immunoglobulin. Maltose-based intravenous immunoglobulin is thought to be a safer alternative and have a lower risk of renal toxicity than sucrose-based preparations. Maltase, but not sucrase, is present in the brush border of proximal convoluted renal tubules, where the maltose is metabolised. We report a case of maltose-based intravenous immunoglobulin-induced acute renal failure in an elderly diabetic woman. In this case, the risk factors included advanced age, hypovolaemia, sepsis, diabetes mellitus, and the high infusion rate of the intravenous immunoglobulin. Maltase is readily inhibited by hyperglycaemia; therefore, poor glycaemic control may predispose patients to develop acute renal failure even with the better-tolerated maltose-based intravenous immunoglobulin.

輸注靜脈注射免疫球蛋白可以造成滲透性腎病，引發腎衰竭。在現有的報告病例中，大部份都是由於使用含有蔗糖的靜脈注射免疫球蛋白所造成的。相比之下，含有麥芽糖的靜脈注射免疫球蛋白相信是較為安全，引起腎臟中毒的機會亦較低。此外，在近曲腎小管的刷狀緣區並沒有蔗糖酶，只有在這裏將麥芽糖分解的麥芽糖酶。本文報告一位年老的糖尿病女患者，因輸注含有麥芽糖的靜脈注射免疫球蛋白，導致急性腎衰竭。致病的因素包括病人年老、血容量減少、敗血症、糖尿病，以及輸注靜脈注射免疫球蛋白的速率過高。由於麥芽糖酶容易迅速為血糖過多所抑制，因此，即使使用耐受性較強的含麥芽糖成份的靜脈注射免疫球蛋白，在血糖控制不良的情況下，仍會容易引致病人出現急性腎衰竭。

Key words:

Immunoglobulins, intravenous;
Kidney failure, acute;
Maltose;
Sucrose

關鍵詞：

免疫球蛋白，靜脈注射；
腎衰竭，急性；
麥芽糖；
蔗糖

Hong Kong Med J 2005;11:45-9

Division of Nephrology, Department of
Medicine and Geriatrics, Tuen Mun
Hospital, Tuen Mun, Hong Kong
TH Kwan, FRCP, FHKAM (Medicine)
MKH Tong, MRCP, FHKAM (Medicine)
YP Siu, MRCP, FHKAM (Medicine)
KT Leung, MRCP, FHKAM (Medicine)
HK Lee, MRCP, FHKAM (Medicine)
CY Yung, MRCP, FHKAM (Medicine)
TC Au, FRCP, FHKAM (Medicine)

Correspondence to: Dr TH Kwan
(e-mail: kwanth@ha.org.hk)

Introduction

Intravenous immunoglobulin (IVIG) is a highly purified immunoglobulin G preparation made from pooled human plasma which can be stabilised with glucose, maltose, glycine, sucrose, sorbitol, or albumin. The IVIG is used as a prophylaxis or as therapy for various medical disorders. Intravenous immunoglobulin-induced acute renal injury is an uncommon side-effect,¹ and has been mostly related to the administration of sucrose-based IVIG. In contrast, renal injury associated with the newer generation of maltose-stabilised preparation has seldom been reported.² Sucrose was commonly used as the stabiliser to prevent the aggregation of the immunoglobulin, but the high sucrose load contained in these preparations may result in an osmotic insult to the proximal renal tubules. We report a case of acute renal injury following the use of a maltose-based IVIG in an elderly woman.

Case report

A 70-year-old woman had a history of both diabetes mellitus and hypertension for more than 10 years. Her diabetes mellitus was controlled with metformin (500 mg 3 times a day) and gliclazide (40 mg/d), both of which are oral hypoglycaemic agents. Her hypertension was also treated with a nifedipine retard (20 mg), metoprolol (100 mg), and lisinopril (5 mg twice a day). In the year 2000, she was presented to our hospital with anaemic symptoms including palpitations and malaise. Her haemoglobin level on admission was 56 g/L, the antiglobulin test results were positive, and the autoimmune marker studies revealed a positive antinuclear factor titer of 1:160. The serum C3 and C4 levels were depressed to 0.37 g/L (reference range, 0.75-1.61 g/L) and 0.11 g/L (reference range, 0.14-0.44 g/L), respectively, and the anti-dsDNA antibody test results were negative. She was diagnosed as having autoimmune haemolytic anaemia, and a high-dose oral prednisolone treatment (60 mg/d) was started. The prescribed amount of steroid was gradually reduced to a maintenance dosage of 5 mg a day. Her haemoglobin level steadily improved and by April 2004, it had been stabilised to 96 g/L. Her serum creatinine (81 µmol/L) and serum albumin (41 g/L) levels also recovered.

In May 2004, she was readmitted with a high fever (temperature, 39°C), altered conscious state, oliguria, and dehydration. She had orthostatic hypotension with a rapid pulse rate of 130 beats per minute; the rest of her examination was otherwise unremarkable. The blood investigations showed the following serum levels: sodium, 151 mmol/L; urea, 12.8 mmol/L; creatinine, 193 µmol/L; and glucose, 42 mmol/L. She was also found to have metabolic acidosis with a serum pH of 7.28, a bicarbonate level of 11 mmol/L, and an arterial partial pressure of carbon dioxide of 2.9 kPa (21.8 mm Hg). She had a white cell count of 13.3×10^9 /L, a platelet count of 262×10^9 /L, and a reticulocyte count of 5.4%. Her haemoglobin level was low at 43 g/L, but the peripheral blood smear examination did not reveal any notable schistocytes. The serum bilirubin concentration was elevated to 63 µmol/L, the lactate dehydrogenase level was raised at 799 U/L, but her liver function was normal. The haptoglobin level was depressed at 0.27 g/L and antiglobulin test results were positive. The overall blood picture indicated the presence of ongoing active autoimmune haemolysis.

She was resuscitated with intravenous fluid and intravenous broad-spectrum antibiotics, started on insu-

lin infusion, and supported by mechanical ventilation. Her antihypertensive medications and hypoglycaemic agents were also stopped. Sepsis investigative results of cultures of the urine, blood, and cerebrospinal fluids were all negative. Diagnostic imaging including chest radiography, computed tomography of the brain, ultrasonography of the kidneys, and cardiac echocardiography also did not show any abnormalities. On the next day with supportive care and aggressive fluid resuscitation, the haemodynamic state of the patient improved and her blood pressure stabilised at approximately 140/70 mm Hg (mean arterial blood pressure, 80-110 mm Hg), the pulse rate settled down to 80 beats per minute, and the central venous pressure was 10 cm H₂O. Her urine output increased and the serum creatinine concentration decreased to 168 µmol/L.

A course of IVIG at a dosage of 1 g/kg/d for 2 days was then prescribed to treat the autoimmune haemolytic anaemia. Fifty-four grams of IVIG (Intragam P; CSL Limited, Parkville, Victoria, Australia) in a volume of 930 mL was given undiluted intravenously over a 3-hour period. At the start of the IVIG infusion, the blood glucose level was 14.1 mmol/L. Almost immediately following the infusion of the IVIG, she developed acute renal failure with a severe decrease in the urine output to less than 10 mL/h (Fig) and an elevated serum creatinine level up to 222 µmol/L. Renal ultrasonography showed no evidence of urinary blockage, and the urine culture result was negative. Urine microscopy did not reveal vacuolated renal tubular cells. Glycaemic control remained suboptimal following the IVIG infusion, and the blood glucose levels were between 16 and 21 mmol/L. The second dose of IVIG was withheld and continuous venovenous haemofiltration was commenced. After continuous venovenous haemofiltration for 7 days together with supportive treatment, the haemoglobin level began to rise steadily and the urine output also increased. Her renal function fully recovered 2 weeks following the initial administration of the IVIG and the serum creatinine level was 75 µmol/L. A renal biopsy was not performed in view of the prompt recovery of renal function.

Discussion

Intravenous immunoglobulin has been successfully used to treat a wide spectrum of immunological diseases including various autoimmune disorders, primary and secondary immune deficiency states, recent bone marrow transplantation, and chronic lymphocytic leukaemia. Moreover, the use of IVIG is considered reasonably safe, although adverse reactions are not uncommonly encountered. The most frequently

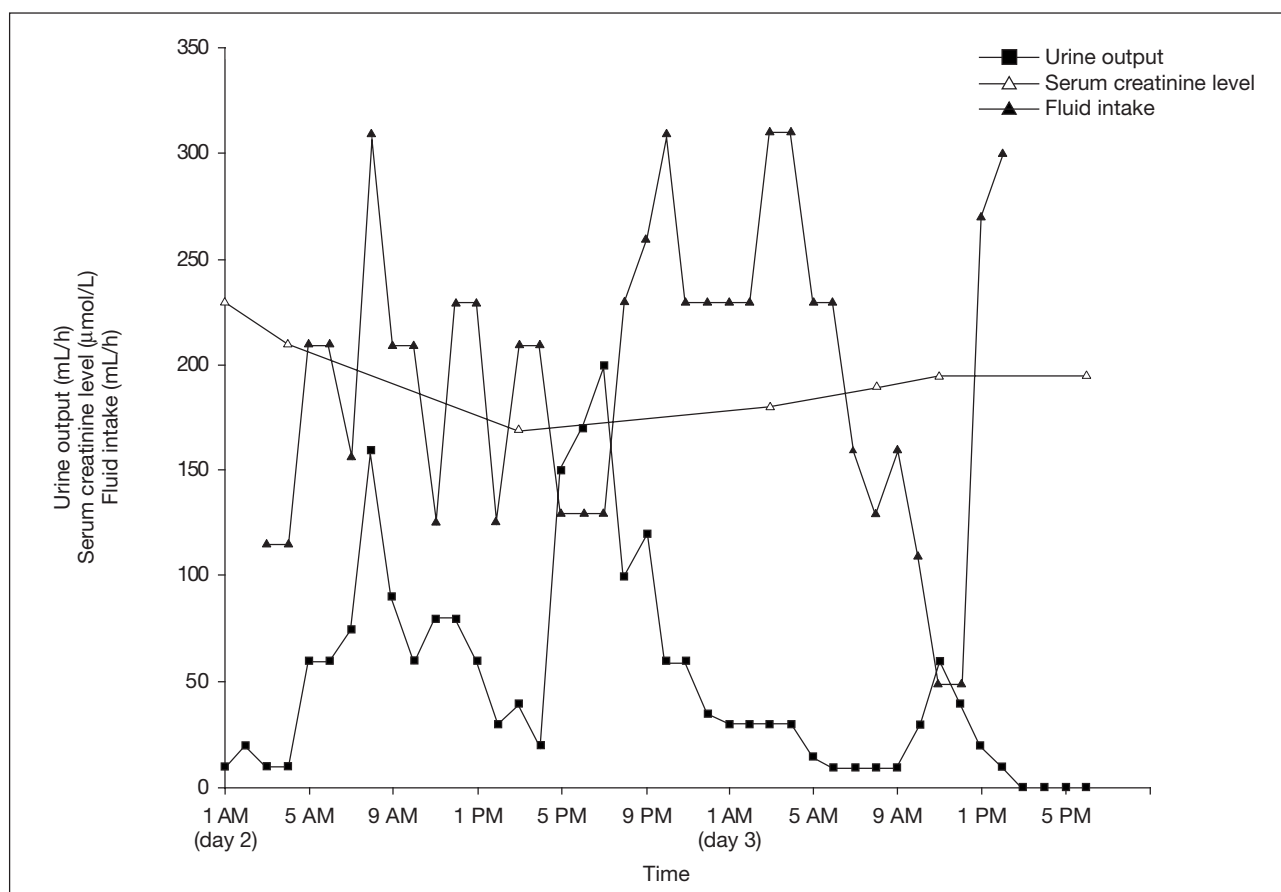


Fig. Temporal relationship between intravenous immunoglobulin infusion, urine output, and serum creatinine level

- 5 AM, 1 PM, and 5 PM on day 2
Additional boluses of fresh plasma, saline, and gelofusine (up to 2.5 L) were given
- 7 PM to 9 PM on day 2
Intravenous immunoglobulin (IVIG) 930 mL was administered for over 3 hours
- 1 PM on day 3
Continuous venovenous haemofiltration (CVVH) was commenced
- 4 PM on day 2, 6 AM on day 3
Furosemide 20 mg and 60 mg was given, respectively
- When urine output dropped after IVIG infusion till noon on day 3, mean arterial pressure remained stable between 79 and 112 mm Hg. Hypotension supervened only after 1 PM on day 3 just before CVVH began

reported side-effects include infusion reactions, hypersensitivity, and anaphylactic responses. Less common but more severe reactions include haematological complications (for example, haemolysis and neutropenia), thromboembolic events secondary to an increased serum viscosity, neurological complication presenting as aseptic meningitis, and IVIG-induced acute renal failure. Renal adverse effect may vary from mild renal impairment to overt acute renal failure that requires dialysis support. The diagnosis may be confirmed by a renal biopsy, which characteristically reveals swollen and vacuolated proximal convoluted tubular cells with obliteration of the tubular lumen.³ Under electron microscopy, lamellar cytoplasmic inclusion bodies may also be seen inside the renal tubular cells.⁴

Intravenous immunoglobulin-induced renal impairment was first described by Perazella and Cayco⁵ in 1998. Since then a number of similar cases have been reported in the literature,⁶⁻⁸ and in almost all of these reports, sucrose-containing products were implicated. The IVIG contains a large amount of pooled human immunoglobulin that requires stabilisation by a sugar moiety to prevent it from aggregating.⁹ Sucrose was first introduced as an osmotic diuretic, and had been one of the most commonly used stabilising agents in IVIG preparations. However, the use of sucrose has been demonstrated to cause sucrose nephropathy and acute renal failure, and its clinical use is now limited.

The exact role of sucrose in the pathogenesis of proximal tubular damage remains unclear, but it has

been reported that the brush border enzymes in the proximal convoluted renal tubules express only maltase and not sucrase or lactase. The sucrose can neither be metabolised nor reabsorbed by the tubular brush border.¹⁰ The presence of considerable amounts of unabsorbed sucrose may cause it to be incorporated into some of the tubular lamellar cytoplasmic inclusion bodies where it could cause osmotic cellular vacuolation and swelling. Hypovolaemia causes the flow of glomerular filtrate in the tubular lumen to be sluggish, which may hasten or further aggravate this osmotic damage. In view of the potential nephrotoxicities of sucrose, alternative stabilising agents including maltose, glucose, glycine, or D-sorbitol have been developed.^{11,12}

Newer generations of IVIG preparations use maltose, glucose, or glycine as the stabilising agent instead of sucrose. These alternatives have been shown to have safety profiles comparable to that of sucrose-based preparations.¹³ Glycine-based IVIG was reported to be superior to sucrose-based IVIG because of the lower incidence of acute renal impairment.⁶ In our case, we used the Intragam P, which is a maltose-based IVIG preparation that has been clinically used since September 2000. This product has an excellent safety profile and is well tolerated.¹⁴ The Intragam P contains 6 g of human protein and 10 g of maltose in each 100 mL. Maltase in the brush border of the proximal convoluted renal tubules can rapidly break down maltose into glucose, which is then completely reabsorbed, thus minimising the chance of inducing an osmotic injury. In our case however, the presence of co-existing hyperglycaemia raised the serum glucose level up to 42 mmol/L, and the breakdown of maltose to glucose was greatly decreased,¹⁰ hence increasing the likelihood of maltose nephrotoxicity. Furthermore, the rate of administration of IVIG may be crucial, because the rate of introduction of the maltose to the renal tubules will affect its metabolism and clearance. Thus, the inadvertent rapid infusion of the IVIG over 3 hours (mean rate, 310 mL/h) could have contributed to the development of the acute renal failure.

Reports concerning maltose-based IVIG-induced renal failure are scarce.^{12,15} Although we would consider the use of Intragam P to be safe, the renal function should be monitored carefully during and after IVIG administration, particularly in high-risk patients including those with diabetes mellitus, pre-existing renal disease, hypovolaemia, sepsis, or those taking concomitant nephrotoxic agents, or those of advanced age. To minimise the risk of inducing renal

toxicity, the patient should be hydrated well before the IVIG administration and the rate of infusion should be reduced. Intragam P IVIG preparation should preferably be diluted and the initial infusion rate should be no more than 60 mL/h; the rate could then be gradually stepped up to a maximum of between 180 and 240 mL/h over a period of at least 30 minutes. Management of maltose-induced osmotic nephrosis is mainly conservative, and if necessary, discontinue the IVIG infusion and initiate the renal replacement therapy. Except in severe cases, the prognosis is usually favourable with good renal recovery.

Conclusion

The temporal sequence of the acute renal failure was highly suggestive of an osmotic renal injury resulting from the high maltose content of the IVIG, but a renal biopsy was not performed, which would have confirmed this diagnosis. To minimise the risk of osmotic injury associated with IVIG infusion, particularly in patients with baseline renal impairment, it is important that the IVIG is diluted and infused at a slow rate in accordance with the manufacturer's recommendations. The renal function should also be monitored carefully during and after the IVIG therapy. Rigorous optimisation of the glycaemic control may also help to promote clearance of the filtered maltose at the renal tubules, and hence, minimise the risk of renal injury.

References

1. Knezevic-Maramica I, Kruskall MS. Intravenous immune globulins: an update for clinicians. *Transfusion* 2003;43:1460-80.
2. Ahsan N, Wiegand LA, Abendroth CS, Manning EC. Acute renal failure following immunoglobulin therapy. *Am J Nephrol* 1996;16:532-6.
3. Monserrat AJ, Gotelli C, Garay R. Sequential histochemical features in experimental osmotic nephrosis. *Virchows Arch B Cell Pathol* 1969;3:365-76.
4. Costa V, Giuliani B. Electron microscopic observations on experimental osmotic nephrosis. *Pathologica* 1968;60:3-10.
5. Perazella MA, Cayco AV. Acute renal failure and intravenous immune globulin: sucrose nephropathy in disguise? *Am J Ther* 1998;5:399-403.
6. Hansen-Schmidt S, Silomon J, Keller F. Osmotic nephrosis due to high-dose immunoglobulin therapy containing sucrose (but not with glycine) in a patient with immunoglobulin A nephritis. *Am J Kidney Dis* 1996;28:451-3.
7. Ahsan N, Palmer BF, Wheeler D, Greenlee RG Jr, Toto RD. Intravenous immunoglobulin-induced osmotic nephrosis. *Arch Intern Med* 1994;154:1985-7.
8. Stewart RR, Winney RJ, Cash JD. Renal toxicity of intravenous immunoglobulin. *Vox Sang* 1993;65:244.
9. Haskin JA, Warner DJ, Blank DU. Acute renal failure after large doses of intravenous immune globulin. *Ann Pharmacother* 1999;33:800-3.

10. Silbernagl S. The role of brush border enzymes in tubular reabsorption of disaccharides: a microperfusion study in rat kidney. *Pflügers Arch* 1977;371:141-5.
11. Williams MA, Rhoades CJ, Provan D, Newland AC. In vitro cytotoxic effects of stabilizing sugars within human intravenous immunoglobulin preparations against the human macrophage THP-1 cell-line. *Hematology* 2003;8: 285-94.
12. Renal insufficiency and failure associated with immune globulin intravenous therapy—United States, 1985-1998. *MMWR Morb Mortal Wkly Rep* 1999;48:518-21.
13. Ballou M, Berger M, Bonilla FA, et al. Pharmacokinetics and tolerability of a new intravenous immunoglobulin preparation, IGIV-C, 10% (Gamunex, 10%). *Vox Sang* 2003; 84:202-10.
14. Ameratunga R, Sinclair J, Kolbe J. Increased risk of adverse events when changing intravenous immunoglobulin preparations. *Clin Exp Immunol* 2004;136:111-3.
15. Chun NS, Savani B, Seder RH, Taplin ME. Acute renal failure after intravenous anti-D immune globulin in an adult with immune thrombocytopenic purpura. *Am J Hematol* 2003;74:276-9.