

CM Hui 許振明
L Kwong 鄺玲
SY Lam 林樹仁
KT Loo 盧稼泰

Merosin-deficient congenital muscular dystrophy in two siblings

Merosin缺乏症：一對姊弟同患先天性肌營養不良症病例

Congenital muscular dystrophies are a group of heterogeneous inherited autosomal recessive disorders. The so-called 'pure' or 'occidental' form is further divided into merosin-positive and merosin-negative subgroups. Merosin is also expressed in the nervous system and its deficiency could affect development of the nervous system. The authors report two siblings with merosin-negative congenital muscular dystrophy. The clinical picture, biopsy findings, and abnormalities as detected by the magnetic resonance imaging of the two patients are presented.

先天性肌營養不良症是一種遺傳變異的常染色體隱性遺傳病，其“本型”或稱為“西方型”的病症又細分為 merosin 基因呈陽性、merosin 基因呈陰性兩個子型。Merosin 亦見於神經系統，缺乏的話會影響神經系統的發展。本文描述一個 merosin 基因呈陰性的先天性肌營養不良症病例，患者為兩姊弟，並展示兩人的臨床圖片、活組織檢查結果，以及磁共振成像發現的異常情況。

Introduction

Congenital muscular dystrophy (CMD) is a rare disorder with onset at birth or in early infancy, and is characterised by muscular weakness, hypotonia, and contractures. There are several types of CMD with heterogeneous aetiologies—for example, one form is Fukuyama type CMD with severe structural brain abnormalities, which has been mapped to chromosome 9q31-33.¹ The pure form of CMD can be further subdivided into merosin-positive or merosin-negative CMD. The merosin-negative CMD form is thought to be the most severe and can be associated with white matter abnormalities as seen with brain imaging. In this case report, we describe two siblings who both have merosin-negative CMD with variable clinical course. This is the first local report of this type of condition, and the findings are discussed in context with the relevant literature.

Case reports

Case 1

A 9-year-old girl was born by full-term, normal delivery in China. Her parents were non-consanguineous and there was no family history of neuromuscular diseases. The pregnancy was uneventful but she was noted to be hypotonic at birth. She had developed recurrent episodes of chest infection since the age of 1 month and was presented to us with this infection at 4 months old. Physical examination revealed an alert infant, but she was hypotonic with decreased spontaneous movements. She had complete head lag with facial weakness, weak cry, and ineffective sucking. Her body weight was at the third percentile, and she had a proximal muscle power of grade 2/6, with generalised muscle wasting. The tendon of the archilles was tight and the deep tendon reflexes were diminished. However, the results of both the ocular and the hearing examinations were normal.

The results of the clinical investigations revealed a serum creatine kinase level of 1770 IU/L, which is grossly elevated from normal. Also, the metabolic screening and the cardiac assessment were both normal. Furthermore, the computed tomography (CT) of the brain showed no abnormalities. Magnetic resonance imaging (MRI) spectroscopy showed extensive demyelination changes

Key words:

Laminin;
Muscular dystrophies;
Congenital

關鍵詞：

層粘蛋白；
肌營養不良症；
先天性

Hong Kong Med J 2004;10:423-6

Tuen Mun Hospital, Tsing Chung Koon
Road, Tuen Mun, Hong Kong;
Department of Paediatrics and Adolescent
Medicine

CM Hui, FHKCPaed, FHKAM (Paediatrics)
L Kwong, FHKCPaed, FHKAM (Paediatrics)
SY Lam, FHKCPaed, FHKAM (Paediatrics)
Department of Pathology
KT Loo, FHKCPath, FHKAM (Pathology)

Correspondence to: Dr CM Hui
(e-mail: huicm888@hotmail.com)

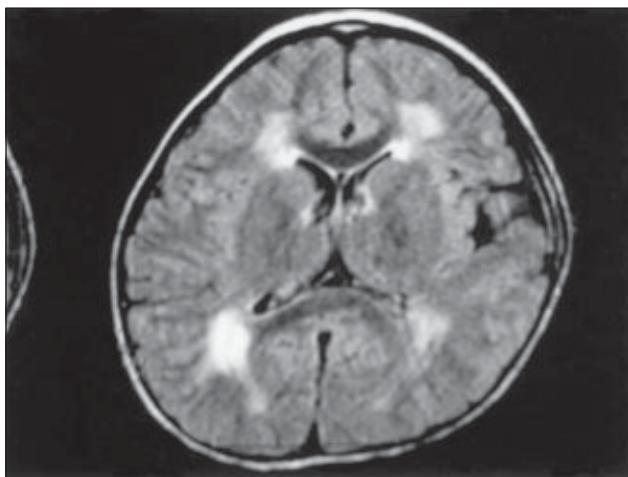


Fig 1a. Magnetic resonance image showing the periventricular deep white matter, which demonstrates abnormal T1W hypointensity and T2W hyperintensity, in a bilateral symmetrical fashion. The subcortical U-fibres are relatively spared, with the changes most prominent in the peritrigonal region

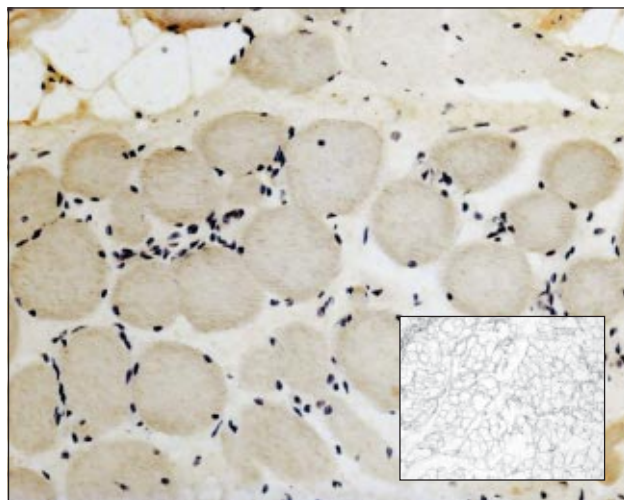


Fig 1b. Muscle biopsy showing negative staining for merosin (immunoperoxidase with haematoxylin counterstain, original magnification, x12.5). Inset: muscle biopsy with positive merosin stain (immunoperoxidase)

in periventricular white matters (Fig 1a); however, an MRI sampled at trigonal area detected no abnormal neurometabolites. An electromyogram showed early recruitment, low amplitude, and brief duration of polyphasic motor unit potential, which are consistent with a myopathic process. Yet, the sensory and motor nerve conduction studies were normal. Muscle biopsy showed prominent fatty replacement of muscle fibres, and the preserved fibres exhibited variation in diameter. There was no relevant inflammatory cell infiltration, and the intermyofibrillary architecture was unremarkable. Immunohistochemical studies on the muscle biopsy showed a completely negative reaction for merosin but was positive to α -sarcoglycan and β -sarcoglycan (Fig 1b). The final diagnosis of the patient was merosin-negative CMD.

The patient developed respiratory failure at the age of 5 months requiring mechanical ventilation, and a tracheostomy was performed at the age of 8 months. The girl was subsequently discharged home at the age of 30 months. She used a ventilator at home and was treated with interdisciplinary neurological and pulmonary rehabilitation. At the age of 9 years, the girl could only sit with support, and multiple contractures and scoliosis were seen. However, no mental impairment was observed and she could communicate in meaningful sentences and play computer games. Furthermore, she was able to attend a special school nearby.

Case 2

The patient was the younger brother of the girl in the first case. Despite genetic counselling and an apparently normal antenatal period, he was noted to be flaccid shortly after birth. At the age of 8 months, his body weight was at the tenth percentile. Proximal muscle power was determined

to be at grade 2/6; there was generalised muscle wasting and the deep tendon reflexes were diminished.

Computed tomography of his brain showed non-specific increased hypodensity in the right parieto-occipital junction white matter. The cardiac assessment was again normal. The electromyogram showed myopathic changes and results of a muscle biopsy at the age of 4 months showed mild variation in the fibre diameter. The majority of fibres were within the normal size range, but a few irregularly distributed foci of interstitial mononuclear inflammatory cell infiltration were present. Occasional regenerating fibres were seen, yet there was no fibrofatty infiltration. Merosin staining was not performed in the muscle biopsy specimen, but because the phenotype and clinical presentation was similar to his elder sister, the final diagnosis was also merosin-negative CMD.

Since the age of 3 years, he had developed recurrent chest infection and required nocturnal bilevel positive airway pressure (BiPAP). Although he was wheelchair-bound, he could speak in sentences and his cognitive function was intact. His respiratory function was static and he did not require a tracheostomy.

Discussion

Myopathies are defined as any disorder of muscle tissue and characterised by lower motor neuron weakness. The condition can be classified according to the presence or absence of specific ultrastructural changes as detected by muscle biopsy.² These dystrophic changes are reported to be an increase in the connective tissue, degenerating and regenerating fibres, and marked variation in the fibre size.^{2,3} Furthermore, muscular dystrophies can be classified

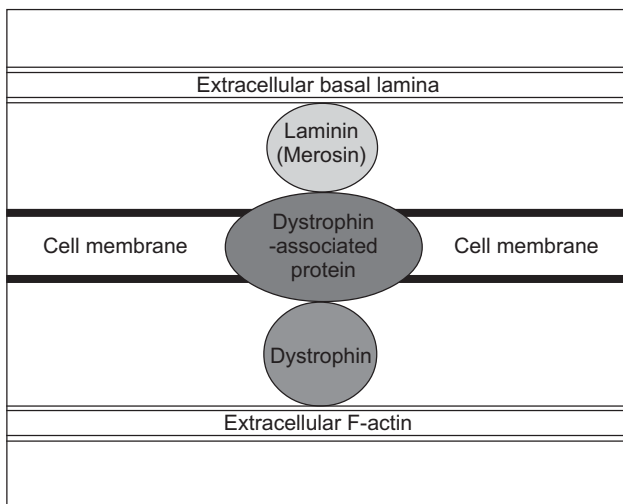


Fig 2. The dystrophin-glycoprotein complex confers the muscle membrane stability. The dystrophin portion is intracellular and is anchored to the intracellular F-actin filament, the dystrophin-associated protein is transmembrane, and the laminin-merosin complex is anchored to the basal lamina in the extracellular matrix

according to the onset of symptoms and the progression of muscle weakness. Congenital muscular dystrophy is an autosomal recessive disease that is present at birth or manifest by the age of 6 months. It is characterised by a static or slow progression of muscle weakness. Other types of muscular dystrophies have later onset and muscular weakness is progressive, such as X-linked dystrophinopathies (Duchenne and Becker muscular dystrophies), and limb girdle muscular dystrophies.

There are two categories of CMD depending on the structural involvement of the central nervous system (CNS).² Fukuyama CMD, Walker-Warburg syndrome, and muscle-eye-brain disease are associated with structural abnormalities of the brain, severe mental retardation, and seizures. The latter two disorders are also associated with ocular malformation. The classic form of CMD has no apparent clinical involvement of the CNS and the patient has normal intellect. Although the brain is structurally normal, a subset of patients has been identified with white matter changes on examination with CT or MRI.

The classic form of CMD can be further subdivided into two groups depending on the presence or absence of merosin. In 1994, Tome et al⁴ reported the first group of patients with classic CMD that were also deficient in merosin. The merosin-negative cases demonstrated clinical homogeneity with symptoms of severe hypotonia, multiple contractures, delayed developmental milestones, and normal mentation accompanied by variable degrees of central hypomyelination as seen with neuroimaging.^{1,3}

Laminins are a family of large glycoprotein which form the back bone of the basement membrane.⁵ Each laminin

molecule consists of three polypeptide chains (alpha, beta, and gamma).⁶ Different laminin isoforms exist as combinations of these polypeptide chains. Merosin is the name for the alpha-2 chain of laminin 2 molecule which is prominently expressed in muscle and other tissues. The merosin gene has been mapped to the laminin alpha-2 locus (LAMA2) at chromosome 6q22.^{1,2} In Duchenne muscular dystrophy, a number of dystrophin-associated proteins (DAP) have been identified,^{7,8} which are subdivided into three groups—sarcoglycans, dystroglycans, and syntrophins. These proteins span the muscle membrane and function as a complex bridge between the cell cytoplasm and the extracellular matrix.^{9,10} The dystrophin-glycoprotein complex is formed from laminin-merosin, DAP, and dystrophin (Fig 2). The dystrophin portion is intracellular and is anchored to the intracellular F-actin filament. The DAP portion of the bridge complex is in transmembrane, and the laminin-merosin complex is anchored to the basal lamina in the extracellular matrix. The muscle membrane is stabilised by this dystrophin-glycoprotein complex; however, a deficiency in any part of this complex bridge disrupts the integrity of the membrane. Tears in the membrane cause excess calcium leakage into the muscle fibre and initiates a cascade of events that eventually lead to muscle fibre necrosis. This scenario is exactly what happens in the final stages of muscular dystrophy.⁹

In a review of published reports involving 248 patients with immunohistochemical abnormalities of merosin,³ 76% of cases fitted the definition of classic CMD, 10% presented after the age of 6 months, and 75% were not able to walk by the age of 2 years. Seizures were reported in 20% of the cases and 11 patients died from respiratory failure at ages ranging from 4 months to 12 years (mean and median, 60 months). A creatine kinase level greater than 1000 U/L was recorded on at least one occasion in 100 of 124 patients that were tested, the creatine kinase level on the remaining 124 patients were not mentioned in the report. But mental retardation was only present in 7% to 12%; this mental retardation had no apparent correlation to the severity of weakness.

Philpot et al¹¹ reviewed 24 cases of pure congenital muscular dystrophy, of which 11 were merosin-negative. They found that the merosin-deficient group was more severely affected clinically than the merosin-positive group. MRI was performed in 15 children, seven of these patients had merosin-negative muscular dystrophy. In these seven, there were white matter changes in the MRI images. Philpot et al¹¹ postulated that the white matter changes were specific to merosin-negative CMD type. Merosin is expressed in foetal brain and this may account for the dysmyelination as seen in the MRI studies.

Although merosin-negative CMD cases demonstrate clinical homogeneity, the severity of weakness and CNS manifestation may vary. Patients with merosin-negative CMD are also likely to develop dilated cardiomyopathy.¹²

Patients also have difficulties in all stages of feeding that progress with age.¹³ The patients in this case report were diagnosed as having the same phenotype, but the respiratory function was more crippling in the elder sister compared with the brother. She required a tracheostomy and home ventilation during young childhood, whereas the brother was stable on BiPAP.

An accurate diagnosis is important for the treatment of patients with congenital muscular dystrophy because the clinical course can then be more precisely predicted. The common complications can be anticipated using such methods as regular echocardiography, and a comprehensive extensive battery of tests is often required. Genetic counselling needs to be more informative because this form of CMD is an autosomal recessive disorder and can be detected at an early stage. Prenatal diagnosis is now possible through chorionic villous biopsy or amniocentesis because merosin is also expressed in trophoblasts.^{2,14} Foetal muscle biopsy is also another option for prenatal diagnosis in late pregnancy.² The importance of pulmonary rehabilitation as part of the management programme cannot be overlooked because the mortality of patients with congenital muscular dystrophy is related to respiratory function.

Conclusion

Congenital muscular dystrophy is not a single disease entity. It can be subdivided into two different subtypes depending on the presence or absence of merosin, which is an important structural constituent of a larger structure called dystrophin-glycoprotein complex. Defects of this complex can lead to the disruption of integrity of the muscle cell membrane, which results in muscle damage. Merosin-deficient CMD has a distinctive clinical presentation in addition to the other CMD features—patients have demyelination changes in the brain but of normal intellect. Diagnosing merosin-negative CMD requires

special staining of the muscle biopsy samples, and also genetic investigation. To our knowledge, this is the first reported case of sibling merosin-negative CMD in our locality.

References

1. Mendell JR. Congenital muscular dystrophy: searching for a definition after 98 years. *Neurology* 2001;56:993-4.
2. Jones KJ, North KN. Recent advances in diagnosis of the childhood muscular dystrophies. *J Paediatr Child Health* 1997;33:195-201.
3. Jones KJ, Morgan G, Johnston H, et al. The expanding phenotype of laminin alpha2 chain (merosin) abnormalities: case series and review. *J Med Genet* 2001;38:649-57.
4. Tome FM, Evangelista T, Leclerc A, et al. Congenital muscular dystrophy with merosin deficiency. *C R Acad Sci III* 1994;317:351-7.
5. Wewer UM, Engvall E. Merosin/laminin-2 and muscular dystrophy. *Neuromuscul Disord* 1996;6:409-18.
6. Minetti C, Bado M, Morreale G, Pedemonte M, Cordone G. Disruption of muscle basal lamina in congenital muscular dystrophy with merosin deficiency. *Neurology* 1996;46:1354-8.
7. Jones KJ, Kim SS, North KN. Abnormalities of dystrophin, the sarcoglycans, and laminin alpha2 in the muscular dystrophies. *J Med Genet* 1998;35:379-86.
8. Vajsar J, Chitayat D, Becker LE, Ho M, Ben-Zeev B, Jay V. Severe classical congenital muscular dystrophy and merosin expression. *Clin Genet* 1998;54:193-8.
9. Tsao CY, Mendell JR. The childhood muscular dystrophies: making order out of chaos. *Semin Neurol* 1999;19:9-23.
10. Sunada Y, Edgar TS, Lotz BP, Rust RS, Campbell KP. Merosin-negative congenital muscular dystrophy associated with extensive brain abnormalities. *Neurology* 1995;45:2084-9.
11. Philpot J, Sewry C, Pennock J, Dubowitz V. Clinical phenotype in congenital muscular dystrophy: correlation with expression of merosin in skeletal muscle. *Neuromuscul Disord* 1995;5:301-5.
12. Spyrou N, Philpot J, Foale R, Camici PG, Muntoni F. Evidence of left ventricular dysfunction in children with merosin-deficient congenital muscular dystrophy. *Am Heart J* 1998;136:474-6.
13. Philpot J, Bagnall A, King C, Dubowitz V, Muntoni F. Feeding problems in merosin deficient congenital muscular dystrophy. *Arch Dis Child* 1999;80:542-7.
14. Pegoraro E, Marks H, Garcia CA, et al. Laminin alpha2 muscular dystrophy: genotype/phenotype studies of 22 patients. *Neurology* 1998;51:101-10.