

EMC Chau 周慕慈  
KYY Fan 范瑜恩  
WH Chow 周榮興

# Combined atrial septostomy and oral sildenafil for severe right ventricular failure due to primary pulmonary hypertension

## 以心房間隔造口術和口服sildenafil治療原發性肺動脈高壓引起的嚴重右心室衰竭

Management of primary pulmonary hypertension is usually difficult because the disease is uncommon and the aetiology of the disease is not well understood. The disease is potentially lethal because it can lead to failure of the right ventricle, low cardiac output, and ensuing multiple organ failure. We report the successful treatment of a case of low-output syndrome due to primary pulmonary hypertension using combined drug therapy and atrial septostomy. Latest developments in the treatment of this disease are also discussed.

原發性肺動脈高壓是一種罕見的疾病，醫學界對病因亦不太了解，這使治療相當困難。本症有可能造成死亡，因為它能引起右心室衰竭、低排血量，並導致多種器官機能衰竭。本文所報告的病例，是一位原發性肺動脈高壓引起低排血量綜合徵的病人，她接受藥物治療及心房間隔造口術後得以康復。本文並討論本症療法的最新發展。

### Introduction

Primary pulmonary hypertension is a rare but potentially fatal disease among young people; without treatment, affected individuals have a median life expectancy of 2.8 years after diagnosis. Management is usually difficult because the aetiology of the disease is uncertain. The major prognostic factor is whether the right ventricle can adapt to the increased afterload. As the pulmonary pressure increases, there is right ventricular hypertrophy, followed by dilatation. When the pulmonary resistance exceeds the adaptation capacity, the right ventricle decompensates and the patient may die of low-output syndrome. In this article, we report a case of primary pulmonary hypertension with low-output syndrome due to right ventricular failure and the successful treatment using combined atrial septostomy and oral sildenafil (citrate) therapy.

### Case report

A 40-year-old Chinese woman was referred to the Grantham Hospital in August 2002 for management of severe pulmonary hypertension. Because causes of pulmonary hypertension could not be identified, the patient was treated with warfarin, frusemide, diltiazem, and home oxygen therapy. Cardiac catheterization in 2003 showed elevated right atrial pressure of 22 mm Hg, systemic pulmonary hypertension (pulmonary artery pressure, 119/48 [mean, 77] and aortic blood pressure, 122/77 [mean, 92]), and a low cardiac index (calculated using the Fick Principle) of  $1.27 \text{ L}\cdot\text{min}^{-1}\cdot\text{m}^{-2}$ . Intravenous prostacyclin therapy was tried, but was not tolerated by the patient because of nausea and vomiting. She was assessed for lung transplantation but was deemed unsuitable because of poorly controlled diabetes mellitus and multiple bilateral leg ulcers due to chronic ankle oedema.

#### Key words:

Heart atria;  
Heart septum;  
Hypertension, pulmonary

#### 關鍵詞：

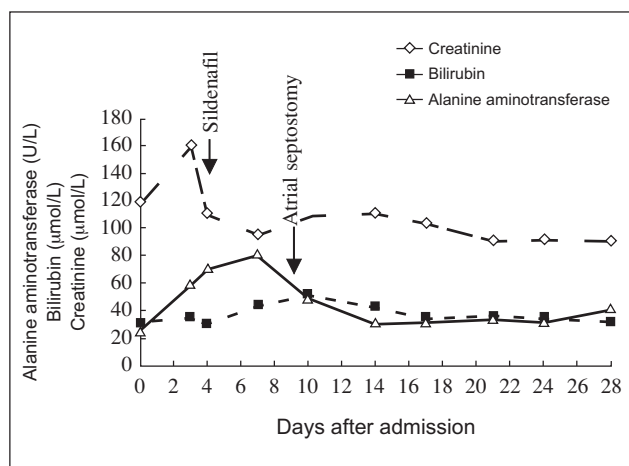
心房；  
心臟間隔；  
高壓，肺動脈

*Hong Kong Med J* 2004;10:281-4

Department of Cardiology, Grantham Hospital, 125 Wong Chuk Hang Road, Hong Kong

EMC Chau, MB, BS, FRCP  
KYY Fan, MB, ChB, FRCP  
WH Chow, MB, BS, FRCP

Correspondence to: Dr EMC Chau  
(e-mail: echau@hkucc.hku.hk)



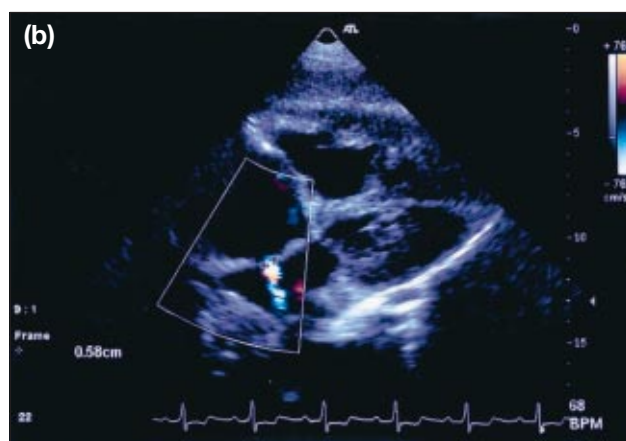
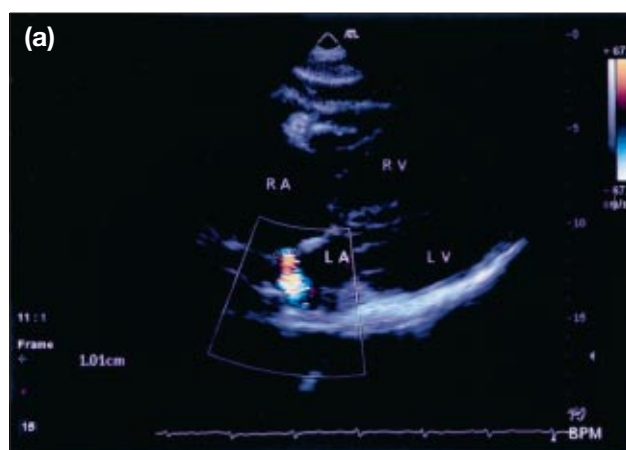**Fig 1. Renal and liver function test results after hospital admission**

The patient's liver function continued to deteriorate after oral sildenafil administration, but rapidly improved after atrial septostomy

The patient's condition continued to deteriorate, requiring hospital admission in June 2003 for symptoms of severe right heart failure. She had a distended abdomen and dyspnoea even at rest. Her arterial oxygen saturation was 91% during oxygen therapy at 5 L/min, and her blood pressure was low, at 102/67. Her blood tests showed impaired liver and renal function. Intravenous inotropic therapy was started. Echocardiography showed that the right side of the heart was grossly dilated and also revealed severe pulmonary regurgitation and tricuspid regurgitation. The pulmonary hypertension was supra-systemic, and the right ventricular pressure was estimated to be 135 mm Hg.

Oral sildenafil therapy was thus implemented, starting at 25 mg twice a day and increasing to 50 mg 3 times a day. Although renal function improved slightly on inotropic therapy, her liver remained congested and its function progressively deteriorated (Fig 1). After 5 days of sildenafil treatment, the patient underwent atrial septostomy. This procedure was performed percutaneously through the right femoral vein and used a Brockenborough needle for trans-septal puncture; graded balloon dilatation at the atrial septum used three balloons (range, 10-14 mm in diameter). Immediately after the procedure, the cardiac index increased from the baseline at the beginning of the procedure of 1.3 L·min<sup>-1</sup>·m<sup>-2</sup> to 1.8 L·min<sup>-1</sup>·m<sup>-2</sup>, and the aortic blood pressure increased from 89/56 (mean, 60) to 100/60 (mean, 73). Furthermore, the left ventricular end-diastolic pressure increased from 12 mm Hg to 16 mm Hg, and the oxygen saturation at 5 L/min oxygen decreased from 94% to 74%. The patient tolerated the procedure without any complaints.

In the immediate postoperative period, the patient remained hypoxic: arterial saturation at 5 L/min oxygen varied between 55% and 78%. However, her liver and



**Fig 2. Subcostal view of transthoracic echocardiogram performed at (a) 1 week and (b) 3 weeks after atrial septostomy**

The scan shows the right-to-left shunt and a reduction in the size of the atrial septal defect, from 10 mm to 6 mm (RA=right atrium, RV=right ventricle, LA=left atrium, LV=left ventricle)

renal function improved, and intravenous inotropic therapy was gradually discontinued 3 days later. Serial echocardiography performed at 1 week and 3 weeks after the atrial septostomy showed a gradual reduction in the size of the atrial septal defect, from 10 mm to 6 mm (Fig 2). Corresponding with the reduction in the right-to-left shunt, the patient's oxygen requirement decreased and oxygen saturation increased from 85% while she was breathing oxygen at 5 L/min to 90% while breathing room air. She was discharged home 4 weeks after the procedure and was given warfarin, frusemide, and sildenafil (50 mg, 3 times daily). After 4 weeks of sildenafil treatment, echocardiography showed that the right ventricular systolic pressure was 95 mm Hg and the degree of tricuspid regurgitation had markedly reduced.

At 8 months after the atrial septostomy, the patient's condition was good, and she managed to complete a 381-m hall walk in 6 minutes. Furthermore, oxygen saturation while she breathed room air was 98%, she no longer had abdominal distension or leg oedema, and her leg ulcers had healed completely. Echocardiography revealed that the

right atrium and ventricle were still very dilated, but the degree of tricuspid regurgitation had decreased and the right ventricular pressure was approximately 60 mm Hg.

## Discussion

### *Pathophysiology*

The aetiology of primary pulmonary hypertension is unknown. However, pathological mechanisms appear to involve remodelling of the pulmonary arteries, vasoconstriction, and in situ thrombosis.<sup>1</sup> There is some evidence that the cells in the plexiform lesions of the pulmonary arteries are polyclonal in cases of secondary pulmonary hypertension, but monoclonal in cases of primary pulmonary hypertension, suggesting a tumour-like proliferation.<sup>2</sup> In pulmonary hypertension, endothelial dysfunction is related to changes in levels of many humoral mediators, such as increased levels of vasoconstrictive substances (eg endothelin, thromboxane A<sub>2</sub>, and angiotensin II), and reduced levels of vasodilating substances (eg prostacyclin, prostaglandins, nitric oxide, atrial natriuretic peptide, and brain natriuretic peptide). Some of the new drugs used to treat pulmonary hypertension target these mediators.

### *Drug treatments*

Conventional treatment for primary pulmonary hypertension includes warfarin, diuretics, digoxin, and oxygen therapy. About 25% of patients with primary pulmonary hypertension respond favourably to oral high-dose calcium channel blockers; these drugs can bring about a significant drop in the mean pulmonary pressure and an improved prognosis.<sup>3</sup>

Other drugs that target humoral mediators have been shown to be effective in the treatment of severe pulmonary hypertension. They include prostacyclin<sup>4</sup> and its analogues (notably, iloprost<sup>5</sup>), endothelin antagonists (eg bosentan<sup>6</sup>), and phosphodiesterase inhibitors (eg sildenafil<sup>7</sup>). Currently, sildenafil is only approved for treatment of erectile dysfunction in Hong Kong.

### *Surgical and interventional treatments*

For a number of years, primary pulmonary hypertension was a major indication for lung transplantation. The limited availability of suitable donors, side-effects of long-term immunosuppression after transplantation, and development of obliterative bronchiolitis were the major limitations.

Patients with pulmonary hypertension due to a right-to-left shunt have a better survival rate than those with primary pulmonary hypertension.<sup>8</sup> This finding prompted several studies to use atrial septostomy to create a right-to-left shunt at the atrial level, via either blade catheterization<sup>9</sup> or balloon dilatation.<sup>10,11</sup> Atrial septostomy is indicated as a palliative procedure for treating advanced primary pulmonary hypertension that is refractory to vasodilator therapy. This approach allows decompression of the right

ventricle, which effectively increases both the preload to the left ventricle and the cardiac output. The drawback of this treatment, however, is the fall in oxygen saturation and practical risks associated with the procedure. In the small studies using balloon dilatation atrial septostomy,<sup>10,11</sup> the procedure-related mortality ranged from 0% to 6.7%. As illustrated in our case, spontaneous closure of the iatrogenic atrial septal defect is possible, and the procedure may sometimes need to be repeated. So far at our institution, we have performed graded balloon dilatation atrial septostomy in three patients with severe primary pulmonary hypertension, and all three patients survived the procedure. Their mean cardiac index increased from 1.18 L·min<sup>-1</sup>·m<sup>-2</sup> to 1.66 L·min<sup>-1</sup>·m<sup>-2</sup> and oxygen saturation fell from 93% to 74% immediately after the procedure.

### *Rationale for combined oral sildenafil and atrial septostomy in our case*

There are some relative contra-indications of atrial septostomy in advanced primary pulmonary hypertension. It is recognised that patients with severe right ventricular failure manifested by a low cardiac index and high right atrial pressure (as in our case) are at greatest risk of death following atrial septostomy, because of refractory hypoxaemia or a sudden increase in left atrial pressure leading to acute pulmonary oedema. Ideally, the arterial oxygen saturation of a patient at rest breathing room air should be greater than 90%, to allow for the expected drop in saturation following a right-to-left shunt. It has been recommended that during the procedure, the oxygen saturation should not be allowed to fall below 75%, and that the left ventricular end-diastolic pressure should not exceed 18 mm Hg.<sup>10</sup>

In view of the poor condition of the patient in our case, we decided that a pulmonary-selective vasodilator should be given to optimise her condition before attempting the atrial septostomy. Unfortunately, this patient could not tolerate intravenously administered prostacyclin. Oral sildenafil was chosen because it was readily available (albeit for a totally different illness—erectile dysfunction) and affordable when compared with other new pulmonary vasodilators. The drug was well tolerated, although the patient's liver function continued to deteriorate. The atrial septostomy produced an immediate improvement in haemodynamic indicators, such as cardiac output and arterial blood pressure, and resulted in increased perfusion of the major organs. There was also immediate decompression of the right ventricle, as evidenced by the rapid improvement in her liver function and resolution of symptoms of right ventricular failure, such as abdominal distension and ankle oedema. The drastic drop in the oxygen saturation indicated that the final size of the balloon used in the atrial septostomy was probably oversized. Fortunately, the tendency for spontaneous closure in balloon dilatation of the atrial septum actually worked to our advantage in gradually reducing the right-to-left shunt while the oral sildenafil took its effect. The fact that at 8 months after the procedure,

the patient was no longer in right ventricular failure was encouraging, and demonstrated that oral sildenafil was effective in lowering the pulmonary arterial pressure.

### Conclusion

Treatment of primary pulmonary hypertension is difficult and proves challenging even in specialised centres. However, combination therapy involving the new pharmacological agents with or without atrial septostomy may be life-saving in patients presenting with severe right ventricular failure due to the disease. Atrial septostomy is useful in producing an immediate decompression of the failing right ventricle and improving cardiac output and perfusion of the major organs, while sildenafil alleviates the pulmonary hypertension in the long term. Whether early introduction of these combination treatments may obviate the need for lung transplantation remains to be seen.

### References

1. Olschewski H, Seeger W. In: Pulmonary hypertension—pathophysiology, diagnosis, treatment, and development of a pulmonary-selective therapy. Bremen, Germany: Uni-Med Verlag AG; 2002.
2. Lee SD, Shroyer KR, Markham NE, Cool CD, Voelkel NF, Tudor RM. Monoclonal endothelial cell proliferation is present in primary but not secondary pulmonary hypertension. *J Clin Invest* 1998;101:927-34.
3. Rich S, Kaufmann E, Levy PS. The effect of high doses of calcium-channel blockers on survival in primary pulmonary hypertension. *N Engl J Med* 1992;327:76-81.
4. Barst RJ, Rubin LJ, Long WA, et al. A comparison of continuous intravenous epoprostenol (prostacyclin) with conventional therapy for primary pulmonary hypertension. The Primary Pulmonary Hypertension Study Group. *N Engl J Med* 1996;334:296-302.
5. Olschewski H, Ghofrani HA, Schmehl T, et al. Inhaled iloprost to treat severe pulmonary hypertension. An uncontrolled trial. German PPH Study Group. *Ann Intern Med* 2000;132:435-43.
6. Channick RN, Simonneau G, Sitbon O, et al. Effects of the dual endothelin-receptor antagonist bosentan in patients with pulmonary hypertension: a randomised placebo-controlled study. *Lancet* 2001;358:1119-23.
7. Mikhail GW, Prasad SK, Li W, et al. Clinical and haemodynamic effects of sildenafil in pulmonary hypertension: acute and mid-term effects. *Eur Heart J* 2004;25:431-6.
8. Hopkins WE, Ochoa LL, Richardson GW, Trulock EP. Comparison of the hemodynamics and survival of adults with severe primary pulmonary hypertension or Eisenmenger syndrome. *J Heart Lung Transplant* 1996;15:100-5.
9. Rich S, Dodin E, McLaughlin VV. Usefulness of atrial septostomy as a treatment for primary pulmonary hypertension and guidelines for its application. *Am J Cardiol* 1997;80:369-71.
10. Sandoval J, Gaspar J, Pulido T, et al. Graded balloon dilation atrial septostomy in severe primary pulmonary hypertension. A therapeutic alternative for patients nonresponsive to vasodilator treatment. *J Am Coll Cardiol* 1998;32:297-304.
11. Thanopoulos BD, Georgakopoulos D, Tsaousis GS, Simeunovic S. Percutaneous balloon dilatation of the atrial septum: immediate and midterm results. *Heart* 1996;76:502-6.