

LJ Zhou 周林江
 PL Khong 孔碧蘭
 KY Wong 黃嘉賢
 GC Ooi

A case of cerebellar hypoplasia in a Chinese infant with osteogenesis imperfecta

一個成骨不全的華裔幼兒小腦發育不全的病例

We report a unique case of unilateral cerebellar hypoplasia in a young Chinese girl with osteogenesis imperfecta type IV. Magnetic resonance imaging showed mild basilar invagination and impression. Although unilateral cerebellar hypoplasia and osteogenesis imperfecta may have been coincidental diagnoses, we propose possible mechanisms for unilateral cerebellar hypoplasia secondary to osteogenesis imperfecta. For example, cerebellar hypoplasia may have been because of vascular disruption or direct compression to the posterior circulation in utero. Foetuses with osteogenesis imperfecta are more susceptible to the above risks compared to the normal foetus because of associated craniocervical anomalies and a poorly ossified skull.

本報告描述一個單側小腦發育不全的獨特病例，患者是一名華裔女孩，她兼有第四型成骨不全。磁共振成像顯示女孩有輕微顛底凹入。雖然小腦發育不全和成骨不全同時出現可能只是診斷上的巧合，但是我們在本文指出成骨不全可能誘發小腦發育不全，並提出了一些可能的成因，其中一個原因就是血管受到破壞，或子宮後部血液循環直接受壓，引致小腦發育不全。與健全的胎兒比較，成骨不全的胎兒由於顛頸交界處出現結構畸形，以及顛骨的骨化不良，所以特別容易受到前述的問題影響。

Introduction

Osteogenesis imperfecta (OI) is a hereditary systemic bone disease that results from abnormal production of type-I collagen.¹ The disease is characterised by fragile bones, blue scleras, dentogenesis imperfecta, and early loss of hearing. According to Sillence,¹ there are four types of OI, each further subdivided on the basis of salient characteristics. Type I is the mildest form, and patients tend to live near-normal lives. In contrast, type II is invariably fatal before birth or in the perinatal period. Type III is less severe than type II but more severe than type IV, such that the order of decreasing severity of OI is type II, type III, type IV, and type I.

Osteogenesis imperfecta is associated with spinal deformities, including craniocervical anomalies such as basilar impression and basilar invagination.²⁻⁴ Posterior fossa lesions that have been associated with OI are brainstem compression,^{2,3} and Chiari-I malformation with syringomyelia⁴; there has also been an isolated report of Dandy-Walker malformation.⁴

In this article, we report a case of unilateral cerebellar hypoplasia in a young child with OI, and discuss the possible aetiology of cerebellar hypoplasia in this patient. To the best of our knowledge, cerebellar hypoplasia in a patient with OI has not been reported previously.

Case report

A 28-month-old Chinese girl known to have type IV OI, presented to the Queen Mary Hospital with repeated spontaneous fractures of her clavicles and limb bones. She was the first child of a non-consanguineous Chinese couple born

Key words:

Arnold-chiari malformation;
 Magnetic resonance imaging;
 Osteogenesis imperfecta

關鍵詞：

小腦扁桃體延髓聯合畸形；
 磁共振成像；
 成骨不全

Hong Kong Med J 2004;10:211-3

The University of Hong Kong, Queen Mary Hospital, Pokfulam Road, Hong Kong;
 Department of Diagnostic Radiology
 LJ Zhou, PhD
 PL Khong, FRCP
 GC Ooi, MRCP, FRCP
 Department of Paediatrics
 KY Wong, MRCP

Correspondence to: Dr PL Khong
 (e-mail: plkhong@hkucc.hku.hk)

vaginally at 42 weeks' gestation. There were no antenatal or birth complications. Her birthweight was 2.9 kg; body length, 50.5 cm; and head circumference, 33.5 cm. Apgar scores were 7 and 9 at 1 and 5 minutes, respectively. Physical examination at the time of birth showed white sclera in both eyes and normal deciduous dentition. Cytogenetic study revealed a normal karyotype; however, molecular analysis and genetic mutational studies were not available. Subsequent follow-up revealed recurrent fractures after minor injuries in her first year of life. There was progressive scoliosis and the patient's gross motor development was delayed. Her head circumference, body length, and weight fell below the third centiles. Tests for autoimmune markers at the age of 2 years gave negative results. By 28 months of life, the patient could stand only with support, and sit independently for a short period of time. At the recent presentation, she was found to have generalised, non-paralytic hypotonia, as well as third cranial nerve palsy over the left eye. Cerebellar signs were otherwise absent, and she did not experience any seizures.

Magnetic resonance imaging (MRI) demonstrated hypoplasia of the left cerebellar hemisphere and vermis. The left cerebellar hemisphere was small and medially rotated (Fig a). The fissures were of normal size when compared with the those of the folia. The right cerebellar hemisphere was also normal in size. Although the fourth ventricle was asymmetrical and distorted, it was not enlarged. There was also no enlargement of the posterior fossa, and no posterior fossa cyst was detected. No associated anomaly of the corpus callosum and cerebral hemispheres was noted. The ventricles were normal in size. In addition, MRI revealed mild basilar impression and invagination (Fig b) with the Klaus height index measuring 28 mm (ie the height of the posterior fossa—a line drawn perpendicular from the tip of the dens to Twining's line, which is itself a line drawn between the tuberculum and the internal occipital protuberance; normal level, >30 mm). The tip of the dens projected 5 mm above Chamberlain's line (posterior hard palate to opisthion).

Discussion

We describe focal cerebellar hypoplasia and vermian hypoplasia in a child with OI. Cerebellar hypoplasia has not been previously reported in patients with OI or with basilar invagination or impression from other causes. On the other hand, basilar invagination or impression is common in OI and is estimated to occur in about 25% of patients with OI, most commonly in those with type-IV OI.² The pathogenesis of skull base deformities in OI has been proposed to be because of the fact that the weight of the cranium and its contents exceed the weight-bearing capacity of "soft" bones at the skull base; the resulting recurrent microfractures in the region of the foramen magnum with upward translocation of the rostral cervical spine and into the posterior fossa.⁵

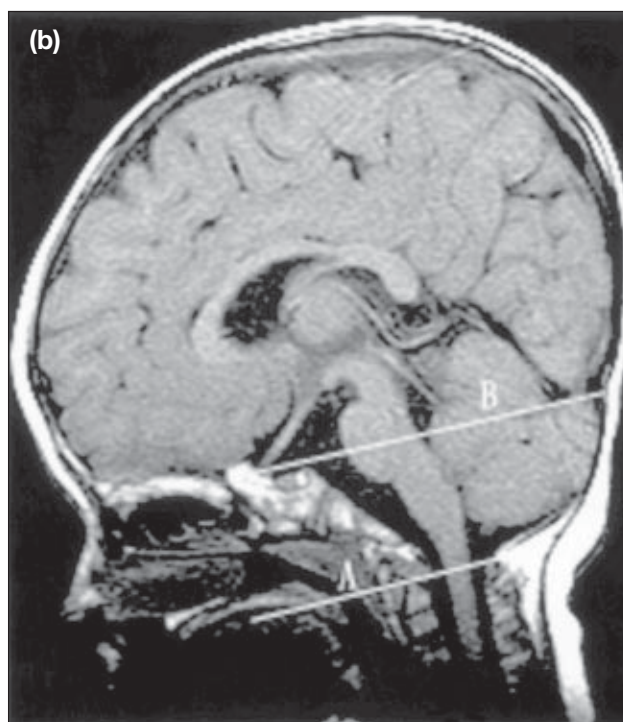
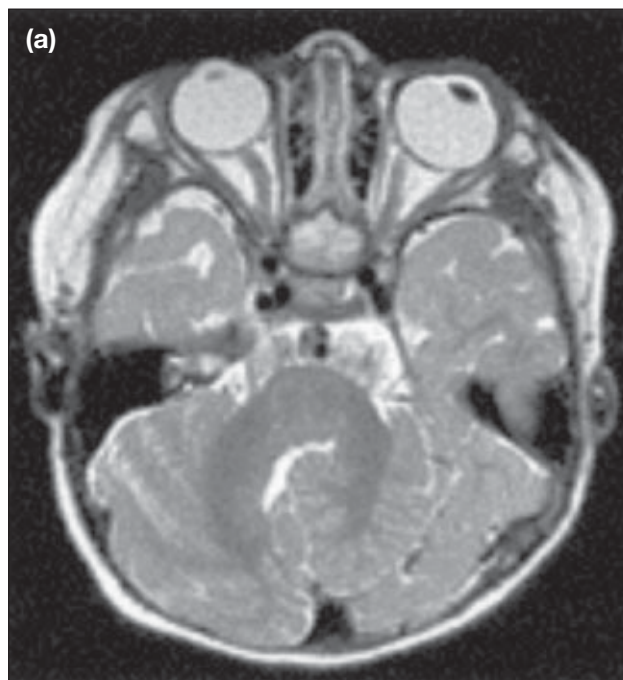


Fig. Osteogenesis imperfecta in a 28-month-old girl

(a) Axial T2-weighted magnetic resonance image of the posterior fossa showing hypoplasia of the left cerebellar hemisphere, which is also medially rotated. The fissures and folia are normal; (b) Sagittal T1-weighted magnetic resonance image of the brain showing mild basilar impression and invagination. The Klaus height index measures 28 mm (A=Chamberlain's line, B=Twining's line)

In this case, we could not determine if cerebellar hypoplasia and OI were associated with each other, or if these were two isolated processes. Hypoplasia of the cerebral hemispheres is found in a wide range of conditions,

including cytomegalovirus infection, chromosomal abnormalities, genetically determined hypoplasias, metabolic disorders, and complex malformations.⁶ Some cases of unilateral cerebellar hypoplasia are due to unexplained prenatal vascular disruption.⁶ In the patient in our case, injury to the posterior circulation may have been secondary to direct compression or vascular disruption related to some event during pregnancy. Reported vascular complications of craniocervical anomalies leading to posterior fossa lesions include vertebral artery dissection,⁷ cerebellar infarction,⁸ and cerebellar atrophy.⁹ Although it is unlikely that basilar invagination or impression per se occurs to a significant degree in utero, it is possible that there is added trauma from minor transient displacement of posterior fossa structures in utero, especially in view of the closely packed neuro-anatomical structures of the posterior fossa. Another possibility is localised trauma in utero from direct compression of the cerebellar hemisphere in foetuses with poorly ossified skulls. Injury to the cerebellum may be compounded by underlying excessive vascular fragility associated with OI.⁷

Recent postmortem studies in fatal (type-II) OI have shown an association between mutations in type-I collagen and malformations in the central nervous system.¹⁰ These malformations include neuronal migration anomalies, such as lissencephaly and abnormal cortical laminations. It has been suggested that type-I collagen may help guide neurone migration during the development of the central nervous system by acting as a guide for outgrowth of neuronal processes.¹⁰ The above-mentioned

cerebral malformations have not been reported in the less severe types of OI. In the patient in our case, there was no MRI evidence of an abnormal folia pattern or the presence of heterotopic nodules of grey matter in the cerebellum to suggest cerebellar dysplasia.¹¹

References

1. Sillence DO. Osteogenesis imperfecta nosology and genetics. *Ann NY Acad Sci* 1988;543:1-15.
2. Sillence DO. Craniocervical abnormalities in osteogenesis imperfecta: genetic and molecular correlation. *Pediatr Radiol* 1994;24:427-30.
3. Hayes M, Parker G, Ell J, Sillence D. Basilar impression complicating osteogenesis imperfecta type IV: the clinical and neuroradiological findings in four cases. *J Neurol Neurosurg Psychiatry* 1999;66:357-64.
4. Charnas LR, Marini JC. Communicating hydrocephalus, basilar invagination, and other neurologic features in osteogenesis imperfecta. *Neurology* 1993;43:2603-8.
5. Frank E, Berger TS, Tew JM Jr. Basilar impression and platybasia in osteogenesis imperfecta tarda. *Surg Neurol* 1982;17:116-9.
6. Boltshauser E. Cerebellar imaging: an important signpost in paediatric neurology. *Childs Nerv Syst* 2001;17:211-6.
7. Schievink WI, Michels VV, Piepgras DG. Neurovascular manifestations of heritable connective tissue disorders. A review. *Stroke* 1994;25:889-903.
8. Ando S, Matsui Y, Fujii J, Nakahara S, Moritake K. Cerebellar infarctions secondary to cranio-cervical anomalies: a case report. *Nippon Geka Hokan* 1994;63:148-54.
9. Goel A, Desai K, Bhatjiwale M, Muzumdar DP. Basilar invagination and Chiari malformation associated with cerebellar atrophy: report of two treated cases. *J Clin Neurosci* 2002;9:194-6.
10. Emery SC, Karpinski NC, Hansen L, Masliah E. Abnormalities in central nervous system development in osteogenesis imperfecta type II. *Pediatr Dev Pathol* 1999;2:124-30.
11. Patel S, Barkovich AJ. Analysis and classification of cerebellar malformation. *AJNR Am J Neuroradiol* 2002;23:1074-87.

Answers to CME Programme *Hong Kong Medical Journal* April 2004 issue

Hong Kong Med J 2004;10:84-8

I. The safety, feasibility, and acceptability of patient-controlled sedation for colonoscopy: prospective study

A	1. False	2. False	3. True	4. True	5. True
B	1. False	2. True	3. False	4. False	5. True

Hong Kong Med J 2004;10:107-16

II. Advances in imaging of the solitary pulmonary nodule

A	1. False	2. True	3. False	4. True	5. False
B	1. True	2. False	3. True	4. False	5. False