

KM Wong 黃劍明
 YL Liu 廖忻麟
 KC Lee 李景中
 KT Leung 梁基泰
 CY Cheung 張志遠
 YH Chan 陳耀恆
 MP Lee 李文寶
 KS Choi 蔡冠誠
 KF Chau 周嘉歡
 PCK Li 李頌基
 CS Li 李俊生

Corticosteroid therapy in a Chinese patient with nephropathy associated with human immunodeficiency virus infection

以皮質類固醇醫治一位受人類免疫缺陷病毒感染的華裔腎病患者

A 52-year-old man with 6 years' history of human immunodeficiency virus infection who was receiving highly active antiretroviral therapy presented with acute renal failure and nephrotic syndrome. Renal biopsy revealed features consistent with nephropathy associated with human immunodeficiency virus infection. Treatment consisted of intravenous methylprednisolone followed by oral prednisolone. The patient's renal function improved, although proteinuria persisted. Human immunodeficiency virus-associated nephropathy is very rare in Asian populations and is more common among blacks. To the best of our knowledge, this is the first documented case of nephropathy associated with human immunodeficiency virus infection occurring in Hong Kong.

本病例的患者為一名 52 歲男性，受人類免疫缺陷病毒（HIV）感染已 6 年，他當時正接受高效抗逆轉錄病毒療法的治療，並出現急性腎衰竭以及腎病綜合徵。其後腎臟活組織檢查顯示伴有 HIV 感染的腎病病徵。病者接受甲潑尼龍靜脈注射，並口服潑尼松龍後，雖然仍有蛋白尿，但腎功能已有所改善。伴有 HIV 感染的腎病，黑人病患者較多，亞洲人則非常罕見。據我們所知，本文報告的病例，即伴有 HIV 感染的腎病，是香港有紀錄以來的第一宗病例。

Key words:

Acquired immunodeficiency syndrome;
 Adrenal cortex hormones;
 AIDS-associated nephropathy;
 Chinese;
 Kidney failure, acute

關鍵詞：

愛滋病（獲得性免疫缺陷綜合徵）；
 腎上腺皮質激素；
 伴有 AIDS 的腎病；
 華裔；
 腎衰竭，急性

Hong Kong Med J 2004;10:201-5

Queen Elizabeth Hospital, 30 Gascoigne Road, Kowloon, Hong Kong;

Department of Medicine

KM Wong, FRCP, FACP

YL Liu, MRCP

KT Leung, MRCP

KS Choi, FRCP

KF Chau, FRCP

PCK Li, FRCP

CS Li, FRCP, FACP

Department of Pathology

KC Lee, FRCPA

CY Cheung, MRCP

YH Chan, MRCP

MP Lee, MRCP

Correspondence to: Dr KM Wong
 (e-mail: wongkmf@ha.org.hk)

Introduction

In 1984, Gardenzward et al¹ reported an association between infection with the human immunodeficiency virus (HIV) and renal diseases; since then, HIV infection has been reportedly associated with an increasing number of different forms of renal disease. The most characteristic pathological finding is focal segmental glomerulosclerosis (FSGS) due to HIV-associated nephropathy (HIVAN). Because of the similarities in clinical and pathological features of HIVAN and those of heroin-induced nephropathy,² the existence of HIVAN has been debated. However, the occurrence of HIVAN among patients without a history of intravenous drug misuse supports the notion that HIVAN is a distinct clinical entity.³

According to the United States Renal Data System, during the era before the introduction of highly active antiretroviral therapy (HAART)—that is, the 1980s and early 1990s—the incidence of end-stage renal failure (ESRF) due to HIVAN rose by more than 75% a year, a rate higher than that at which the incidence of ESRF due to other causes rose in during the same period.⁴ In fact, in the pre-HAART era, patients with HIVAN could progress to ESRF in 1 to 4 months, especially in the presence of combined severe glomerular and tubular injury.⁵ By 1999, HIVAN accounted for approximately 10% of all the new cases of ESRF in the United States. Furthermore, HIVAN is the third most common cause of renal failure (after diabetes and hypertension) among African-Americans aged 20 to 60 years, especially among those with a history of intravenous drug misuse.⁶ Considerable geographical and racial differences exist in the prevalence of HIVAN: HIVAN occurs much more commonly among blacks, males, and

patients with low CD4 counts (<200 /mL) and advanced disease; it is relatively uncommon among homosexual males and Asians.^{7,8}

An estimated 10% of HIV-infected patients will develop HIVAN; about 90% of these cases are among blacks.⁴ It has been argued that the black racial predominance of HIVAN is because of the higher prevalence of FSGS associated with heroin-induced nephropathy among the black population. For example, in 1984, Rao et al⁹ described a syndrome resembling HIVAN among black intravenous drug misusers. However, a black racial predominance of HIVAN has also been suggested in an autopsy study of 239 HIV-positive patients of whom six were blacks¹⁰: the only case of HIVAN diagnosed was in one of these six black patients. The increased predilection of renal diseases among blacks is not unexpected, given their increased prevalence of other renal diseases such as diabetic, hypertensive, and lupus nephropathy. The marked racial disparity suggests that genetic factors have an important role in the pathogenesis of HIVAN.⁵

Since the introduction of HAART, there has been a marked reduction in the mortality rate of patients with acquired immunodeficiency syndrome (AIDS). Although the rise in the incidence of new cases of ESRF due to HIVAN seems to have ceased, the actual number of new patients per year has not decreased and fluctuates around 900 cases per year.⁴ This finding may reflect the increasing prevalence of HIV infection in the United States, particularly among the black population, thereby increasing the pool of patients who are at risk of developing ESRF attributed to HIVAN.

In general, HIVAN occurs in patients who have harboured HIV infection for a few years. The cardinal features of HIVAN comprise a pentad of massive proteinuria, azotaemia (uraemia), enlarged echogenic kidneys on ultrasound imaging, normal systemic blood pressure, and a collapsing form of FSGS as detected by renal biopsy.⁶ The pathogenesis of HIVAN is not completely understood. Both direct viral effects and indirect immune responses to HIV-related changes—for example in levels of interleukin-6 and tumour necrosis factor α —have been suggested as causes.⁵ The use of complementary DNA probes and in-situ hybridisation has allowed the detection of the HIV genome in the glomerular and tubular epithelium.¹¹ However, the HIV genome has also been detected in the kidneys of HIV-positive patients with other glomerulopathies.⁵

Animal models provide evidence for a direct role of HIV-1 in HIVAN. In a transgenic mouse model, HIV-1 *gag* and *pol* genes were deleted to render the virus non-infectious, but when the envelope and regulatory genes were expressed at levels sufficient to recreate HIVAN, renal diseases that closely resembled HIVAN developed in these animals.¹² The characteristic collapsing FSGS attributed to the loss of differentiation markers and abnormal proliferation of

podocytes.¹³ These findings suggest that viral expression in the kidney may induce the development of HIVAN.

In this article, we describe the clinical course of HIVAN in a Chinese patient. To the best of our knowledge, this is the first documented case of nephropathy associated with HIV infection occurring in Hong Kong.

Case report

In 1996, a 52-year-old Chinese man received a diagnosis of HIV infection when he presented to a regional hospital with miliary tuberculosis. He had acquired the infection during heterosexual intercourse, and had no history of intravenous drug misuse. The patient was treated with a course of antituberculous therapy and his condition improved. He also received ziduvudine and didanosine therapy. In view of the dropping CD4 count (from 546 /mL to 198 /mL), however, a course of HAART comprising lamivudine, stavudine, and indinavir was started in 1999. His CD4 count subsequently rose to 600 /mL.

The patient defaulted follow-up treatment for 1 year until he experienced a relapse of pulmonary tuberculosis in 2000. Antituberculous therapy and HAART, comprising lamivudine, stavudine, and indinavir, were restarted. His condition was clinically stable for approximately 2 years, when he was referred for evaluation to Queen Elizabeth Hospital of deteriorating renal function and bilateral lower extremity oedema. Indinavir therapy was switched to nevirapine therapy to avoid the possibility of nephrolithiasis, which may have complicated the clinical course. He was otherwise asymptomatic and had no postural dizziness. He gave no history of nephrolithiasis, urinary tract infection, excessive use of non-steroidal anti-inflammatory drugs, and use of herbal medicine, intravenous drug misuse, or other systemic complaints.

Results of a physical examination were unremarkable, except for bilateral ankle oedema. The patient was afebrile and his blood pressure and heart rate were 130/80 mm Hg and 80 beats per minute, respectively. There was no postural hypotension noted. Initial laboratory evaluations revealed a serum creatinine level of 206 μ mol/L (the serum creatinine level 1 year previously had been 120 μ mol/L, which was already compatible with a mild degree of renal dysfunction; reference range, 53-106 μ mol/L) and a serum albumin level of 21 g/L (reference range, 35-50 g/L). He also had proteinuria at a rate of 15 g/d. Microscopy of a urine sample showed one dysmorphic red blood cell per high-power field, but no leukocytes, eosinophils, cellular casts, or crystals. Results of serological tests for hepatitis B and C, rheumatoid factor, antinuclear antibody, anti-glomerular basement membrane antibody and anti-neutrophil cytoplasmic antibody were all negative. His serum complement C3 level was normal at 1.05 g/L (reference range, 0.9-1.8 g/L). His CD4 count was 437 /mL with an undetectable viral load in his serum. Renal ultra-

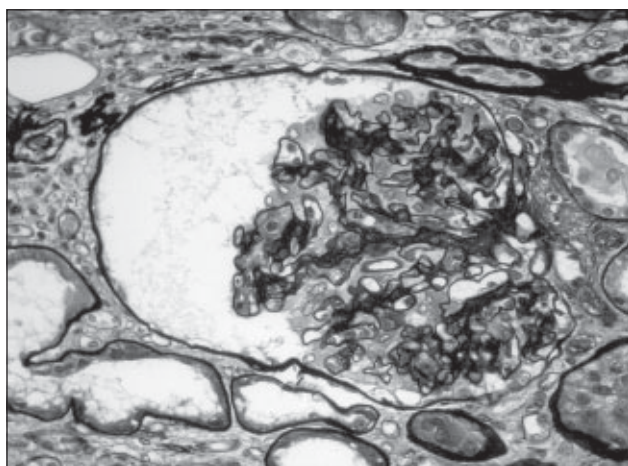


Fig 1. A glomerulus showing early changes with collapsed glomerular tuft, dilated Bowman's space and mild visceral epithelial cell proliferation

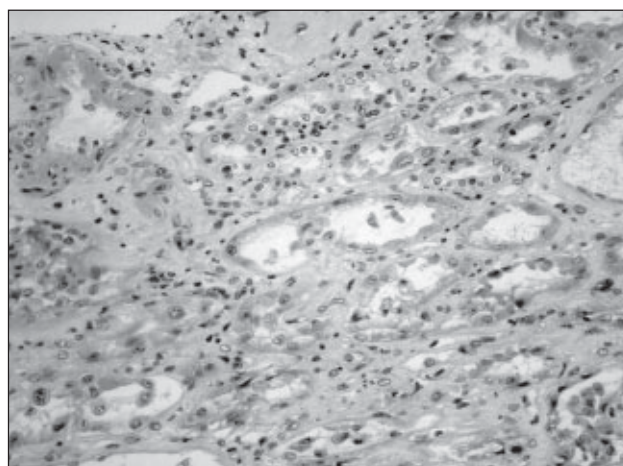


Fig 2. Interstitial oedema associated with mild infiltration of plasma cells and lymphocytes (left upper field)
There is also mild tubulitis, and in the centre, a dilated tubule with degenerative changes in the lining epithelium is visible (H&E)

sonography showed normal-sized kidneys with slightly increased echogenicity but preserved corticomedullary differentiation. However, renal function deteriorated further; the serum creatinine level rose to 440 μM over the next few days. Renal biopsy was then performed to determine the underlying cause of his acute-on-chronic renal failure.

Renal biopsy revealed a combination of glomerular and tubulo-interstitial disease. The glomeruli showed features of FSGS, some of which were associated with endocapillary proliferation; features of immune complex deposition were absent. Moreover, occasional glomerular tufts were collapsed and early, mild visceral epithelial cell proliferation was evident, as was dilatation of Bowman's space (Fig 1)—signs suggestive of a collapsing variant of FSGS. In the interstitium, interstitial oedemas were detected, which were due to lymphocyte and plasma cell infiltration. The tubules also showed focal dilatation, attenuation of lining epithelium, and sloughing of epithelial cells into the lumen (Fig 2). However, the typical cast-filled, dilated tubules were not found. Electron microscopy showed extensive effacement of visceral epithelial cell foot processes, but did not reveal any electron-dense deposits. Tubuloreticular inclusions were not found, but occasional nuclear bodies were. The histological findings were compatible with HIVAN.

Because of his deteriorating renal function, the patient was given intravenous pulse methylprednisolone at a dose of 500 mg/d for 3 days followed by oral prednisolone (40 mg/d). Furthermore, HAART was continued, with the dosage of stavudine and lamivudine adjusted according to renal function. The patient showed a satisfactory response to steroid therapy: the serum creatinine level decreased from a peak of 440 μM to 160 μM over the next 2 weeks. His clinical course was complicated by the development of right lower-lobe pneumonia attributed to *Acinetobacter* infection and septic shock. His condition improved after treatment with piperacillin and tazobactam and fluid resuscitation. He

no longer had ankle oedema and was discharged from hospital, when serum creatinine and albumin levels were 167 μM and 20 g/L, respectively. When the patient was seen 8 weeks after initiation of steroid therapy, his renal function had further improved: the serum creatinine level had decreased to 119 μM and albumin level had increased to 33 g/L; proteinuria had decreased to 1 g/d.

Discussion

In Hong Kong, HIV infection and AIDS were first reported in 1984 and 1985, respectively. As of August 2003, the cumulative number of reported HIV infections in Hong Kong was 2116.¹⁴ So far, HIVAN in a Hong Kong Chinese patient has not been reported in the literature.

The most typical histological finding of HIVAN on light microscopy is a collapsing form of FSGS. There may be collapse of glomerular capillaries and obliteration of the capillary lumina, associated with segmentally or globally sclerosed glomeruli. The microcystic dilatation and cast-containing renal tubules may contribute to an increased kidney size by as much as 25%. Podocyte hyperplasia may cause obliteration of Bowman's space, thereby forming a characteristic 'pseudocrescent'.^{6,15} The interstitium is oedematous and shows a variable degree of T-cell infiltration. Immunofluorescence may reveal segmental granular immunoglobulin M and C3 deposits in capillary walls.⁶ Electron microscopy shows wrinkled basement membranes, proliferation of epithelial cells, and effacement of focal foot processes. Tubuloreticular inclusions can also be seen within the cytoplasm of glomerular and peritubular capillary endothelial cells consisting of ribonucleoprotein and membrane material stimulated by α -interferon.¹⁵ In the HAART era, as in this case, tubuloreticular inclusion bodies are less commonly seen, thereby reflecting the efficacy of HAART in reducing the systemic α -interferon level.¹⁶ Although the histological features of HIVAN seem

quite specific, similar lesions and collapsing glomerulopathy have been reported among patients with parvovirus B19 infection and in patients receiving high-dose pamidronate therapy, which may also induce visceral epithelial cell injury.¹⁷

No standard therapy for HIVAN has been developed, but there are anecdotal reports indicating that corticosteroid therapy,¹⁸ HAART,¹⁹ and angiotension-converting enzyme inhibitor therapy²⁰ could help decrease the rate of progression of renal failure in patients with HIVAN. Although the effects of HAART on the progression of HIVAN have not been evaluated in any controlled clinical trials, HAART has been reported to be effective in reducing proteinuria and causing regression of glomerular pathology. Without HAART, patients with HIVAN progressed to end-stage renal disease within weeks to months. The prognosis improved with HAART.^{5,19,21} This improvement may result in a slower progression to ESRF. However, as in our case report, the development of HIVAN cannot be prevented despite an apparently maximum suppression of viral replication by HAART.

In the patient in our case, the serum creatinine level decreased considerably after corticosteroid therapy. The efficacy of corticosteroid therapy in stabilising renal function in patients with HIVAN has been reported in a number of case reports and small-scale retrospective studies.^{5,18} In view of the potential serious infective complications of corticosteroid therapy, this treatment should be limited to short-term use in patients with biopsy-proven HIVAN and significant renal dysfunction without active infective complications. Patients should be treated with an optimal dose of HAART to prevent viral replication during immunosuppressive therapy.

It is important to note that besides HIVAN, acute renal failure due to other coincidental renal disorders, such as acute tubular necrosis, may occur even more frequently. Patients who are HIV-positive tend to be at a particular risk for acute renal failure because of infection, hypotension, nephrotoxic drugs (eg amphotericin B, pentamidine, or aminoglycosides), intratubular obstruction due to crystal precipitation (eg during treatment with sulphadiazine, acyclovir, or indinavir), other glomerulopathies (including heroin-induced nephropathy), thrombotic thrombocytopenic purpura, and haemolytic uraemic syndrome.²² Therefore, renal biopsy is needed to identify the underlying renal disease even in HIV-positive patients presenting with classical features of HIVAN. It has been reported that clinical features can distinguish HIVAN from other renal diseases in only 55% to 60% of cases.⁷ In addition, electrolyte abnormalities, including hyponatraemia and hyperkalaemia attributed to type IV renal tubular acidosis, can manifest as hyperkalaemic normal anion gap metabolic acidosis.⁵

Most HIV medications are well tolerated. However,

given the frequent administration of a large number of drugs to HIV-positive patients, the possibility of adverse drug effects on the kidneys should always be considered. Dose adjustment, especially of nucleoside reverse transcriptase inhibitors (eg ziduvudine, didanosine, stavudine, and lamivudine), should be made in patients receiving HARTT when the glomerular filtration rate is below 50 mL/min. This also applies to drugs that are used to treat opportunistic infections because they can cause nephrotoxicity and other electrolyte abnormalities.

In conclusion, since the first description of HIVAN,⁹ much has been reported regarding the epidemiology, pathogenesis, and treatment of the disease. However, despite all these advances, HIVAN continues to be an important cause of renal failure in HIV-positive patients, especially among blacks. There is preliminary evidence that HAART and corticosteroid therapy are associated with a reduced rate of decline in creatinine clearance. Larger-scale controlled prospective clinical trials are warranted to determine the efficacy and safety of HAART, corticosteroid, and other novel therapies for the treatment of HIVAN.

References

1. Gardenzwartz MH, Lerner CW, Seligson GR, et al. Renal disease in patients with AIDS: a clinicopathologic study. *Clin Nephrol* 1984;21:197-204.
2. Mazbar SA, Schoenfeld PY, Humphreys MH. Renal involvement in patients infected with HIV: experience at San Francisco General Hospital. *Kidney Int* 1990;37:1325-32.
3. Pardo V, Meneses R, Ossa L, et al. AIDS-related glomerulopathy: occurrence in specific risk groups. *Kidney Int* 1987;31:1167-73.
4. US Renal Data System (USRDS): USRDS 2001 annual data report. Bethesda MD: The National Institutes of Health, National Institute of Diabetes and Digestive and Kidney Diseases; 2001.
5. Ross MJ, Klotman PE. Recent progress in HIV-associated nephropathy. *J Am Soc Nephrol* 2002;13:2997-3004.
6. Cohen AH. HIV-associated nephropathy: current concepts. *Nephrol Dial Transplant* 1998;13:540-2.
7. Winston JA, Klotman ME, Klotman PE. HIV-associated nephropathy is a late, not early, manifestation of HIV-1 infection. *Kidney Int* 1999;55:1036-40.
8. Praditpornsilpa K, Napathorn S, Yenrudi S, Wankrairo P, Tungsaga K, Sitprija V. Renal pathology and HIV infection in Thailand. *Am J Kidney Dis* 1999;33:282-6.
9. Rao TK, Filippone EJ, Nicastrì AD, et al. Associated focal and segmental glomerulosclerosis in acquired immunodeficiency syndrome. *N Engl J Med* 1984;310:669-73.
10. Hailemariam S, Walder M, Burger HR, et al. Renal pathology and premortem clinical presentation of Caucasian patients with AIDS: an autopsy study from the era prior to antiretroviral therapy. *Swiss Med Wkly* 2001;131:412-7.
11. Cohen AH, Sun NC, Shapshak P, Imagawa DT. Demonstration of human immunodeficiency virus in renal epithelium in HIV-associated nephropathy. *Mod Pathol* 1989;2:125-8.
12. Schwartz EJ, Klotman PE. Pathogenesis of human immunodeficiency virus (HIV)-associated nephropathy. *Semin Nephrol* 1998;18:436-45.
13. Barisoni L, Bruggeman LA, Mundel P, D'Agati VD, Klotman PE. HIV-1 induces renal epithelial dedifferentiation in a transgenic model of HIV-associated nephropathy. *Kidney Int* 2000;58:173-81.
14. Hong Kong: Public Health and Epidemiology Bulletin 2003;12:48.

15. D'Agati V, Appel GB. Renal pathology of human immunodeficiency virus infection. *Semin Nephrol* 1998;18:406-21.
16. Stylianou E, Aukrust P, Bendtzen K, Muller F, Froland SS. Interferons and interferon (IFN)-inducible protein 10 during highly active anti-retroviral therapy (HARRT)-possible immunosuppressive role of IFN-alpha in HIV infection. *Clin Exp Immunol* 2000;119:479-85.
17. Schwimmer JA, Markowitz GS, Valeri A, Appel GB. Collapsing glomerulopathy. *Semin Nephrol* 2003;23:209-18.
18. Smith MC, Pawar R, Carey JT, et al. Effect of corticosteroid therapy on human immunodeficiency virus-associated nephropathy. *Am J Med* 1994;97:145-51.
19. Wali RK, Drachenberg CI, Papadimitriou JC, Keay S, Ramos E. HIV-1-associated nephropathy and response to highly-active antiretroviral therapy. *Lancet* 1998;352:783-4.
20. Kimmel PL, Mishkin GJ, Umana WO. Captopril and renal survival in patients with immunodeficiency virus nephropathy. *Am J Kidney Dis* 1996;28:202-8.
21. Winston JA, Burns GC, Klotman PE. Treatment of HIV-associated nephropathy. *Semin Nephrol* 2000;20:293-8.
22. Peraldi MN, Maslo C, Akposso K, Mougenot B, Rondeau E, Sraer JD. Acute renal failure in the course of HIV infection: a single-institution retrospective study of ninety-two patients and sixty renal biopsies. *Nephrol Dial Transplant* 1999;14:1578-85.