

ACY Chan 陳智仁  
CL Liu 廖子良

# The role of endoscopic ultrasonography in the management of cystic lesions of the pancreas

## 內窺鏡超聲波檢查在治療胰腺囊性病變的作用

**Objective.** To review the role of endoscopic ultrasonography in the management of cystic lesions of the pancreas.

**Data sources.** MEDLINE literature search (1998-2003).

**Study selection.** Key words for the literature search were 'endoscopic ultrasonography', 'pancreas', 'pseudocyst', and 'cystic tumor'.

**Data extraction.** All relevant studies were reviewed.

**Data synthesis.** In the management of cystic lesions of the pancreas, endoscopic ultrasonography appears to be superior to percutaneous ultrasonography, computed tomography, and endoscopic retrograde cholangiopancreatography, because it can achieve detailed imaging of both the pancreatic parenchymal tissue and the ductal anatomy simultaneously with a high-frequency ultrasound examination at a close proximity. Endoscopic ultrasonography can differentiate benign pseudocysts or benign cystic lesions from malignant neoplasms of the pancreas; the distinction is crucial in the surgical treatment of the patients. The diagnostic accuracy can be further enhanced with endoscopic ultrasonography-guided fine-needle aspiration of the cystic fluid to detect tumour markers and cytological examination. Endoscopic ultrasonography-guided aspiration with or without endoscopic cystogastrostomy or cystoduodenostomy has become the treatment of choice for patients with pancreatic pseudocysts. The procedure is associated with decreased morbidity and mortality when compared with open surgery.

**Conclusion.** Endoscopic ultrasonography appears to be a useful tool in the management of cystic lesions of the pancreas.

**目的：**回顧內窺鏡超聲波檢查在治療胰腺囊性病變中的作用。

**資料來源：**MEDLINE 文獻檢索（1998 至 2003 年）。

**研究選取：**以「內窺鏡超聲波檢查」、「胰臟」、「假性囊腫」及「囊腫」為關鍵詞檢索文獻。

**資料選取：**回顧所有有關的資料及數據。

**資料綜合：**在治療胰腺囊性病變中，內窺鏡超聲波檢查的表現比經皮膚超聲波檢查、電腦斷層掃描及內窺鏡逆行胰膽管造影術都優勝；因為透過近距離高頻率的超聲波檢查，內窺鏡超聲波檢查可同時獲得胰腺實質及管道解剖的詳細圖像。內窺鏡超聲波檢查能將胰腺良性假性囊腫或良性囊性病變與惡性腫瘤區分，而此區別對於病人的外科治療至關重要。診斷的準確性可通過在內窺鏡超聲波引導下，以細針抽取囊液作腫瘤標記物及細胞學檢查進一步提昇。無論是否配合內窺鏡胰囊腫胃吻合術或胰囊腫十二指腸吻合術，在內窺鏡超聲波引導下以細針抽取囊液，已成為治療胰腺假性囊腫的首選療法。與開腹手術相比，其併發症及死亡率均較低。

**結論：**內窺鏡超聲波檢查在治療胰腺囊性病變方面，是一種有效的方法。

### Key words:

Endosonography;  
Pancreatic neoplasms;  
Pancreatic pseudocyst

### 關鍵詞：

內窺鏡超聲波檢查；  
胰臟癌；  
假性胰腺囊腫

Hong Kong Med J 2003;9:441-5

Department of Surgery, The University of  
Hong Kong, Queen Mary Hospital,  
Pokfulam Road, Hong Kong  
ACY Chan, MB, BS  
CL Liu, FRCS (Edin), FACS

Correspondence to: Dr CL Liu  
(e-mail: clliu@hkucc.hku.hk)

## Introduction

Endoscopic ultrasonography is one of the most important areas of development in gastrointestinal endoscopy. It is an invaluable tool in the diagnosis, staging, and management of most upper and lower gastrointestinal disorders,<sup>1</sup> such as oesophagogastric tumours,<sup>2,3</sup> oesophageal varices,<sup>4</sup> Barrett's oesophagus,<sup>5</sup> rectal cancer<sup>3,6,7</sup> and other rectal diseases.<sup>8</sup> Endoscopic ultrasonography is also very

**Table. Fluid analysis of cystic lesions of the pancreas**

Cystic lesion	Viscosity	CEA*	CA-72.4	Amylase	Cytology
Pseudocyst	Low	Low	Low	High	Inflammatory
Serous cystadenoma	Low	Low	Low	Usually low	25%-50% positive
Mucinous cystadenoma	Usually high	High	Low	Usually low	40% positive
Mucinous cystadenocarcinoma	High	High	High	Usually low	67% positive

\* CEA = carcinoembryonic antigen

useful in the management of diseases of the lung<sup>9,10</sup> and thyroid,<sup>11</sup> mediastinal tumours,<sup>12</sup> and diseases of the gastrointestinal tract. In this article, we review the role of endoscopic ultrasonography in the management of cystic lesions of the pancreas.

Approximately 90% of all cystic lesions of the pancreas are benign pseudocysts, which are related to acute and chronic pancreatitis, and trauma. The remaining 10% of cases are cystic neoplasms.<sup>13,14</sup> The conventional imaging methods that are used to diagnose cystic tumours of the pancreas are transabdominal ultrasonography, abdominal computed tomography (CT) and endoscopic retrograde cholangiopancreatography (ERCP). Computed tomography is useful in demonstrating any involvement of parenchymal tissue, whereas ERCP, despite its invasiveness, is more effective in visualising the ductal anatomy.<sup>15,16</sup> Endoscopic ultrasonography appears to be superior to both CT and ERCP, because it can achieve a detailed image of both pancreatic parenchymal tissue and the ductal anatomy at the same time.<sup>17</sup>

Endoscopic ultrasonography is a combination of two investigation modalities—namely, endoscopic visualisation and high-frequency ultrasonography.<sup>18,19</sup> Two types of endoscopic ultrasonography are commonly used: mechanical radial echo-endoscopy, which provides 360° images perpendicular to the longitudinal axis of the endoscope, and curvilinear electronic array endoscopy, which provides images sagittal to the longitudinal axis of the endoscope. Both types of endoscopy can operate at different frequencies, thereby allowing different depths of penetration. The close proximity of the pancreas to the stomach and duodenum is well within the range of endoscopic ultrasonography. Hence, the head, body, and tail of the pancreas can be visualised clearly, and the pancreatic duct can also be examined in detail.<sup>1,20,21</sup>

### Pancreatic pseudocyst

Pancreatic pseudocysts may develop as a complication of acute or chronic pancreatitis, trauma, or pancreatic duct obstruction by tumour. Small pseudocysts usually do not require intervention, and spontaneous resolution is common. In contrast, spontaneous resolution occurs less frequently in large pseudocysts, and the risk of developing a complication is high. It has been recommended that any pseudocysts larger than 6 cm and persistent for more than 6 weeks be drained.<sup>22-24</sup> Management of

pancreatic pseudocysts consists of surgical drainage, percutaneous drainage under the guidance of ultrasonography or CT, or endoscopic drainage. Although surgical drainage has been the standard treatment, it is associated with significant operative morbidity rate of 10% and mortality rate of about 1%.<sup>24</sup> In the past decade, percutaneous and endoscopic drainage has become the treatment of choice for pseudocysts and has gradually replaced surgical drainage in most cases.<sup>25,26</sup>

Endoscopic ultrasonography plays both diagnostic and therapeutic roles in the management of pancreatic pseudocysts. During the examination, pseudocysts may appear uniloculated or multilocated. The cyst wall and the septa are usually thin and are made up of fibrous tissue. Although a clinical history of pancreatitis may make the diagnosis of simple pancreatic pseudocyst more likely, it can be difficult to distinguish pancreatic pseudocysts from cystic neoplasms by using endoscopic ultrasonography alone.<sup>27</sup> However, endoscopic ultrasonography-guided aspiration and cystic fluid analysis can be very helpful in achieving the diagnosis. Aspirates from pancreatic pseudocysts usually yield fluid with a high level of amylase, low levels of tumour markers, and inflammatory cells (Table).<sup>14,28-32</sup>

Endoscopic ultrasonography-guided drainage has become the treatment of choice for complicated pancreatic pseudocysts; the method has a high success rate and causes minimal morbidity and mortality.<sup>33</sup> The most common route of drainage is through either the stomach or the duodenum. As a general rule for safe drainage, the maximum distance between the pseudocyst and the gut lumen should be less than 1 cm. Any greater distance increases the risk of perforation during endoscopic drainage. In addition, identification of the indentation in the gut wall created by the bulk of the pseudocyst gives a rough guide to the pseudocyst's exact location in relation to the gut lumen.<sup>33</sup> The presence of anechoic material inside the cystic cavity indicates an ideal lesion for endoscopic ultrasonography-guided drainage. On the other hand, substantial hyper-echoic material indicates the presence of debris or necrotic tissue, which in turn would prompt the endoscopist to use endoprosthesis for optimal drainage. Endoscopic ultrasonography can also detect any vascular structure in the wall or in between the pseudocyst and the gut wall, including varices and retroperitoneal vessels. Avoidance of such structures on needle passage during drainage is crucial in minimising the associated risk of haemorrhage.<sup>33</sup>

## Serous cystadenoma

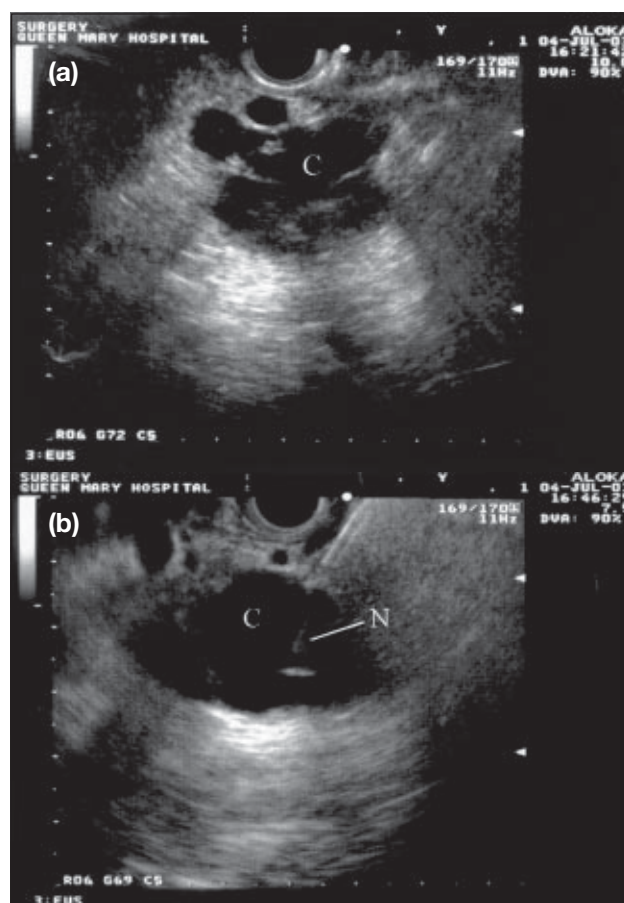
Using endoscopic ultrasonography, serous cystadenoma (SCA) typically appears as multiple microcystic compartments with thin septations. Depending on the size of the tumour, a large SCA can occasionally appear as a single macrocystic lesion. Another morphological feature of SCA is the presence of central calcifications in about 15% of all cases. In addition, SCA can typically appear as an anechoic lesion. In contrast, the presence of mixed hyperechoic signals are likely to be associated with debris and are more commonly found in mucinous cystadenomas (MCAs). The fact that most cases of SCA are microcystic lesions has rendered endoscopic ultrasonography-guided fine-needle aspiration (FNA) less reliable, because it is difficult to pass the needle into the small-size compartments. Acellularity in the aspiration fluid can make up to 50% of all cases and result in a diagnostic accuracy of only 25%.<sup>16,34</sup> However, the presence of glycogen-rich cells in the cyst aspirate is a diagnostic feature of SCA.<sup>13</sup>

## Mucinous cystadenoma and mucinous cystadenocarcinoma

Mucinous cystadenoma is the most common primary cystic tumour of the pancreas, accounting for about 45% of all cases. There is a female preponderance and middle-aged women are mostly affected. Mucinous cystadenoma is recognised as a group of tumours with heterogeneous pathological features, ranging from slow-growing benign tumour to aggressive malignant mucinous cystadenocarcinoma (MCAC). In more than half of cases, histological examination of the resected tumour reveals co-existing benign and malignant epithelia. Hence, MCA is generally regarded as potentially malignant, and surgical resection is considered as first-line treatment.

The typical features of MCA under endoscopic ultrasonography are macrocystic, single loculation, and peripheral calcification. Sometimes, a large MCA could be divided by thin septae that form multiple fluid-filled compartments. The lining of the wall is relatively thin, and the lesion is usually well demarcated from the pancreas. Floatation of mucus within the cystic fluid is sometimes visible.<sup>35</sup> A large multiloculated lesion should warrant surgical resection in view of the risk of malignant transformation. Similarly, a single loculated lesion in the absence of a clinical history of pancreatitis or pancreatic trauma should also be resected, owing to the likelihood of a mucinous neoplasm. However, a diagnostic challenge will arise when a multiloculated lesion is found in a patient who has a history of pancreatitis or pancreatic trauma. In this case, FNA with cystic fluid analysis will increase the diagnostic accuracy of endoscopic ultrasonography.

The combination of ultrasonography and CT is



**Fig. (a)** Picture of endoscopic ultrasonography showing a multiloculated cyst (C) with echogenic material at the neck of the pancreas, compatible with mucinous cystadenocarcinoma. **(b)** Endoscopic ultrasonography-guided aspiration with a 21-gauge needle (N) of the lesion (C) yielding thick clear fluid; biochemical analyses of the aspirate showed a low amylase level (<70 U/L) and a very high carcinoembryonic antigen level (>10 000 ng/mL)

inaccurate in the diagnosis of MCAC, and 40% to 60% of cases can be misinterpreted as pseudocyst.<sup>35</sup> This can be explained by the limited spatial resolution of these two imaging modalities and the pathological features of MCAC. Typically, MCAC is a thick-walled macrocyst with intracystic mural nodules or extracystic solid components in small tumours. A dilated pancreatic duct is present in about 80% of cases. Endoscopic ultrasonography has a higher spatial resolution than ultrasonography and CT, and so it can clearly delineate the internal architecture of the pancreatic parenchyma precisely. Endoscopic ultrasonography might also be more sensitive in detecting cystic tumours of less than 2 cm in diameter.<sup>36</sup> The overall 5-year survival rate for resected MCAC is more than 50%, and curative resection can be achieved in 74% of patients.<sup>37</sup> The prognosis of unresected MCAC is dismal and comparable with unresected pancreatic adenocarcinoma. Hence, an aggressive surgical approach may be justified for radical resection of MCAC, even when there is local spread to neighbouring structures.



## Fine-needle aspiration and cystic fluid analysis

It has been reported that FNA and cystic fluid analysis significantly increase the accuracy of the diagnosis of pancreatic cystic tumour (Fig).<sup>30,38</sup> Cystic fluid analysis with various tumour markers and enzymes have been extensively studied (Table). Nevertheless, it is important to appreciate that no single marker is specific enough to differentiate between benign lesions and malignant tumours. Cystic fluid in mucinous cystic tumour is generally more viscous than SCA and pancreatic pseudocysts. It may be related to the high protein concentration of the cystic fluid, although differences in total protein concentration among various cystic lesions are yet to be determined.<sup>30,38</sup> The level of amylase is significantly higher in pancreatic pseudocysts than in cystic neoplasms of the pancreas, because pseudocysts frequently communicate with the pancreatic ductal system. A high level of amylase itself is the single most important determinant factor in establishing the diagnosis of pseudocysts.<sup>30,39</sup>

Carcinoembryonic antigen (CEA) is a good tumour marker to differentiate mucinous lesion from non-mucinous neoplasms: the former is associated with a high CEA level. The presence of CEA is usually normal in pseudocysts and SCA. A CEA level of more than 400 ng/mL (>400 µg/L) is potentially predictive of malignancy.<sup>30,39</sup> CA-72.4 has been increasingly recognised as one of the best tumour markers in differentiating MCAC from benign pseudocysts. Although studies with other tumour markers such as CA-19.9 and CA-15.3 have also shown promising results, the sensitivities and specificities of measuring levels of these markers appear to be inferior to those of measuring CA-72.4 in detecting MCAC. Sperti et al<sup>40</sup> reported a sensitivity of 87.5% and a specificity of 94.0% of CA-72.4 in the detection of mucinous tumours. Expression of CA-72.4 may occur during the malignant transformation of a benign mucinous cystic tumour.<sup>41</sup>

Cyst-fluid cytology is useful in diagnosing MCA and MCAC through the identification of mucin epithelial cells and malignant cells, respectively. When positive cells are present, the specificity of fluid cytology is close to 100%. However, cyst-fluid cytology is often negative, and inadequate cystic fluid sampling also jeopardises the reliability of this technique. Centeno et al<sup>32</sup> reported a prospective evaluation of FNA on 28 radiographically identified cysts. The overall accuracy of cyst-fluid cytology was 40% for mucinous cysts and 67% for malignant cystic tumours.

The technique of FNA of cystic tumours of the pancreas is similar to FNA of pancreatic solid masses.<sup>42</sup> However, in view of the fluid component of the tumour, multiple needle punctures would certainly increase the risk of perforation and cystic rupture. Hence, a single-needle pass technique is usually adopted. Although there is a theoretic risk of needle tract tumour seeding during FNA for suspected malignant cystic lesions, such a complication has yet to be reported.

## Conclusion

Endoscopic ultrasonography is a useful diagnostic tool in the assessment of cystic lesions of the pancreas. It can help to avoid characterising a mucinous cyst as a benign serous cyst and erroneously opting for simple observation instead of choosing early surgical resection for cure. Endoscopic ultrasonography-guided FNA with cystic fluid analysis can further enhance the diagnostic accuracy. Endoscopic ultrasonography-guided drainage is the treatment of choice in most patients with pancreatic pseudocysts.

## References

- Fickling WE, Wallace MB. Endoscopic ultrasound and upper gastrointestinal disorders. *J Clin Gastroenterol* 2003;36:103-10.
- Moreto M. Diagnosis of esophagogastric tumors. *Endoscopy* 2003; 35:36-42.
- Heidemann J, Schilling MK, Schmassmann A, Maurer CA, Buchler MW. Accuracy of endoscopic ultrasonography in preoperative staging of esophageal carcinoma. *Dig Surg* 2000;17:219-24.
- Irisawa A, Saito A, Obara K, et al. Usefulness of endoscopic ultrasonographic analysis of variceal hemodynamics for the treatment of esophageal varices. *Fukushima J Med Sci* 2001;47:39-50.
- Scotiniotis IA, Kochman ML, Lewis JD, Furth EE, Rosato EF, Ginsberg GG. Accuracy of EUS in the evaluation of Barrett's esophagus and high-grade dysplasia or intramucosal carcinoma. *Gastrointest Endosc* 2001;54:689-96.
- Wiersema MJ, Harewood GC. Endoscopic ultrasound for rectal cancer. *Gastroenterol Clin North Am* 2002;31:1093-105.
- Marone P, Petruccio F, de Bellis M, Battista Rossi G, Tempesta A. Role of endoscopic ultrasonography in the staging of rectal cancer: a retrospective study of 63 patients. *J Clin Gastroenterol* 2000;30: 420-4.
- Schwartz DA, Harewood GC, Wiersema MJ. EUS for rectal disease. *Gastrointest Endosc* 2002;56:100-9.
- Wang J, Sun Y, Wang Z, Wang X. Endoscopic ultrasonography guided fine-needle aspiration in diagnosis of lung neoplasm and mediastinal lymph node metastasis [in Chinese]. *Zhonghua Wai Ke Za Zhi* 2002; 40:743-5.
- Fritscher-Ravens A, Bohuslavizki KH, Brandt L, et al. Mediastinal lymph node involvement in potentially resectable lung cancer: comparison of CT, positron emission tomography, and endoscopic ultrasonography with and without fine-needle aspiration. *Chest* 2003; 123:442-51.
- Koike E, Yamashita H, Noguchi S, et al. Endoscopic ultrasonography in patients with thyroid cancer: its usefulness and limitations for evaluating esophagopharyngeal invasion. *Endoscopy* 2002;34:457-60.
- Catalano MF, Rosenblatt ML, Chak A, Sivak MV Jr, Scheiman J, Gress F. Endoscopic ultrasound-guided fine needle aspiration in the diagnosis of mediastinal masses of unknown origin. *Am J Gastroenterol* 2002; 97:2559-65.
- Fernandez-del Castillo C, Warshaw AL. Cystic tumors of the pancreas. *Surg Clin North Am* 1995;75:1001-16.
- Gress F, Gottlieb K, Cummings O, Sherman S, Lehman G. Endoscopic ultrasound characteristics of mucinous cystic neoplasms of the pancreas. *Am J Gastroenterol* 2000;95:961-5.
- Ooi LL, Ho GH, Chew SP, Low CH, Soo KC. Cystic tumours of the pancreas: a diagnostic dilemma. *Aust NZ J Surg* 1998;68:844-6.
- Rattner DW, Fernandez-del Castillo C, Warshaw AL. Cystic pancreatic neoplasms. *Ann Oncol* 1999;10(Suppl 4):104S-106S.
- Dye CE, Waxman I. Endoscopic ultrasound. *Gastroenterol Clin North Am* 2002;31:863-79.
- Thatcher BS, Sivak MV Jr, George C. Endoscopic ultrasonography: a preliminary report. *Gastrointest Endosc* 1985;31:237-42.
- Endoscopic ultrasound—a marriage of inconvenience? *Lancet* 1987; 2:431-2.

20. Eisen GM, Chutkan R, Goldstein JL, et al. Role of endoscopic ultrasonography. *Gastrointest Endosc* 2000;52:852-9.
21. Lachter J, Zelikovsky S. EUS changes diagnosis from pancreatic to gallbladder carcinoma. *Int J Gastrointest Cancer* 2002;32:161-4.
22. Byrne MF, Mitchell RM, Baillie J. Pancreatic Pseudocysts. *Curr Treat Options Gastroenterol* 2002;5:331-8.
23. Martin EW Jr, Catalano P, Cooperman M, Hecht C, Carey LC. Surgical decision-making in the treatment of pancreatic pseudocysts. Internal versus external drainage. *Am J Surg* 1979;138:821-4.
24. Usatoff V, Brancatisano R, Williamson RC. Operative treatment of pseudocysts in patients with chronic pancreatitis. *Br J Surg* 2000;87:1494-9.
25. Vosoghi M, Sial S, Garrett B, et al. EUS-guided pancreatic pseudocyst drainage: review and experience at Harbor-UCLA Medical Center. *MedGenMed* 2002;4:2.
26. Gumaste UV, Dave PB. Pancreatic pseudocyst drainage—the needle or the scalpel? *J Clin Gastroenterol* 1991;13:500-5.
27. Ahmad NA, Kochman ML, Lewis JD, Ginsberg GG. Can EUS alone differentiate between malignant and benign cystic lesions of the pancreas? *Am J Gastroenterol* 2001;96:3295-300.
28. Sperti C, Cappellazzo F, Pasquali C, et al. Cystic neoplasms of the pancreas: problems in differential diagnosis. *Am Surg* 1993;59:740-5.
29. Sperti C, Pasquali C, Guolo P, et al. Evaluation of cyst fluid analysis in the diagnosis of pancreatic cysts. *Ital J Gastroenterol* 1995;27:479-83.
30. Sand JA, Hyoty MK, Mattila J, Dagorn JC, Nordback IH. Clinical assessment compared with cyst fluid analysis in the differential diagnosis of cystic lesions in the pancreas. *Surgery* 1996;119:275-80.
31. Hammel P, Voitot H, Vilgrain V, Levy P, Ruzsiewicz P, Bernades P. Diagnostic value of CA 72-4 and carcinoembryonic antigen determination in the fluid of pancreatic cystic lesions. *Eur J Gastroenterol Hepatol* 1998;10:345-8.
32. Centeno BA, Warshaw AL, Mayo-Smith W, Southern JF, Lewandrowski K. Cytologic diagnosis of pancreatic cystic lesions. A prospective study of 28 percutaneous aspirates. *Acta Cytol* 1997;41:972-80.
33. Fockens P. EUS in drainage of pancreatic pseudocysts. *Gastrointest Endosc* 2002;56(4 Suppl):93S-97S.
34. Le Borgne J, de Calan L, Partensky C. Cystadenomas and cystadenocarcinomas of the pancreas: a multiinstitutional retrospective study of 398 cases. French Surgical Association. *Ann Surg* 1999;230:152-61.
35. Brugge WR. The role of EUS in the diagnosis of cystic lesions of the pancreas. *Gastrointest Endosc* 2000;52(6 Suppl):18S-22S.
36. Bounds BC, Brugge WR. EUS diagnosis of cystic lesions of the pancreas. *Int J Gastrointest Cancer* 2001;30:27-31.
37. Le Borgne J. Cystic tumours of the pancreas. *Br J Surg* 1998;85:577-9.
38. Harewood GC, Wiersema MJ. Endosonography-guided fine needle aspiration biopsy in the evaluation of pancreatic masses. *Am J Gastroenterol* 2002;97:1386-91.
39. Sperti C, Pasquali C, Guolo P, Polverosi R, Liessi G, Pedrazzoli S. Serum tumor markers and cyst fluid analysis are useful for the diagnosis of pancreatic cystic tumors. *Cancer* 1996;78:237-43.
40. Sperti C, Pasquali C, Pedrazzoli S, Guolo P, Liessi G. Expression of mucin-like carcinoma-associated antigen in the cyst fluid differentiates mucinous from nonmucinous pancreatic cysts. *Am J Gastroenterol* 1997;92:672-5.
41. Alles AJ, Warshaw AL, Southern JF, Compton CC, Lewandrowski KB. Expression of CA 72-4 (TAG-72) in the fluid contents of pancreatic cysts. A new marker to distinguish malignant pancreatic cystic tumors from benign neoplasms and pseudocysts. *Ann Surg* 1994;219:131-4.
42. Binmoeller KF, Rathod VD. Difficult pancreatic mass FNA: tips for success. *Gastrointest Endosc* 2002;56(4 Suppl):86S-91S.