

AOO Chan 陳安安
IOL Ng 吳呂愛蓮
CM Lam 林志明
TWH Shek 石維雄
CL Lai 黎青龍

Cholestatic jaundice caused by sequential carbimazole and propylthiouracil treatment for thyrotoxicosis

連續施用卡比馬唑與丙硫氧嘧啶以治療甲狀腺毒症引致阻塞性黃疸

A 36-year-old Chinese man presented to the Queen Mary Hospital in August 1999 with a 2-week history of jaundice due to propylthiouracil treatment for thyrotoxicosis. He had previously received carbimazole but had developed an urticarial skin rash after 2 weeks of treatment. The patient developed liver failure and fulminant pneumonitis shortly after hospital admission. Despite receiving treatment with broad-spectrum antibiotics and intravenous immunoglobulin, he died 11 days after the onset of the respiratory symptoms. Postmortem examination using electron microscopy showed typical glycogen bodies within the cytoplasm of the hepatocytes, which corresponded to eosinophilic cytoplasmic inclusion bodies visible under light microscopy. Immunohistochemical studies of the inclusion bodies were positive for carcinoembryonic antigen and albumin, and negative for fibrinogen, complement protein C3, immunoglobulins G, M, and A, α -fetoprotein, and α -1-antitrypsin. This is the first report of a patient who received two sequential antithyroid drugs and developed predominate cholestasis with unique histological features. Extreme caution should be taken when a patient develops allergy to one type of antithyroid drug, because cross-reactivity may develop to the other type.

1999年8月，瑪麗醫院接收一名36歲華裔男性病人，他在入院前兩星期因接受丙硫氧嘧啶治療甲狀腺毒症而患上黃疸病。患者在此之前亦曾服用卡比馬唑，但用藥兩星期後出現蕁麻疹。患者入院後不久即出現肝功能衰竭及暴發型局竈性肺炎。雖然已經採用各種抗生素和經靜脈輸入免疫球蛋白，但患者在呼吸系統出現症狀11天後死亡。我們使用電子顯微鏡進行的解剖，發現肝細胞的細胞質含典型糖原，與在光學顯微鏡下清晰可見的嗜酸性細胞質包涵體吻合。就包涵體所作的免疫組織化學研究顯示，包涵體對癌胚抗原和清蛋白呈陽性反應，而對纖維蛋白原、補體蛋白C3、免疫球蛋白G、M和A， α 胎蛋白和 α -1胰蛋白則呈陰性反應。這是首宗因患者連續接受兩種抗甲狀腺藥物，引起明顯而具有獨特組織學特點的膽汁阻塞的病例。因此，當病人對一種抗甲狀腺藥物出現敏感時，醫生必須格外謹慎，因為交叉作用可能會使病人對另一種藥物產生敏感。

Key words:

Antithyroid agents;
Carbimazole;
Cholestasis;
Propylthiouracil

關鍵詞：

抗甲狀腺劑；
卡比馬唑；
膽汁阻塞；
丙硫氧嘧啶

Hong Kong Med J 2003;9:377-80

The University of Hong Kong, Queen Mary Hospital, Pokfulam Road, Hong Kong:

Department of Medicine

AOO Chan, MD, FHKAM (Medicine)

CL Lai, MD, FHKAM (Medicine)

Department of Pathology

IOL Ng, MD, FHKAM (Pathology)

TWH Shek, MB, BS, FHKAM (Pathology)

Department of Surgery

CM Lam, MS, FHKAM (Surgery)

Correspondence to: Dr AOO Chan
(e-mail: aoochan@hkusua.hku.hk)

Introduction

Cholestatic jaundice is a rare but potentially fatal complication arising from the use of the antithyroid drugs carbimazole and propylthiouracil. The underlying mechanism of pathogenesis is still unclear, and no known effective medical therapy has been found. We report on a man who developed cholestatic jaundice shortly after receiving sequential carbimazole and propylthiouracil treatment for thyrotoxicosis.

Case report

A 36-year-old Chinese man who had neglected symptoms of thyrotoxicosis for 1 year was treated by his family physician with carbimazole 10 mg three times

daily. An urticarial skin rash developed after 2 weeks of treatment, which was thus switched to propylthiouracil 100 mg three times daily. The patient developed jaundice 2 weeks later and was referred to the Queen Mary Hospital in August 1999.

The patient gave no history of hepatitis, alcohol, or drug abuse. Physical examination detected jaundice and multiple shotty cervical lymphadenopathy. The liver was enlarged to 3 cm below the costal margin, but it was soft and smooth. There was no skin rash or any sign of chronic liver disease.

The liver biochemistry tests showed an elevated serum concentrations of bilirubin 214 $\mu\text{mol/L}$ (reference range, 5-21 $\mu\text{mol/L}$), alkaline phosphatase 529 U/L (50-120 U/L), γ -glutamyltransferase 321 U/L (0-30 U/L), alanine aminotransferase 124 U/L (10-40 U/L), and aspartate aminotransferase 85 U/L (20-48 U/L). A low white blood cell count of $2.9 \times 10^9/\text{L}$ (reference range, $4.5\text{--}11.0 \times 10^9/\text{L}$) was noted on admission but the count quickly returned to normal 10 days later. There was no eosinophilia, and the clotting profile was normal. The level of free thyroxine was 51 pmol/L (reference range, 12-30 pmol/L) and the level of thyrotropin (thyroid-stimulating hormone) was less than 0.03 mIU/L (0.5-5.0 mIU/L). The tests for antibodies against hepatitis A, B, and C viruses all gave negative results. Furthermore, antibodies against cytomegalovirus, herpes simplex virus, and Epstein-Barr virus were also absent. The

anti-mitochondrial antibody and anti-smooth muscle antibody test results were negative as well.

An ultrasonography scan of the liver showed no stone in the gall bladder and common bile duct, although the intrahepatic ducts were prominent at the left lobe. Because cholangitis could not be excluded, an endoscopic retrograde cholangiopancreatography was performed, but the biliary tree was found to be normal. A percutaneous liver biopsy was thus performed.

The patient's liver biochemistry test results progressively worsened after admission. A course of oral prednisolone at 0.5 mg/kg was started with the presumptive diagnosis of drug-induced cholestasis. Subsequently, the serum alkaline phosphatase concentration decreased from 657 U/L to 194 U/L, but the bilirubin concentration continued to rise and peaked at 862 $\mu\text{mol/L}$ 12 days after starting therapy (Fig 1). The prothrombin time remained unchanged. Prednisolone administration was continued for 10 days and then gradually tapered off.

The patient developed a swinging fever 10 days after stopping steroid treatment and was asymptomatic, with no chest symptoms and no sputum production. Chest X-rays, ultrasonography of the liver, and echocardiography did not reveal an infective focus. However, the patient developed shortness of breath with greenish sputum 6 days later. The

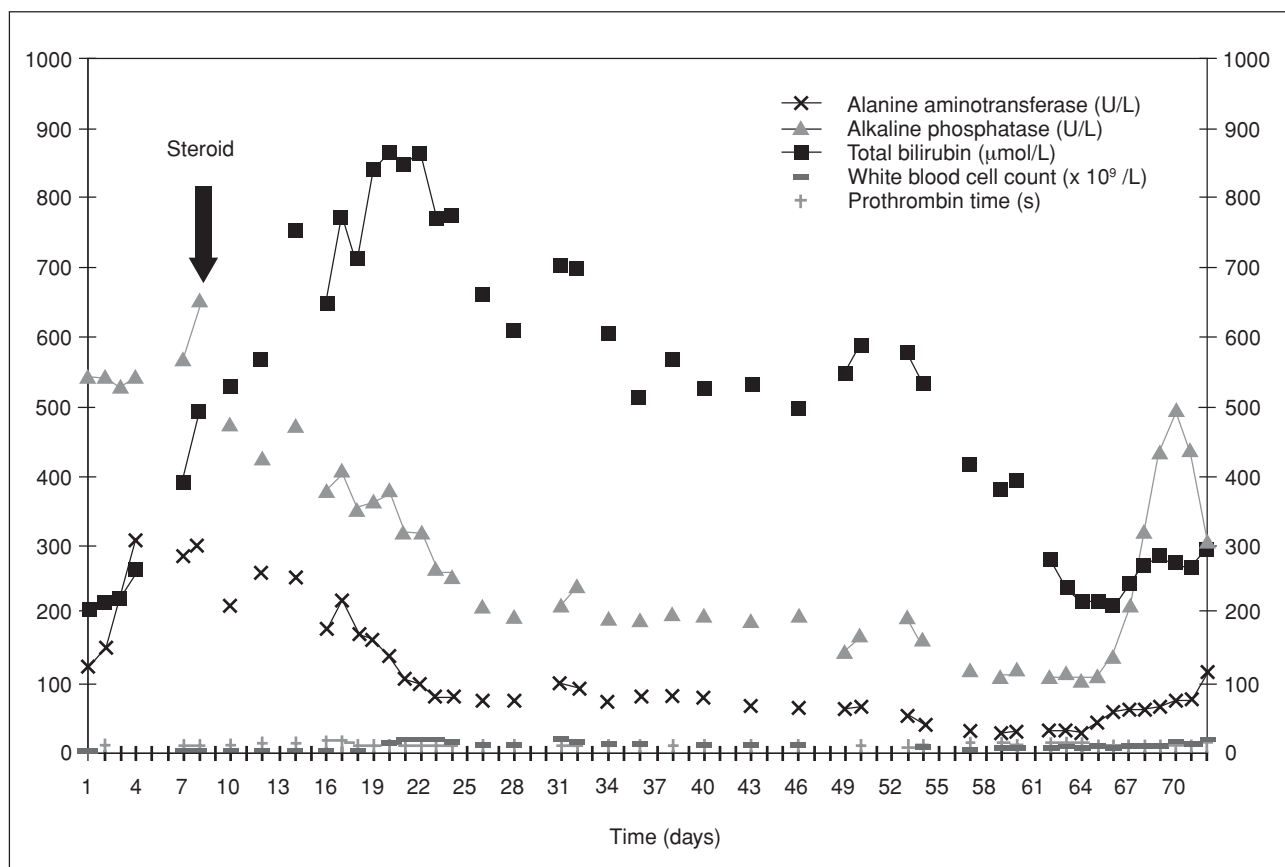


Fig 1. Time course of the change in liver biochemistry during steroid treatment

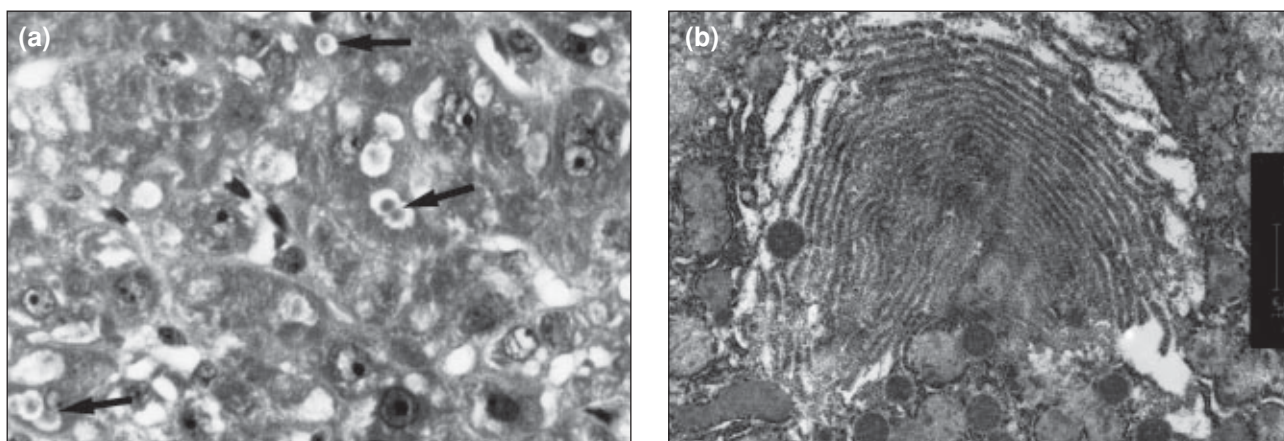


Fig 2. (a) Photomicrograph showing weakly eosinophilic cytoplasmic inclusion bodies (arrows) in the hepatocytes (H&E, x600); (b) electron micrograph showing glycogen bodies with semiconcentric or concentric arrays of smooth membranes associated with glycogen rosettes (x 13 350)

chest X-ray showed bilateral diffused haziness with ill-defined air-space shadows in both lungs, suggesting fulminant pneumonitis. Yet, repeated sputum, blood, and broncho-alveolar lavage were all negative for known organisms.

Results from an open lung biopsy revealed no granulomatous inflammation, and staining for acid-fast bacilli and fungi was negative. Immunostaining for herpes simplex virus and cytomegalovirus was also negative. The overall picture was compatible with acute lung injury, with diffused alveolar injury, acute interstitial pneumonia, or pneumonitis. Despite treatment with broad-spectrum antibiotics and intravenous immunoglobulin, the patient died 11 days after the onset of the respiratory symptoms.

The liver tissue showed preserved acinar architecture. There was prominent intracanalicular cholestasis in acinar zones 2 and 3. Inflammation was minimal and apoptotic bodies were not visible. Fatty change was absent. In addition, microscopy revealed numerous cytoplasmic, weakly eosinophilic inclusion bodies, which were variable in size, positive for periodic acid-Schiff, and sensitive to diastase digestion.

Immunohistochemical studies showed that the inclusion bodies were positive for carcinoembryonic antigen and albumin, and negative for fibrinogen, complement protein C3, immunoglobulins G, M, and A, α -fetoprotein, and α -1-antitrypsin. Immunostaining for herpes virus antigens HBsAg and HBcAg were negative. The portal tracts were mildly expanded by moderate lymphocytic infiltration with a small number of neutrophils but no eosinophils.

Electron microscopic examination of liver tissue revealed typical glycogen bodies within the cytoplasm of the hepatocytes, which corresponded to the eosinophilic cytoplasmic inclusion bodies that were visible under light microscopy (Fig 2a). The glycogen bodies had concentric arrays of smooth membranes associated with glycogen rosettes (Fig 2b).

Discussion

The patient in this case fulfilled the diagnostic criteria of drug-induced hepatotoxicity as proposed by Hanson in 1984¹: the absence of serological evidence of viral hepatitis infection, absence of chronic liver disease, and absence of drug or alcohol misuse with a temporal relation to drug therapy. The persistent ultrasound findings could be attributed to the marked cholestasis.

Antithyroid drugs have been reported to induce liver toxicity but usually in the form of acute hepatitis with elevation of parenchymal enzymes.^{1,2} The occurrence of acute cholestasis is rare, although it is associated more commonly with carbimazole than with propylthiouracil. Hepatotoxicity, mainly in the form of cholestasis, has been reported in six cases of carbimazole use³⁻⁷ and in one of propylthiouracil use.⁸ Only one study reported that cross-reactivity of the two drugs caused hepatotoxicity.⁷

Either carbimazole or propylthiouracil may have been the cause of the hepatotoxicity in the patient in this case. Cholestasis usually develops around several weeks after carbimazole use, but it may take only 1 day after propylthiouracil use.⁹ However, the possibility of crossover reactivity between the two drugs cannot be excluded. Cross-sensitivity has been reported to occur in about 50% of patients in one study.¹⁰ The levels of bilirubin and alkaline phosphatase in the patient in our case were twice as high as those reported. We thus suspect cross-reactivity of the two drugs occurred.

The successful use of steroid has been reported for fulminant hepatitis caused by antithyroid agents.^{11,12} The underlying mechanism of the hepatotoxicity may be immune-mediated, as evidenced by the observation that toxic symptoms occurred at an accelerated rate on rechallenge with antithyroid drugs.¹³ In addition, peripheral lymphocyte sensitisation to propylthiouracil has been demonstrated *in vitro*.^{14,15} However, the type of hepatic injury was hepatocellular in those steroid-responsive cases.

Table. Summary of histological findings in published adult cases of carbimazole- and propylthiouracil-induced cholestasis since 1980

Report	Age (years)/sex	Drug	Time to onset of cholestasis	Histological findings	Outcome
Dinsmore et al, ⁵ 1983	24/F	Carbimazole	3 months	Intracanalicular cholestasis, occasional bile thrombi, portal infiltration	Recovered
Blom et al, ⁴ 1985	81/F	Carbimazole	6 weeks	Intracanalicular cholestasis, piecemeal necrosis, portal infiltration	Recovered
Ayensa et al, ³ 1986	45/F	Carbimazole	10 days	Intracanalicular cholestasis, portal infiltration	Recovered
Ozenne et al, ⁶ 1989	70/F	Carbimazole	10 days	Cholestasis: centrilobular, normal portal tract	Recovered
This report, 1999	36/M	Carbimazole, propylthiouracil	4 weeks	Intracanalicular cholestasis, glycogen inclusion bodies, minimal inflammation	Died

The use of steroid has not been reported before in patients with cholestatic hepatotoxicity.

The type of liver injury in patients receiving propylthiouracil and carbimazole reported previously was usually hepatitis or mixed cholestatic hepatitis. Liver biopsy often revealed portal inflammatory changes and hepatocyte necrosis, with or without intracanalicular cholestasis. Cholestasis with minimal inflammation and absent apoptotic bodies has not been reported previously, and this is also the first reported case demonstrating numerous glycogen inclusion bodies in the liver biopsy specimen from a patient receiving antithyroidal drugs.

Glycogen inclusion bodies in drug-induced hepatotoxicity have been reported in patients taking anabolic steroids, trimethoprim or sulfamethoxazole, 6-mercaptopurine, methotrexate, nitrofurantoin, or vitamin A.¹⁶ Whether carbimazole or propylthiouracil is the cause of the increase in glycogen inclusion bodies cannot be ascertained. The reported features of liver biopsies in patients with hepatotoxicities because of carbimazole and propylthiouracil are summarised in the Table.

The cause of the lung injury in this patient could be ascertained. We postulate that it was due to superimposed opportunistic infection during steroid treatment, or due to a generalised immune-mediated reaction involving the liver, as well as the lung. Hence, extreme caution should be taken when a patient develops hepatotoxicity in response to one type of antithyroidal agent, because cross-reactivity may develop in response to a second type of antithyroidal drug. The use of steroid in this condition is still uncertain. Further studies are needed on the mechanisms of antithyroid drugs causing hepatotoxicity and on the use of steroid in these conditions.

References

1. Hanson JS. Propylthiouracil and hepatitis. Two cases and a review of the literature. *Arch Intern Med* 1984;144:994-6.
2. Liaw YF, Huang MJ, Fan KD, Li KL, Wu SS, Chen TJ. Hepatic injury during propylthiouracil therapy in patients with hyperthyroidism. A cohort study. *Ann Intern Med* 1993;118:424-8.
3. Ayensa C, Diaz de Otazu R, Cia JM. Carbimazole-induced cholestatic hepatitis. *Arch Intern Med* 1986;146:1455.
4. Blom H, Stolk J, Schreuder HB, von Blomberg-van der Flier M. A case of carbimazole-induced intrahepatic cholestasis. An immune-mediated reaction? *Arch Intern Med* 1985;145:1513-5.
5. Dinsmore WW, O'Hara MD, Callender ME. Postanaesthetic carbimazole jaundice. *N Engl J Med* 1983;309:438.
6. Ozenne G, Manchon ND, Doucet J, Hemet J, Schrub JC, Bercoff E. Carbimazole-induced acute cholestatic hepatitis. *J Clin Gastroenterol* 1989;11:95-7.
7. Sadoul JL, Canivet B, Freychet P. Toxic hepatitis induced by antithyroid drugs: four cases including one with cross-reactivity between carbimazole and benzylthiouracil. *Eur J Med* 1993;2:473-7.
8. Seidman DS, Livni E, Ilie B, Blum I. Propylthiouracil-induced cholestatic jaundice. *J Toxicol Clin Toxicol* 1986;24:353-60.
9. Lock DR, Stoege ZM. Severe hepatotoxicity on beginning propylthiouracil therapy. *J Clin Gastroenterol* 1997;24:267-9.
10. Jackson IM. Management of thyrotoxicosis. *J Maine Med Assoc* 1975;66:224-32,243.
11. Levy M. Propylthiouracil hepatotoxicity. A review and case presentation. *Clin Pediatr (Phila)* 1993;32:25-9.
12. Ichiki Y, Akahoshi M, Yamashita N, et al. Propylthiouracil-induced severe hepatitis: a case report and review of the literature. *J Gastroenterol* 1998;33:747-50.
13. Weiss M, Hassin D, Bank H. Propylthiouracil-induced hepatic damage. *Arch Intern Med* 1980;140:1184-5.
14. Mihas AA, Holley P, Koff RS, Hirschowitz BI. Fulminant hepatitis and lymphocyte sensitization due to propylthiouracil. *Gastroenterology* 1976;70:770-4.
15. Pacini F, Sridama V, Refetoff S. Multiple complications of propylthiouracil treatment: granulocytopenia, eosinophilia, skin reaction and hepatitis with lymphocyte sensitization. *J Endocrinol Invest* 1982;5:403-7.
16. Phillips MJ, Poucell S, Patterson J, Valencia P. Drug and toxic effects. In: *The liver. An atlas and text of ultrastructural pathology*. New York: Raven Press; 1987:159-72.