

Transient hypotension after high-speed head-on motor vehicle collision

高速汽車意外後短暫的血壓過低

.....
A 43-year-old woman was taken to the accident and emergency department after a high-speed motor vehicle collision. She had only minor external injuries, but developed an episode of hypotension, which rapidly responded to fluid infusion. Chest X-ray showed a widened superior mediastinum. Computed tomography confirmed thoracic aortic injury. In patients with high-speed deceleration injury, even transient hypotension should be taken seriously and a diligent search for the source of bleeding should be immediately undertaken.

一名43歲女士因高速汽車意外被送入急症室。病人只有輕微外傷，但出現血壓過低，經輸液後迅速回復正常。胸X光顯示病人上縱隔變寬，後經電腦斷層掃描證實胸大動脈受損。對於高速交通意外的傷者，儘管只有短暫的血壓過低，也應慎重處理，並應立即仔細搜索可能出血的位置。

Introduction

Despite medical and technical advances in the diagnosis and treatment of blunt thoracic aortic injuries (TAIs), the mortality rate after arrival at trauma centres remains high.^{1,2} A high proportion of deaths occur in the accident and emergency departments or before completion of surgery.³ Higher vigilance and expeditious management in accident and emergency departments are necessary if the outcome is to be improved.

Case report

A 43-year-old woman was taken to the Accident and Emergency Department at North District Hospital approximately half an hour after a motor vehicle collision. She was the front-seat passenger of a private car that collided head-on with a lamp-post at approximately 70 km per hour. She was fully conscious with Glasgow Coma Scale score of 15/15. Blood pressure was 150/75 mm Hg, pulse rate was 75 beats per minute, respiratory rate was 20 breaths per minute, and oxygen saturation (SpO₂) was 100% in 100% oxygen. She had injuries to the face and left forearm. There was no history of loss of consciousness. There was no abdominal pain. Only on direct questioning did she admit some chest discomfort on the left side. Lacerations to the left cheek and left upper eyelid and deformity of the left forearm and hand were the only external injuries detected.

In the resuscitation room, she developed an episode of transient hypotension with systolic blood pressure of approximately 85 mm Hg, which responded to rapid fluid infusion after approximately 10 minutes to 120 mm Hg. Electrocardiogram was normal. Focused abdominal sonography in trauma was normal. X-ray showed fractured shafts of the left radius and ulna and the base of the left first metacarpal, but the cervical spine and pelvic X-rays were normal. Chest X-ray showed suspicion of widened superior mediastinum and blurred aortic knob (Fig 1). Computed tomography (CT) of the thorax with contrast showed an intimal flap from the isthmus down the lower thoracic aorta, with mediastinal haematoma and some pleural fluid on the right side (Fig 2). The patient was transferred to a trauma centre where an aortic stent-graft was inserted and internal fixation of the fractures performed. The postoperative course was uneventful. She was discharged after 12 days.

Key words:

Accidents, traffic;
Aortic rupture;
Hypotension;
Thoracic injuries;
Wounds and injuries

關鍵詞：

交通意外；
大動脈破裂；
血壓過低；
胸部創傷；
創傷與傷口

Hong Kong Med J 2003;9:210-2

Accident and Emergency Department,
North District Hospital, 9 Po Kin Road,
Sheung Shui, Hong Kong
CH Chung, FHKAM (Emergency Medicine),
FHKAM (Surgery)

Correspondence to: Dr CH Chung

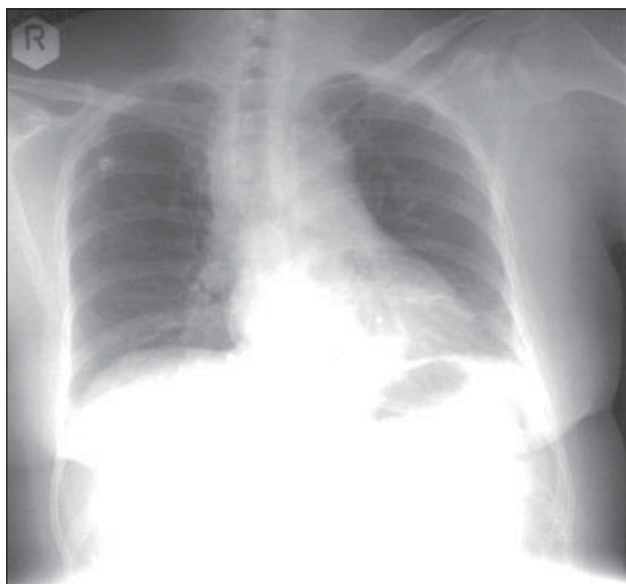


Fig 1. Erect chest X-ray showing suspicious widening of superior mediastinum (8.1 cm) and blurred aortic knob

Discussion

Thoracic aortic injury is a common cause of sudden death following rapid deceleration blunt thoracic trauma. More than 80% of cases are due to motor vehicle collisions.⁴ On the other hand, approximately 10% to 50% of all traffic fatalities are related to great vessel injury. Classically, 80% to 90% of these patients die immediately at the scene with complete aortic rupture.^{5,6} The remaining 10% to 20% of patients with partial aortic disruption have a high chance of survival if the aortic tear is quickly identified and treated. Since these patients are usually young and healthy, 71% to 84% will survive if diagnosis and surgical intervention are prompt.^{5,7} If the injury is not identified in patients who initially survive, 30% will die within the first 6 hours, 50% within 24 hours, and 90% within 4 months.^{4,5} Data indicated that with improved prehospital care, up to 50% of critical patients with TAI may reach the hospital alive.⁷

Despite the severe nature of the injury, the clinical signs of TAI are often occult and easily missed,⁵ or even absent.⁷ Since TAI is elusive but rapidly fatal, a high index of suspicion based on the mechanism of injury is the single most important factor for early diagnosis. The diagnosis of TAI should be considered for any patient sustaining a severe deceleration injury, especially in motor vehicle collisions at a speed in excess of 70 km per hour, or deformity of the steering wheel.⁵ One third to one half of patients may have no external evidence of chest injury, as in this patient.^{4,5} As a result, absence of external evidence of chest injury does not rule out the possibility of TAI. This patient only admitted some chest discomfort with direct questioning. Persistent or recurrent hypotension occurs more commonly in patients with TAI than in similarly traumatised patients without aortic rupture.⁸ In addition, 50% of patients with proven TAI have hypotension in the accident and emergency department.⁹

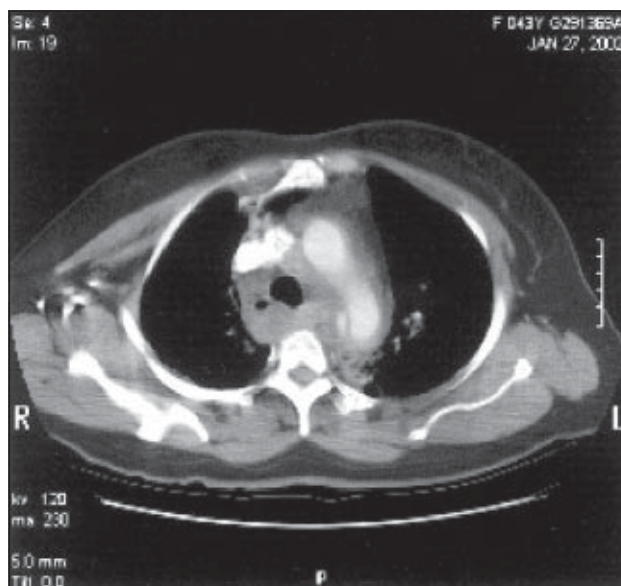


Fig 2. Computed tomography of the thorax showing intimal flap at aortic isthmus

Chest X-ray remains an excellent screening tool for determining the need for additional diagnostic studies. Widened superior mediastinum in the chest X-ray by frank visualisation or by measurement is the most sensitive sign (sensitivity, 92%), but the specificity is low (10%).^{5,7-9} Commonly cited guidelines for abnormal mediastinal widening include a mediastinal width at the level of the aortic arch greater than 6 cm in the erect posteroanterior film or greater than 8 cm in the supine anteroposterior chest film.^{5,8,9} Blurring or obscuration of the aortic knob or descending aorta is an accurate indication of aortic rupture.⁴ For patients after high-speed deceleration injury, the constellation of 'grossly widened mediastinum plus haemothorax plus transient hypotension' is regarded as highly specific for aortic injury and impending sudden death from free rupture—the 'triad of impending rupture'.¹ Hence, the significance of even transient hypotension for patients after high-speed deceleration injury should be taken seriously, and a diligent search for the source of bleeding should be immediately started.

Aortography has been the mainstay as the diagnostic modality of choice.⁵ The procedure allows precise anatomical localisation of the injury and provides information regarding vascular anomalies and other factors that influence operative strategy. The sensitivity is 83% to 97%, and specificity is up to 100%.^{10,11} Its role as the 'gold standard' for definitive diagnosis of blunt aortic injuries has been continually challenged, however. In addition to the minimal, but not negligible, risk, aortography is an invasive, time-consuming, manpower- and resource-intensive procedure. With more advanced technology providing faster and better resolution of images, helical CT with non-ionic contrast has been favourably compared with aortography for accuracy and availability.¹² Chest CT is non-invasive, rapid, and more informative for other thoracic injuries.⁵ Computed tomography depiction of a mediastinal haematoma as an indirect

sign of acute TAI has a sensitivity of 100%, a specificity of 87%, a positive predictive value of 21%, and a negative predictive value of 100%. Hence, the absence of mediastinal haematoma on CT eliminates the need for aortography.¹³

The role of transoesophageal echocardiography (TOE) in the diagnosis of traumatic aortic injury is controversial.^{7,10} As a semi-invasive procedure, TOE has been suggested by many authors to be the diagnostic procedure of choice to supplant aortography in the evaluation of TAI.^{4,5} Transoesophageal echocardiography does not require intravenous contrast, is portable, and can be rapidly performed at the bedside for unstable patients.⁵ Review of the literature reported sensitivities and specificities of 85% to 97% and 92% to 100%, respectively, for TOE.^{10,11} Even with the existing multidimensional reconstruction, TOE has imaging limitations. Also, the presence of atheromatous disease, pneumomediastinum, or pneumothorax can confound optimal imaging of a concomitant aortic injury.^{11,14} Transoesophageal echocardiography is not appropriate for patients with combative behaviour, severe coagulopathy, history of previous radiation therapy to the chest, unstable cervical spinal injury, oesophageal pathology, and severe facial trauma.^{7,11} With inherent blind spots and operator dependency, requiring both skill and experience, TOE is currently not a diagnostic modality that can supplant aortography in terms of accuracy and availability.^{7,11} At present, TOE can only be considered as having a complementary diagnostic role, especially in initial thoracic trauma screening and when aortographic findings are indeterminate.⁷ The superiority of TOE is related to its capability for concomitant evaluation of myocardial, valvular, or pericardial abnormalities.⁴ A diagnostic approach for suspected TAI has been proposed.¹⁴ Patients sustaining high-speed blunt torso injury should have a screening chest X-ray. If the chest X-ray is abnormal but the suspicion of aortic injury is low, helical CT scan should be performed. If the chest X-ray finding is consistent with aortic injury and clinical suspicion is high, either contrast-enhanced helical CT scan or aortography should be performed, depending on availability and institutional policy.

Finally, there should also be caution in fluid resuscitation of the hypotensive 'herald' episode, as aggressive

resuscitation is likely to precipitate aortic rupture.¹² Systolic blood pressure should be maintained between 100 and 120 mm Hg before operation.^{4,5} It has been shown that patients given short-acting β -blocking agents (esmolol or labetalol) to reduce aortic wall tension have lower in-hospital rupture.¹² If 'high' blood pressure is not adequately controlled with β -blockers, sodium nitroprusside can be added as a second agent.⁵

References

1. Simon BJ, Leslie C. Factors predicting early in-hospital death in blunt thoracic aortic injury. *J Trauma* 2001;51:906-11.
2. Attar S, Cardarelli MG, Downing SW, et al. Traumatic aortic rupture: recent outcome with regard to neurologic deficit. *Ann Thorac Surg* 1999;67:959-64.
3. Hunt JP, Baker CC, Lentz CW, et al. Thoracic aorta injuries: management and outcome of 144 patients. *J Trauma* 1996;40:547-56.
4. Bowling WM, Wilson RF, Gabor KD, Buchman TG. Thoracic trauma. In: Tintinalli JE, editor. *Emergency medicine: a comprehensive study guide*. 5th ed. New York: McGraw-Hill; 2000:1675-99.
5. Markovchick V, Wolfe R. Cardiovascular trauma. In: Rosen P, editor. *Emergency medicine: concepts and clinical practice*. 4th ed. St Louis: Mosby; 1998:527-45.
6. Wall MJ Jr, Hirshberg A, LeMaire SA, Holcomb J, Mattox K. Thoracic aortic and thoracic vascular injuries. *Surg Clin North Am* 2001;81:1375-93.
7. Ahrar K, Smith DC, Bansal RC, Razzouk A, Catalano RD. Angiography in blunt thoracic aortic injury. *J Trauma* 1997;42:665-9.
8. Kram HB, Wohlmuth DA, Appel PL, Shoemaker WC. Clinical and radiographic indications for aortography in blunt chest trauma. *J Vasc Surg* 1987;6:168-76.
9. Kram HB, Appel PL, Wohlmuth DA, Shoemaker WC. Diagnosis of traumatic thoracic aortic rupture: a 10-year retrospective analysis. *Ann Thorac Surg* 1989;47:282-6.
10. Goarin JP, Cluzel P, Gosgnach M, Lamine K, Coriat P, Riou B. Evaluation of transoesophageal echocardiography for diagnosis of traumatic aortic injury. *Anesthesiology* 2000;93:1373-7.
11. Ben-Menachem Y. Assessment of blunt aortic-brachiocephalic trauma: should angiography be supplanted by transoesophageal echocardiography? *J Trauma* 1997;42:969-72.
12. Fabian TC, Davis KA, Gavant ML, et al. Prospective study of blunt aortic injury: helical CT is diagnostic and antihypertensive therapy reduces rupture. *Ann Surg* 1998;227:666-77.
13. Kawada T, Mieda T, Abe H, et al. Surgical experience with traumatic rupture of the thoracic aorta. *J Cardiovasc Surg (Torino)* 1990;31:359-63.
14. Britt LD, Weireter LJ, Cole FJ. Newer diagnostic modalities for vascular injuries: the way we were, the way we are. *Surg Clin North Am* 2001;81:1263-79.