

RSM Wong 王紹明 ■

Severe acute respiratory syndrome in a doctor working at the Prince of Wales Hospital

威爾斯親王醫院一名醫生患上嚴重急性呼吸系統綜合症

Severe acute respiratory syndrome is a new disease that is highly contagious and is spreading in the local community and worldwide. This report is of a hospital medical officer with severe acute respiratory syndrome. He presented with sudden onset of fever, chills, myalgia, headache, and dizziness in early March 2003. He developed progressive respiratory symptoms and bilateral pulmonary infiltrates during the second week of his illness. Blood tests showed lymphopenia, mild thrombocytopenia, and prolonged activated partial thromboplastin time with normal d-dimer level. His chest condition gradually responded to ribavirin and corticosteroids, and serial chest X-ray showed resolving pulmonary infiltrates. The importance of early diagnosis lies in the potential for early treatment, leading to better response.

嚴重急性呼吸系統綜合症是一種新的疾病，傳染性相當高，並且正在本地和世界其他地方傳播。本文報告一名醫院醫生患上嚴重急性呼吸系統綜合症的病例。他在2003年3月初突然出現發燒、發冷、全身酸痛、頭痛和頭昏。呼吸系統的症狀在第二週持續出現，並發現兩邊肺出現浸潤物。驗血結果顯示患者的淋巴細胞及血小板減少，凝血激酶的活躍時間延長，而d-dimer水平正常。患者肺部的症狀逐漸對利巴韋林和皮質類固醇有反應，連續的X光照片亦顯示肺浸潤物逐漸消失。早期診斷此病使患者可以及早得到治療，從而取得更好的治療效果。

Introduction

Severe acute respiratory syndrome (SARS) is a new disease that is highly contagious and is spreading in the local community and worldwide.¹ It is important to recognise the clinical features so that early diagnosis can be made, as early treatment and infection control will result in improved response and reduce the spread of the disease. This report is of a medical officer who contracted SARS at the Prince of Wales Hospital. This report highlights the clinical features, findings, and progress of SARS.

Case report

A 32-year-old medical officer who worked at the Prince of Wales Hospital developed sudden onset of fever, chills, malaise, headache, dizziness, and myalgia in early March 2003. He had no rhinorrhoea, sore throat, cough, sputum production, or other symptoms. There was no history of recent travel. Physical examination showed a temperature of 38.9°C, clear lungs, and no obvious focus of infection. Nasopharyngeal aspiration for influenzae and throat swab for culture were obtained. Treatment with oseltamivir and levofloxacin was commenced. After further surveillance on day 3, he was found to have a persistent fever of up to 39°C with chills, rigor, malaise, and myalgia. He was admitted to hospital with 21 other doctors, nurses, medical students, and ward staff who had similar clinical features.

Vital signs at admission showed blood pressure of 120/70 mm Hg, pulse of 90 beats per minute, and arterial oxygen saturation of 100% on air. Physical examination was unremarkable. Chest X-ray initially showed clear lung fields.

Key words:

Pneumonia;

Ribavirin;

Severe acute respiratory syndrome

關鍵詞：

肺炎；

利巴韋林；

嚴重急性呼吸系統綜合症

Hong Kong Med J 2003;9:202-5

Department of Medicine and Therapeutics,
Prince of Wales Hospital, Shatin, Hong Kong
RSM Wong, MRCP, FHKAM (Medicine)

This article was published at
www.hkmj.org.hk on 17 April 2003.

Correspondence to: Dr RSM Wong

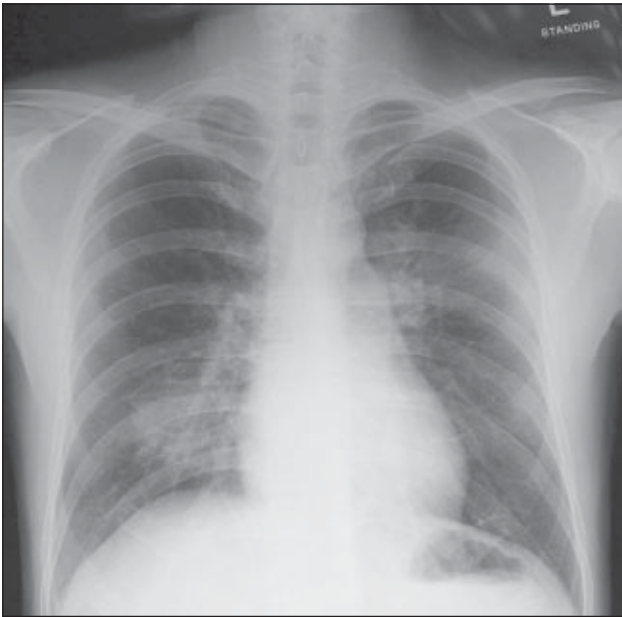


Fig 1. Chest X-ray performed on day 6 showed mild right lower lobe infiltrates

Nasopharyngeal aspirate and throat swab were negative for influenzae A and B, and respiratory syncytial viruses. Complete blood count showed a haemoglobin level of 150 g/L (reference range, 140-175 g/L), platelet count of $150 \times 10^9/L$ (reference range, $150-450 \times 10^9/L$), and white blood cell count of $6.2 \times 10^9/L$ (reference range, $4.5-11.0 \times 10^9/L$) with 53% neutrophils, 31% lymphocytes, and 16% monocytes. Plasma electrolytes, urea, creatinine, liver enzymes, and creatine phosphokinase were all within the reference range. Sepsis work-up, including sputum, urine, and blood cultures, showed no growth.

Immunofluorescence test for Legionella antigen and cold agglutinin were also negative. The patient continued to take oseltamivir and levofloxacin. On day 4, cefotaxime was added, in view of the persistent fever. Chest X-ray on day 6

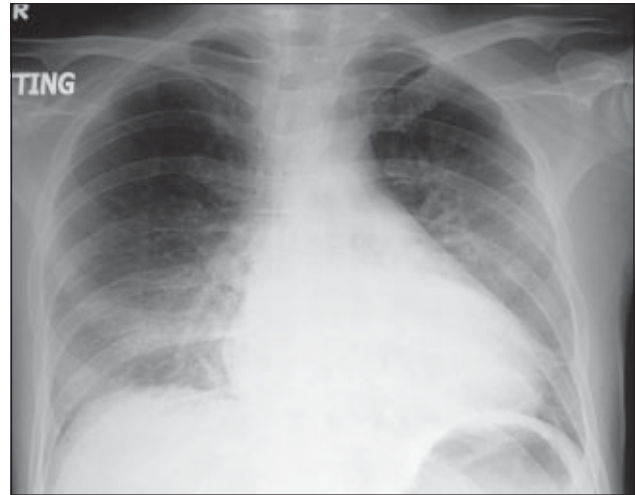
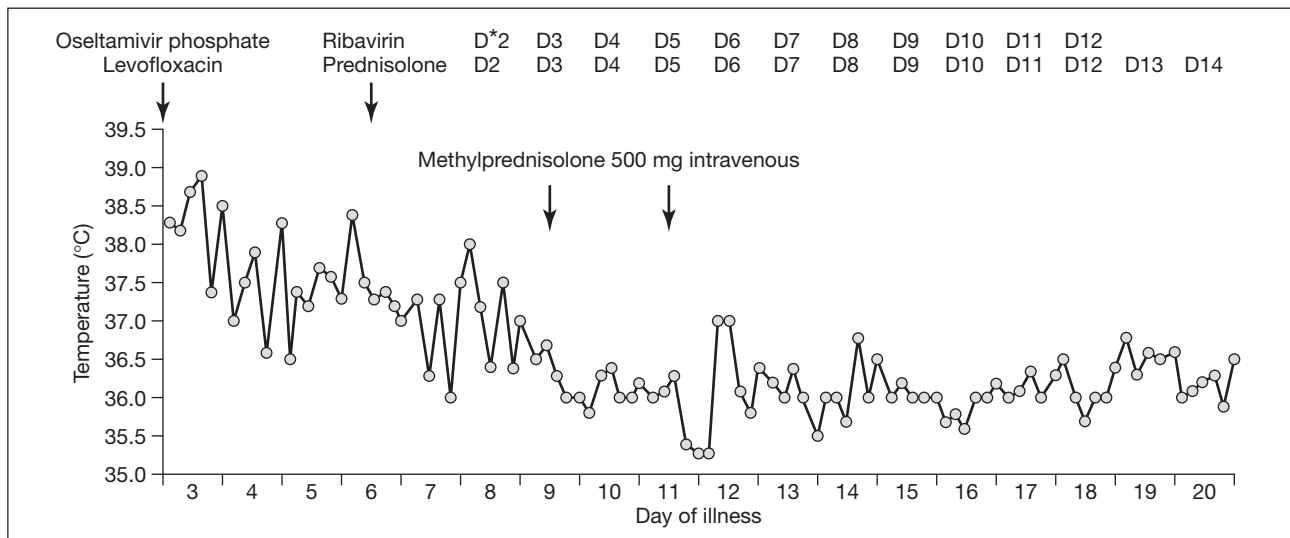


Fig 3. On day 11, chest X-ray (anteroposterior film) showed progression in right lower lobe consolidation and a new left middle zone infiltrate

showed mild right lower lobe infiltrates but the patient remained clinically stable with minimal chest symptoms (Fig 1). He also developed mild thrombocytopenia with a nadir of $106 \times 10^9/L$ and prolonged activated partial thromboplastin time (APTT) of 49.3 seconds (reference range, 24.8-38.0 seconds) on day 7. Prothrombin time and d-dimer remained normal. When laboratory investigations suggested a RNA viral aetiology, his treatment was changed to ribavirin 400 mg three times daily and prednisolone 0.5 mg/kg/day orally on day 7. The dose of ribavirin was subsequently increased to 1.2 g three times daily orally.

His fever responded to ribavirin and prednisolone (Fig 2) but he developed progressive dyspnoea with a dry cough and required oxygen supplementation to maintain his oxygen saturation from day 9. Serial chest X-ray performed in the second week of the illness showed progressive right lower lobe consolidation and a new left middle zone infiltrate (Fig 3). Complete blood count also showed



* D day

Fig 2. Temperature chart of patient showing treatment response to ribavirin and corticosteroids

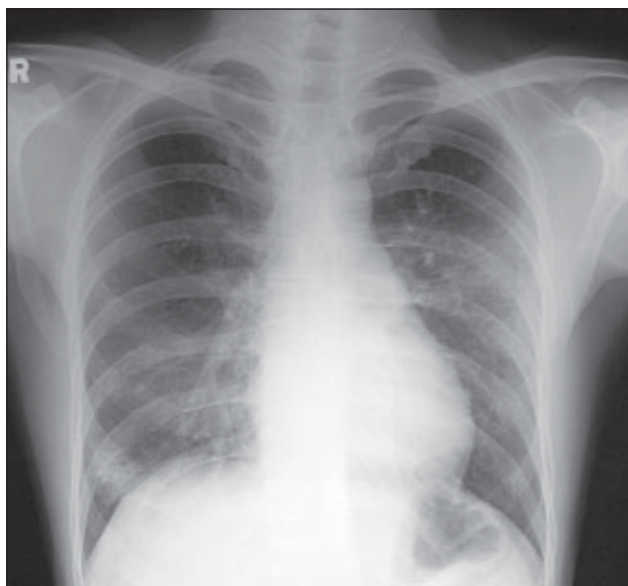


Fig 4. Chest X-ray on day 27 showed gradual resolution of bilateral lung infiltrates

progressive lymphopenia with 6% lymphocytes and a total white blood cell count of $7.8 \times 10^9/L$ on day 9. Two doses of intravenous pulse methylprednisolone 500 mg were given on days 9 and 11, and ribavirin was switched to 400 mg intravenously every 8 hours on day 11. Ciprofloxacin was also given. His condition gradually improved during the third week and serial chest X-ray showed gradual resolution of the bilateral consolidation. His chest symptoms also improved and he had normal oxygen saturation on room air. He completed a 12-day course of ribavirin and continued with a tapering schedule of steroid therapy. He was discharged on day 21 in stable condition. At follow-up on day 27, he had mild dyspnoea on exertion and his chest X-ray showed resolving bilateral pulmonary infiltration (Fig 4).

Discussion

This case illustrates the common clinical presentations and findings of SARS.²⁻⁵ Common clinical features include fever, malaise, chills, headache, myalgia, dizziness, and rigor. At the onset of illness, some patients have mild respiratory symptoms. Rash and neurological or gastrointestinal features are usually absent but some patients develop diarrhoea during the febrile prodrome. Other symptoms include muscular stiffness, loss of appetite, and confusion.

Patients often first present with severe headache, dizziness, and myalgia. Onset of fever is abrupt and the temperature is usually high, typically with chills and rigors. After 3 to 7 days, a lower respiratory phase begins, with the onset of a dry, non-productive cough or dyspnoea, which might be accompanied by or progress to hypoxaemia. In some instances, a patient may rapidly deteriorate with low oxygen saturation and acute respiratory distress requiring intubation and mechanical ventilation. The case-fatality rate

Case definitions of severe acute respiratory syndrome (as at 6 April 2003)

Suspected case

- (1) A person presenting after 1 November 2002 with a history of:
 - high fever ($>38^\circ C$); and
 - cough or breathing difficulty; and
 - one or more of the following exposures during the 10 days prior to onset of symptoms:
 - close contact* with a suspected or probable case of severe acute respiratory syndrome;
 - history of travel to an affected area[†];
 - residing in an affected area.
- (2) A person with an unexplained acute respiratory illness resulting in death after 1 November 2002, but on whom no autopsy has been performed, and one or more of the following exposures during the 10 days prior to onset of symptoms:
 - close contact with a suspect or probable case of severe acute respiratory syndrome;
 - history of travel to an affected area;
 - residing in an affected area.

Probable case

- (1) A suspected case with radiographic evidence of infiltrates consistent with pneumonia or respiratory distress syndrome on chest X-ray.
- (2) A suspected case with autopsy findings consistent with the pathology of respiratory distress syndrome without an identifiable cause.

Exclusion criteria

Severe acute respiratory syndrome should be excluded if an alternative diagnosis can fully explain the illness.

* Close contact is defined as having cared for, lived with, or had direct contact with respiratory secretions or body fluids of a suspected or probable case of severe acute respiratory syndrome

[†] Affected area is defined as an area in which local chain(s) of transmission of severe acute respiratory syndrome is/are occurring as reported by the national public health authorities

among persons with illness meeting the current WHO case definition of SARS is approximately 3% to 4%.⁶

The case definitions for global surveillance are subject to limitations because of the rapidly evolving nature of this illness. Case definitions are updated based on the current understanding of the clinical features of SARS and the available epidemiological data. The latest case definitions for surveillance of SARS can be found on the World Health Organization website.⁷ The case definition of SARS as at 6 April 2003 are shown in the Box.

Complete blood count may be usually normal initially. Lymphopenia is commonly observed early in the course of the illness, but thrombocytopenia is less frequently seen.²⁻⁴ Early in the respiratory phase, elevated creatine phosphokinase levels (as high as 3000 IU/L) and liver transaminases (two to six times the upper limits of normal) have been noted in some patients.²⁻⁴ Abnormal APTT is sometimes noted, while the prothrombin time is usually normal.²

Chest X-ray may be normal during the early phase and throughout the course of illness. A small unilateral patchy shadow may be seen at first, however, progressing to become bilateral, generalised, and interstitial/confluent infiltrates.^{2,3} This may be caused by the immune response targeting the lung. Patchy changes on the chest X-ray are sometimes seen in the absence of chest symptoms.

Conventional and high resolution computed tomography of the chest is useful if plain chest radiograph is negative. Acute respiratory distress syndrome may occur at the end stage.

Treatment with ribavirin and corticosteroid shows a favourable response in the majority of patients.² Treatment with plasma collected from patients in convalescence is also effective for some severe cases. The current evidence suggests that the mode of transmission is most consistent with droplet spread through respiratory secretions. The rapid spread of SARS in one ward at the Prince of Wales Hospital might be related to the use of a nebuliser by a patient with SARS.² Nebulisers should not be used by patients with symptoms compatible with SARS.

Conclusion

The new respiratory illness known as SARS has had a significant impact on the local community and worldwide. This case illustrates some common features and findings of SARS. This diagnosis should be considered for patients with

a high fever, respiratory symptoms, and a history of close contact with a person who has been diagnosed with SARS. Early diagnosis and treatment result in better response.

References

1. Update: Outbreak of severe acute respiratory syndrome—worldwide, 2003. *MMWR Morb Mortal Wkly Rep* 2003;52:241-6,248.
2. Lee N, Hui D, Wu A, et al. A major outbreak of severe acute respiratory syndrome in Hong Kong. *N Engl J Med* 2003. In press.
3. Preliminary clinical description of severe acute respiratory syndrome. *MMWR Morb Mortal Wkly Rep* 2003;52:255-6.
4. Poutanen SM, Low DE, Henry B, et al. Identification of severe acute respiratory syndrome in Canada. *N Eng J Med* 2003. In press.
5. Epidemiology, clinical presentation and laboratory investigation of severe acute respiratory syndrome (SARS) in Canada, March 2003. Health Canada website: <http://www.hc-sc.gc.ca/pphb-dgspssp/publicat/ccdr-rmtc/03vol29/prev/dr-sars0325.html>. Accessed 6 Apr 03.
6. Cumulative number of reported cases (SARS). From 1 Feb 2003 to 27 Mar 2003. World Health Organisation website http://www.who.int/csr/sarscountry/2003_03_27/en/. Accessed 6 Apr 03.
7. Case definitions for surveillance of severe acute respiratory syndrome (SARS). World Health Organization website: <http://www.who.int/csr/sars/casedefinition/en/>. Accessed 6 Apr 03.