

TL Poon 潘德立  
 WS Ho 何偉成  
 KY Pang 彭佳源  
 CK Wong 黃志強

# Tuberculous meningitis with spinal tuberculous arachnoiditis

## 帶有脊椎結核蛛網膜炎的結核腦膜炎

.....  
 This report is of a 36-year-old woman who initially presented with confusion and fever. Subsequent investigations showed tuberculous meningitis with acute hydrocephalus. Ventriculoperitoneal shunt was performed and anti-tuberculosis therapy was given. The patient was later noticed to have weakness of both lower limbs and urinary retention. Magnetic resonance imaging of the thoracic spine showed radiological features of tuberculous arachnoiditis with cord compression. Decompressive laminectomy was performed and high-dose systemic corticosteroid was given. A high level of awareness is required when diagnosing tuberculous arachnoiditis and the importance of high-dose corticosteroid in the treatment regimen is emphasised.

本文報告一位36歲女性，她起初呈現精神錯亂和發燒，後來證實她患有結核性腦膜炎，並有急性腦積水。我們為患者進行腦脊水引流手術和抗肺結核病的治療。患者後來呈現下肢無力及無法排尿的徵狀。胸椎骨的磁共振照相顯示有脊索壓縮的結核蛛網膜炎的放射特徵。我們於是進行減壓縮椎板切除手術和高劑量全身皮質甾類治療。醫生在診斷結核腦膜炎時，要提高警覺。此外，本文亦強調高劑量皮質甾類治療的重要性。

### Introduction

Central nervous system (CNS) tuberculosis represents approximately 10% of extra-pulmonary tuberculosis.<sup>1</sup> However, spinal tuberculous arachnoiditis is a rare complication of CNS tuberculosis that can result in severe peripheral neurological deficit. A patient with spinal tuberculous arachnoiditis secondary to tuberculous meningitis, despite receiving anti-tuberculosis therapy, is presented. This patient had gradual improvement in clinical status after decompressive laminectomy and a course of corticosteroid therapy.

### Case report

A 36-year-old woman presented with acute confusion and fever and was admitted to hospital. Physical examination revealed Glasgow Coma Scale of 12 points and there was evidence of meningism, including neck rigidity. No peripheral motor or sensory impairment and urinary and bowel retention suggesting spinal cord pathology were noted. The preliminary diagnosis was meningitis. Computed tomography scan of the brain showed communicating hydrocephalus (Fig 1). Lumbar puncture was performed with the opening pressure of 16 mm Hg. Cerebrospinal fluid (CSF) was sent for investigation with the following results: glucose level, 2.2 mmol/L (normal range, 2.8-4.4 mmol/L); protein level, >10 g/L (normal range, 0.15-1.45 g/L); white blood cell count, 20 per mm<sup>3</sup>; and lymphocyte count, 39%. Acid-fast bacillus was negative. There was no evidence of extra-neural tuberculous infection or immunosuppression. The results were suggestive of tuberculous meningitis. Ventriculoperitoneal shunt was performed. Anti-tuberculosis therapy was also started, including isoniazid, rifampicin, pyrazinamide, and ethambutol. The clinical condition of the patient improved. Cerebrospinal fluid culture yielded *Mycobacterium tuberculosis*.

The patient was noticed to have sudden onset of paraplegia and urinary retention after 6 days of treatment. No neurological deficit was revealed in the

#### Key words:

Arachnoiditis;  
 Decompression;  
 Laminectomy;  
 Steroids;  
 Tuberculosis, spinal

#### 關鍵詞：

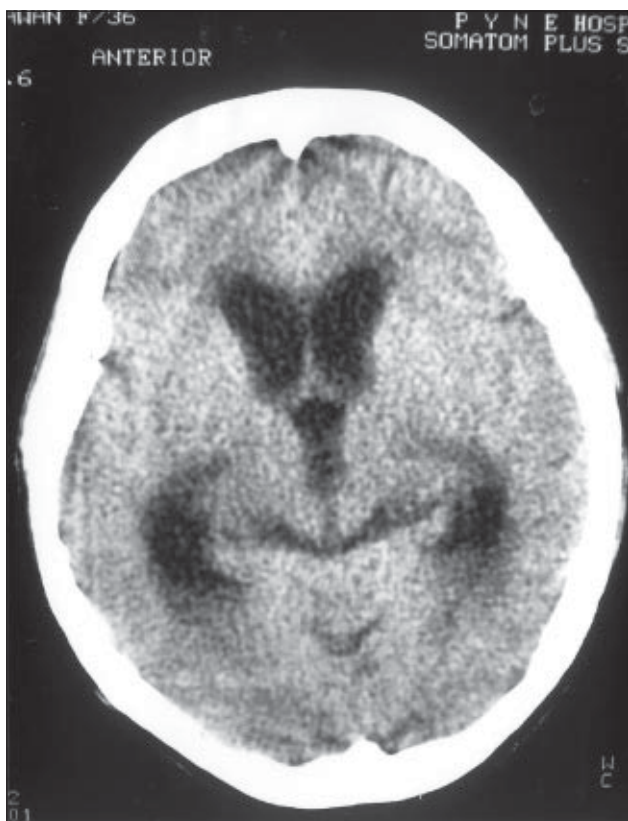
蛛網膜炎；  
 減壓；  
 椎板切除術；  
 類固醇；  
 肺結核，脊椎的

Hong Kong Med J 2003;9:59-61

Department of Neurosurgery, Pamela Youde Nethersole Eastern Hospital, 3 Lok Man Road, Chai Wan, Hong Kong

TL Poon, MRCS  
 WS Ho, FRCS (Edin), FHKAM (Surgery)  
 KY Pang, FRCS (Edin), FHKAM (Surgery)  
 CK Wong, FRCS (Edin), FHKAM (Surgery)

Correspondence to: Dr TL Poon



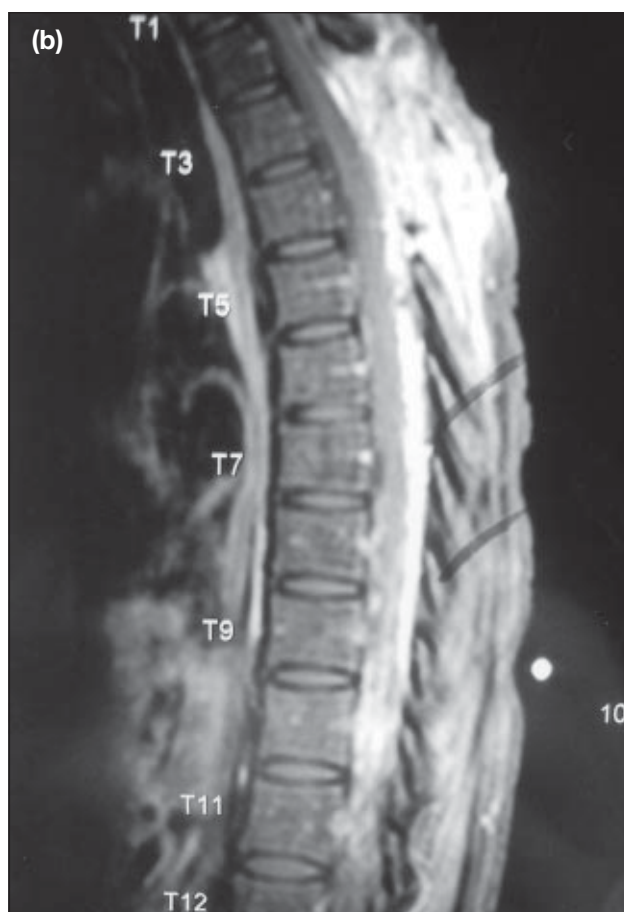
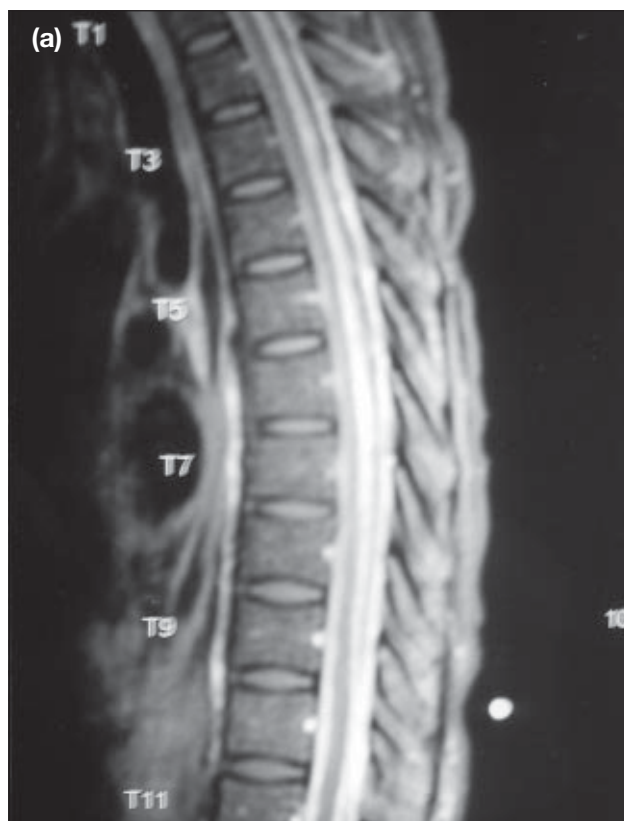**Fig 1. Computed tomography scan of the brain showing communicating hydrocephalus due to tuberculous meningitis**

upper limbs. Clinical features were compatible with spinal cord compression below the cervical level. Magnetic resonance imaging of the spine showed extensive subdural collection over the thoracic spine region with evidence of cord compression (Fig 2a).

Decompressive thoracic laminectomy at the level of T4 to T5 was performed. Intra-operatively, there was diffuse thickening of the arachnoid membrane with no definite localised collection. No further debridement was performed. High-dose corticosteroid (dexamethasone 16 mg/day) was added to the anti-tuberculosis therapy after operation. The patient had a gradual improvement in clinical status. Corticosteroid therapy continued for 4 weeks and was then gradually reduced. Magnetic resonance imaging of the thoracic spine approximately 4 months later showed marked improvement in radiological features (Fig 2b). The patient showed continuous clinical improvement and was able to walk with assistance and to micturate normally.

**Discussion**

Spinal tuberculous arachnoiditis is an inflammatory condition that involves the arachnoid lining along the spinal tract. This condition was previously termed adhesive spinal arachnoiditis or chronic adhesive arachnoiditis.<sup>1</sup> The literature shows that this clinical entity is uncommon in developed countries, but is still commonly reported in South-East Asia, the Indian subcontinent, South America, and Africa.<sup>2</sup>



**Fig 2. Magnetic resonance imaging of the thoracic spine: (a) before treatment showing extensive diffuse subdural collection; (b) 4 months after treatment showing marked reduction of subdural collection**

Three different pathogeneses are suggested for the occurrence of spinal tuberculous arachnoiditis:

- (1) a tuberculous lesion primarily arising in the spinal meninges;
- (2) downward extension of intracranial tuberculous meningitis; and
- (3) extension of tuberculous spondylitis.

Among these, involvement of the spinal arachnoid lining secondary to intracranial tuberculous meningitis is the most common pathogenesis. The thoracic region is the most frequently affected site, followed by the lumbar and cervical regions. Macroscopically, exudate can be seen surrounding the spinal cord and nerve roots. The exudate is particularly prominent posteriorly, probably due to lying in the supine position for a prolonged period. Microscopically, granulomatous inflammation, areas of caseation, tubercles, and fibrous tissue are noted. In chronic cases, the subarachnoid space may be irregularly obstructed, with the formation of pockets of CSF. Changes in arachnoiditis can be recognised as either a diffuse-adhesive form or a cystic form.<sup>2</sup> Accompanying the subdural exudate is vasculitis and direct pressure to the vascular system of the spine. Spinal cord parenchymal changes include border-zone rarefaction and vacuolisation of the cord, extensive atrophy and circumscribed central necrosis, severe gliosis with no recognisable parenchymal tissue, and intramedullary tuberculoma, which can result in multicystic myelomalacia and syringomyelia.<sup>3</sup> All of the above parenchymal changes were absent in the patient described here.

Spinal tuberculous arachnoiditis must be distinguished from other possible causes of arachnoiditis. With the advancement of antibiotic therapy, the incidence of cases with an infectious origin is decreasing. Numerous reports of arachnoiditis relating to spinal radiological procedures and surgery for spinal disorders indicate that iatrogenic causes are the most common.<sup>1,2</sup>

Treatment of spinal tuberculous arachnoiditis may be medical or surgical. Medical treatment remains the mainstay of treatment. Anti-tuberculosis therapy with a combination of drugs should be started once the diagnosis is established.<sup>4</sup> The entire course of therapy should continue for at least 9 to 12 months.<sup>3</sup> Drugs should be adjusted according to the sensitivity in case of resistant strains. Other medical treatments may also be given as adjuvant therapy. Previous studies have shown a promising outcome with

intrathecal hyaluronidase, an enzyme that hydrolyses the glucosaminidic bonds of hyaluronic acid and other mucopolysaccharides of the ground substance.<sup>5,6</sup> High-dose corticosteroid is another efficient adjuvant medical treatment, either given orally or, rarely, via the intrathecal route.<sup>7,8</sup> The patient described here started systemic corticosteroid after surgery and showed a gradual improvement in clinical status. This approach is supported by a French study.<sup>9</sup> The duration of therapy should be approximately 3 to 6 weeks. Surgery—decompressive laminectomy—should be considered if histological diagnosis is necessary or there is evidence of spinal cord compression with neurological deficit or spinal instability.<sup>10</sup>

## Conclusion

Spinal tuberculous arachnoiditis could result in serious and permanent neurological deficit if it is left untreated. A high index of suspicion is important for early diagnosis. Apart from appropriate anti-tuberculosis therapy, high-dose corticosteroid is recommended to achieve a favourable outcome.

## References

1. Guirish A Solanki. Spinal arachnoiditis. In: James D, editor. *Palmer manual of neurosurgery*. London: Churchill Livingstone; 1996:769-74.
2. Sridhar K, Ramamurthi B. Granulomatous fungal and parasitic infections of the spine. In: Menezes AH, Sonntag VK, editors. *Principles of spinal surgery*, Vol 2. New York: McGraw-Hill, Health Professions Division; 1996:1478-80.
3. Zuger A, Lowy FD. Tuberculosis. In: Scheld MW, Whitley RJ, Durack DT, editors. *Infections of the central nervous system*. Philadelphia: Lippincott-Raven; 1997:428-36.
4. Vidyasagar C, Murthy HK. Spinal tuberculosis with neurological deficits. *Natl Med J India* 1996;9:25-7.
5. Bhagwati SN, George K. Use of intrathecal hyaluronidase in the management of tuberculous meningitis with hydrocephalus. *Childs Nerv Syst* 1986;2:20-5.
6. Gourie-Devi M, Satishchandra P. Hyaluronidase as an adjuvant in the management of tuberculous spinal arachnoiditis. *J Neurol Sci* 1991; 102:105-11.
7. Freilich D, Swash M. Diagnosis and management of tuberculous paraplegia with special reference to tuberculous radiculomyelitis. *J Neurol Neurosurg Psychiatry* 1979;42:12-8.
8. Hernandez-Albujar S, Arribas JR, Royo A, Gonzalez-Garcia JJ, Pena JM, Vazquez JJ. Tuberculous radiculomyelitis complicating tuberculous meningitis: case report and review. *Clin Infect Dis* 2000;30:915-21.
9. de La Blanchardiere A, Stern JB, Molina JM, et al. Spinal tuberculous arachnoiditis [in French]. *Presse Med* 1996;25:1333-5.
10. Dastur HM. Diagnosis and neurosurgical treatment of tuberculous disease of the CNS. *Neurosurg Rev* 1983;6:111-7.