

KM Chow 周啟明
 CC Szeto 司徒卓俊
 JF Griffith 高士進
 TYH Wong 汪育華
 PKT Li 李錦滔

Unusual muscle pain in two patients with diabetic renal failure

兩名糖尿病腎衰竭患者的不尋常肌肉疼痛

.....
 We report on two patients with diabetic muscle infarct, a painful musculo-skeletal disorder complicating longstanding diabetes with established microangiopathy. Both patients had renal failure that was treated by dialysis. The underlying pathophysiological process was considered to be an arterial vascular event mediated through ischaemia-reperfusion injury. Clinicians should be alert to this condition. T2-weighted magnetic resonance imaging was valuable in establishing the diagnosis.

我們報告兩名患有糖尿病肌肉梗死的患者，此病由於長期患有糖尿病及微血管病而引起，患者會產生疼痛的肌肉骨骼紊亂。這兩名患者都曾接受透析治療腎衰竭。此病的潛在病理生理學過程相信是因為局部缺血及重新輸血引致受創，從而導致動脈管的問題。臨床醫生應對這種情況加以警惕。T2-加權重磁共振成像能在確診期間提供有價值的資料。

Introduction

Since the first recognition of the entity of diabetic muscle infarction almost 4 decades ago,¹ this condition has remained intriguing and poses diagnostic challenges.² This report presents two such cases, followed by discussion of the epidemiology, diagnosis, and proposed mechanism(s).

Case reports

Case 1

A 49-year-old female who was a non-smoker had type 2 diabetes mellitus diagnosed in 1985. Glycaemic control had been unsatisfactory despite insulin therapy. The condition was further complicated by proliferative retinopathy, peripheral neuropathy, and nephropathy. There were no overt macrovascular complications and coronary vessels were angiographically normal. The patient subsequently progressed to end-stage renal disease in 1998 and required continuous ambulatory peritoneal dialysis, which was then changed to haemodialysis when severe *Pseudomonas* species peritonitis occurred after 2 years.

In August 2000, the patient presented with spontaneous painful swelling in the left calf for 2 weeks. She could only just bear weight after taking analgesics and reported no symptoms of intermittent claudication. Tenderness was elicited on examination of the calf muscles. There was no skin erythema. Serial duplex ultrasound examination excluded deep vein thrombosis. The condition improved with symptomatic management and she was discharged after 1 week. The leg swelling regressed upon subsequent follow-up.

The patient then developed painful swelling of the left buttock in July 2001. Examination revealed a tender soft tissue mass over the lateral gluteal region without any associated skin lesion. She was afebrile. Her white cell count was $9.4 \times 10^9/L$ (normal range, $4.5-11.0 \times 10^9/L$) and erythrocyte sedimentation rate (ESR) was 116 mm/h (normal range, 0-20 mm/h). Radiograph of the pelvis was normal. Ultrasound examination showed subcutaneous oedema of the left gluteal muscles. No abscess or gas formation was evident. Magnetic resonance imaging (MRI) in both the coronal and axial planes confirmed enlarged left

Key words:

Infarction;
 Kidney failure;
 Magnetic resonance imaging;
 Muscle, skeletal;
 Reperfusion injury

關鍵詞：

梗死；
 腎衰竭；
 磁共振成像；
 肌肉、骨骼的；
 再次傷害

Hong Kong Med J 2002;8:368-71

The Chinese University of Hong Kong, Prince of Wales Hospital, Shatin, Hong Kong;
 Department of Medicine and Therapeutics
 KM Chow, MRCP
 CC Szeto, MRCP
 TYH Wong, MRCP
 PKT Li, FRCP, FACP
 Department of Diagnostic Radiology and Organ Imaging
 JF Griffith, FHKCR, FHKAM (Radiology)

Correspondence to: Dr CC Szeto

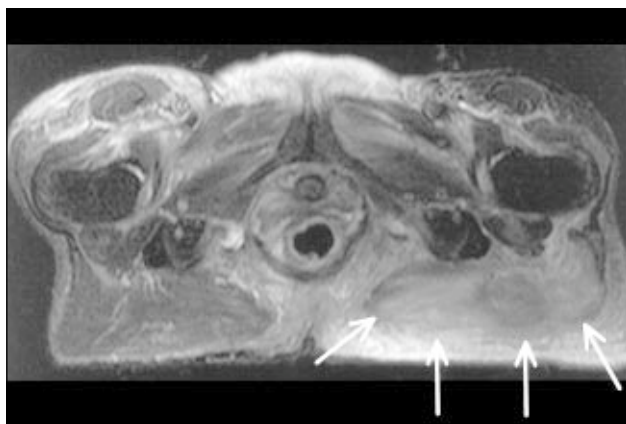


Fig 1. T2-weighted fat suppressed axial magnetic resonance imaging of the pelvis at the level of the pubic symphysis
There is diffuse oedema of the gluteal muscles on the left side (arrows) compared with the normal gluteal muscles on the right side. There is also oedema of the subcutaneous fat in the left gluteal region

gluteus with diffuse muscle hyperintensity on T2-weighted sequences (Fig 1). Repeated ultrasound examination demonstrated increasing oedema and hyperaemia of the left gluteus maximus muscle. Serial serum creatine kinase enzymes were normal. Surgical exploration of the left hip was undertaken, which showed abundant subcutaneous fluid and oedematous tissue. Culture from intra-operative wound swab was negative for microbiological studies. Biopsy showed non-specific inflammatory changes.

A diagnosis of diabetic muscle infarct was made. Symptomatic treatment was continued. The patient made a slow recovery and was able to walk out of the hospital with crutches after 2 months.

The patient presented again with a painful swollen right thigh 2 weeks later (Fig 2). She had changed the injection site for insulin and erythropoietin to the right thigh following surgery to the left buttock. There was no other trauma. There were no clinical features of compartment syndrome, and deep vein thrombosis was excluded by Doppler ultrasound. Erythrocyte sedimentation rate was 124 mm/h. Serial ultrasound imaging confirmed the same disease process

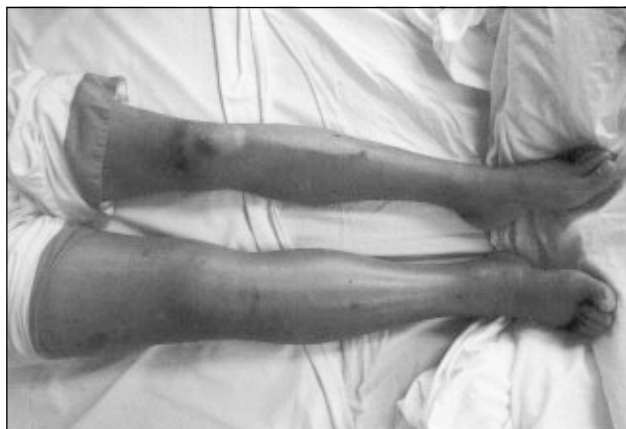

Fig 2. Clinical photograph showing recurrent diabetic muscle infarct involving the thigh muscles

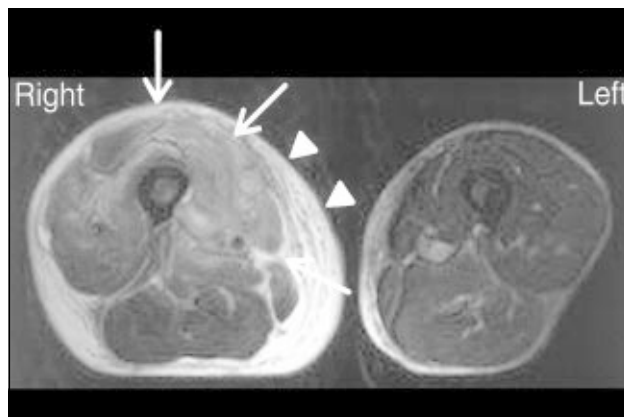


Fig 3. T2-weighted fat suppressed axial image of the mid-thigh showing similar findings to those in Fig 1
There is diffuse oedema of the anterior thigh muscles and in particular the musculus vastus medialis and intermedius (arrows). There is also overlying oedema of the subcutaneous fat (arrowheads)

affecting the right thigh as had previously affected the gluteal muscles. The entire vastus lateralis and rectus femoris were swollen and oedematous with reduced muscle vascularity, sparing the remainder of the thigh muscles. Subcutaneous tissue oedema was noted in the lateral thigh and calf.

In retrospect, this patient with longstanding diabetes mellitus and established microangiopathy receiving dialysis presented with three episodes of muscular infarction of the lower extremities within 2 years, involving a calf, buttock, and thigh.

Case 2

A 35-year-old male smoker had advanced diabetic retinopathy, hypertension, and two-vessel coronary disease requiring angioplasty. He progressed to end-stage renal disease 6 years after the diagnosis of type 2 diabetes mellitus, and underwent continuous ambulatory peritoneal dialysis.

The patient was admitted to hospital for a painful right anterior thigh swelling 2 years later. He could not recall any preceding trauma apart from injection of erythropoietin into the thighs. Serum creatine kinase was 556 U/L (normal range, 87-213 U/L). Serial duplex ultrasound, grey scale ultrasound, and MRI examination findings were similar to those of the first patient described in this report. There was pronounced swelling of the vastus intermedius and vastus medialis muscles, accompanied by a moderate increase in signal intensity on T2-weighted sequence signifying hyperaemia (Fig 3).

The overall scenario suggested a diagnosis of diabetic muscle infarct, which regressed during the following 2 weeks of treatment with bed rest and analgesics. There was no further relapse of the disease for this patient.

Discussion

For both patients, lower limb musculature involvement was manifested as an acute painful swelling in the presence

of longstanding diabetes mellitus and end-organ microvascular complications including end-stage renal disease.

According to the reported case series in the literature, patients with this condition present at a mean age of 40 years, after having had diabetic disease for an average of 15 years.^{3,4} A review of 56 published cases revealed that more than 80% had retinopathy and neuropathy, with an even wider prevalence of nephropathy (90%).³ Nearly one quarter of the patients were receiving renal replacement therapy, comprising either haemodialysis^{3,4} or peritoneal dialysis.⁵ There was no implication of an underlying infective process as indicated by a normal white cell count and microbiological studies, although the ESR exceeded 100 mm/h for more than two thirds of reported patients.³ Curiously, the muscle enzymes were typically normal or only marginally elevated for most patients.^{2-4,6} This is a useful discriminatory factor from immunologically related myositis, which is usually associated with marked elevation of muscle enzymes. Electrophysiological studies have been thought to be of value in supporting the diagnosis. Fibrillation potentials and positive sharp waves were most commonly reported.⁶

Diagnosis is based on clinical and MRI findings for the majority of patients, rather than histopathological evidence of muscle infarction.⁷ The MRI findings of our patients resembled the previously reported descriptions.^{8,9} Both patients showed diffuse enlargement of the involved muscle groups which appeared hyperintense on T2-weighted sequences compared with adjacent muscles (Figs 1 and 3). In a retrospective review of 21 patients with diabetic muscle infarct, areas of muscle infarction were universally seen as marked swelling isointense on T1-weighted images but hyperintense on T2-weighted, inversion-recovery, and gadolinium-enhanced images.⁸ The thigh muscles were involved in 81% to 87% of patients,⁸ with the musculi vastus (vastus intermedius, vastus medialis, or vastus lateralis) being most frequently affected.^{8,9}

Diabetic muscle infarct in the first patient described here was not recognised until a recurrent attack occurred 1 year after the first episode. Indeed, the available data suggest that diabetic muscle infarct remains underdiagnosed.^{7,8} With evolving knowledge and heightened awareness of this distinct diabetic complication, it is now recognised as a disease phenomenon that is self-limiting but with the possibility of recurrence. Recurrent lesions in the contralateral limb, as in the first patient, have been reported in 50% to 62% of patients.^{3,4}

Little data is available regarding the precise pathogenesis and precipitating events of this condition. There is accumulating epidemiological evidence that longstanding diabetic vasculopathy is a sine qua non for the development of diabetic muscle infarct. In the years after the first description by Angervall and Stener,¹ it was widely believed to be secondary to accelerated atherosclerosis and embolisation

of atheromatous plaque. Subsequent reports of radiological examination^{6,7} and postmortem findings¹⁰ demonstrated no evidence of ulcerative aortic or major occlusive vascular disease. Thrombosis and vasculitis could be involved in a minority of patients in view of reported associations with autoimmune disorder,⁴ hypercoagulopathy,¹¹ and even antiphospholipid antibodies.¹² Conclusive angiographic evidence is, however, lacking. Interestingly, for each episode of muscle infarction reported in the literature, including these cases, the involved area was localised to within the same fascial compartment of the leg.⁴⁻⁶ Taking into account the aforementioned MRI appearances, this would therefore argue for a contributory role of muscle oedema in diabetic muscle infarct.

More recently, attention has been focused on reperfusion injury,¹³ which could further jeopardise the ischaemic organs and thereby perpetuate further cellular necrosis. The available data suggest that the diabetic population is at risk of exaggerated leukocyte activation and pronounced leukocyte-endothelium cell adhesion response.¹³ Perhaps diabetic muscle infarct is secondary to a cascade of ischaemia-reperfusion events rather than a single thromboembolic episode. This is further supported by a recent case report of diabetic muscle infarct in which technetium-99m sestamibi scan confirmed the presence of hyperaemia at the site of injury.¹⁴

Although there is no direct evidence that insulin or erythropoietin injection were linked to the occurrence of diabetic muscle infarct in these two patients, both had had prior injections at the affected site. The preponderance of patients with type 1 diabetes mellitus also lends support to such a hypothesis. In fact, it has been demonstrated that insulin injection for glycaemic control predated the disease onset for 80% of patients.³ It is conceivable that patients tend to change the injection site to the opposite thigh after one episode of infarction, as with the first patient reported here. Such practice has been implicated in disease recurrence in the contralateral side. In addition, these two patients had been receiving human recombinant erythropoietin therapy. It appears that the vasoconstrictor effects mediated by endothelin production secondary to erythropoietin therapy¹⁵ may play a role in ischaemia-reperfusion injury.

Conclusion

There is a close relationship between diabetic muscle infarct and the presence of microvascular complications, impaired glycaemic control, and thrombogenicity. The disease is probably mediated via a propensity to ischaemic-reperfusion injury. Diabetic patients with these risk factors and unexplained acute painful swelling of the lower extremity muscle should therefore be investigated. Magnetic resonance imaging, in the appropriate clinical setting and characteristic background arteriopathy, can aid the diagnosis of this unusual musculoskeletal complication.

Acknowledgement

This work was supported in part by The Chinese University of Hong Kong research account 6901031.

References

1. Angervall L, Stener B. Tumoriform focal muscular degeneration in two diabetic patients. *Diabetologia* 1965;1:39-42.
2. Case records of the Massachusetts General Hospital. Weekly clinico-pathological exercises. Case 29-1997. A 54-year-old diabetic woman with pain and swelling of the leg. *N Engl J Med* 1997;337:839-45.
3. Madhan KK, Symmans P, Te Strake L, van Der Merwe W. Diabetic muscle infarction in patients on dialysis. *Am J Kidney Dis* 2000;35:1212-6.
4. Umpierrez GE, Stiles RG, Kleinbart J, Krendel DA, Watts NB. Diabetic muscle infarction. *Am J Med* 1996;101:245-50.
5. Bingham C, Hilton DA, Nicholls AJ. Diabetic muscle infarction: an unusual cause of leg swelling in a diabetic on continuous ambulatory peritoneal dialysis. *Nephrol Dial Transplant* 1998;13:2377-9.
6. Spengos K, Wohrle JC, Binder J, Schwartz A, Hennerici M. Bilateral diabetic infarction of the anterior tibial muscle. *Diabetes Care* 2000;23:699-701.
7. Keller DR, Erpelding M, Grist T. Diabetic muscular infarction. Preventing morbidity by avoiding excisional biopsy. *Arch Intern Med* 1997;157:1611.
8. Jelinek JS, Murphey MD, Aboulafia AJ, Dussault RG, Kaplan PA, Snearly WN. Muscle infarction in patients with diabetes mellitus: MR imaging findings. *Radiology* 1999;211:241-7.
9. Delaney-Sathy LO, Fessell DP, Jacobson JA, Hayes CW. Sonography of diabetic muscle infarction with MR imaging, CT, and pathologic correlation. *AJR Am J Roentgenol* 2000;174:165-9.
10. Chester CS, Banker BQ. Focal infarction of muscle in diabetics. *Diabetes Care* 1986;9:623-30.
11. Bjornskov EK, Carry MR, Katz FH, Lefkowitz J, Ringel SP. Diabetic muscle infarction: a new perspective on pathogenesis and management. *Neuromuscul Disord* 1995;5:39-45.
12. Palmer GW, Greco TP. Diabetic thigh muscle infarction in association with antiphospholipid antibodies. *Semin Arthritis Rheum* 2001;30:272-80.
13. Carden DL, Granger DN. Pathophysiology of ischaemia-reperfusion injury. *J Pathol* 2000;190:255-66.
14. Silberstein L, Britton KE, Marsh FP, Raftery MJ, D'Cruz D. An unexpected cause of muscle pain in diabetes. *Ann Rheum Dis* 2001;60:310-2.
15. Bode-Boger SM, Boger RH, Kuhn M, Radermacher J, Frolich JC. Recombinant human erythropoietin enhances vasoconstrictor tone via endothelin-1 and constrictor prostanoids. *Kidney Int* 1996;50:1255-61.

Department of Paediatrics, Kwong Wah Hospital

Presents

A Certificate Course on Paediatric Respiratory Medicine

Every Saturday afternoon, 4 January 2003 – 22 March 2003

(10 lectures followed by case studies/hands-on workshops)

Join us for a certificate course that will review the principles and practice of paediatric respiratory medicine and address the practical issues of skin prick test, spirometry, ambulatory sleep study, use of asthma medications and exercise tolerance assessment. Illustrative case studies will be presented in an interactive manner.

Course Director: Dr Daniel Ng, MBBS(HK), M Med Sc (HK), FHKAM(Paed), FHKCPaed, FRCP(Edin), FRCP(Glas), DCH(Ire), Dip Epidemiology and Biostatistics (CUHK)

Deadline of Registration : 10 December 2002

Location : Lecture Theatre, 10/F, New Wing, Kwong Wah Hospital

Course Fee : \$2,000

Information and registration : Annie Young
(Application form enclosed or available on request)
Tel : 2781 5055
Fax: 2781 5261
E-mail: dkkng@ha.org.hk

CME Accreditation :

Hong Kong College of Family Physicians : 1.5 points/session (max 10 pts)

Hong Kong College of Paediatricians : 2 points/session (max 18 pts)

Hong Kong Medical Council (CME points to be sought)

Hong Kong Doctors Union (CME points to be sought)

Hong Kong Academy of Medicine (CME points to be sought)

Department of Health (CME points to be sought)