

Corrosive oesophageal injury following vinegar ingestion

服用醋後引致食道的腐蝕性損傷

.....
 A 39-year-old woman drank one tablespoon of white vinegar in order to 'soften' crab shell stuck in her throat. Endoscopy revealed inflammation of the oropharynx and second-degree caustic injury of the oesophagus extending to the cardia. She had an uneventful recovery. This case report confirmed that vinegar could cause ulcerative injury to the oropharynx and oesophagus. The folklore application of vinegar 'dislodging' a foreign body in the throat should be strongly discouraged.

一位39歲女士為了溶化卡在喉嚨的蟹殼，服用了一湯匙白醋。內窺鏡檢查顯示口咽發炎，以及食道受到第二度腐蝕性傷害，延伸至賁門。該病人事後完全康復。這病例報告證實醋對口咽和食道可能造成潰瘍性傷害。使用醋來去除卡在喉嚨的異物的民間療法是不可取的。

Introduction

Hong Kong people enjoy eating seafood, and like to serve fish with the bone attached. As a result, fish bone lodged in the throat is a common occurrence. There are several Chinese folk remedies such as swallowing large rice boluses to dislodge the bone or drinking vinegar to 'soften' it. These measures are still believed and practised nowadays.

Case report

A 39-year-old woman experienced a foreign body sensation and pain in the left side of her throat after eating crab at dinner. She suspected a small piece of crab shell might be lodged in her throat. She drank one tablespoon of household rice vinegar (usually used for cooking) in the belief that it would dissolve the shell. The sensation of foreign body and pain persisted, however. The patient attended a general out-patient clinic the next day and was referred to the accident and emergency department. She enjoyed good health with no history of heartburn, regurgitation, dysphagia, odynophagia, epigastric distress, or gastrointestinal bleeding. There was no retching or vomiting before or after the foreign body sensation. Neither had she probed her throat or tried to induce vomiting. Vital signs were normal. She did not have a fever. Examination revealed scattered whitish patches on the posterior pharyngeal wall. No foreign body was identified. Lateral X-ray of the neck did not reveal any abnormality. She was discharged with an endoscopy appointment for the next morning. The endoscopic finding was inflammation of the oropharynx and second-degree caustic injury of the oesophagus from 22 to 30 cm (Fig 1) and the cardia (Fig 2). There was no evidence of a foreign body. The rest of the stomach and duodenum were normal. She was discharged with antacids. Since she was entirely symptom-free at the follow-up visit 1 week later, endoscopy was not repeated. At another follow-up visit 4 months later, she remained symptom-free.

Key words:

Acetic acid;
 Endoscopy;
 Esophagus;
 Foreign bodies

關鍵詞：

醋酸；
 內窺鏡檢查法；
 食道；
 異物

Hong Kong Med J 2002;8:365-6

Accident and Emergency Department,
 North District Hospital, 9 Po Kin Road,
 Sheung Shui, Hong Kong
 CH Chung, FHKAM (Emergency Medicine),
 FHKAM (Surgery)

Correspondence to: Dr CH Chung

Discussion

Derived from the French words *vin aigre* (sour wine), vinegar has been known from ancient times as a natural by-product of wine. Household vinegar is a sour-tasting liquid containing 4% to 5% acetic acid and is used as a condiment,

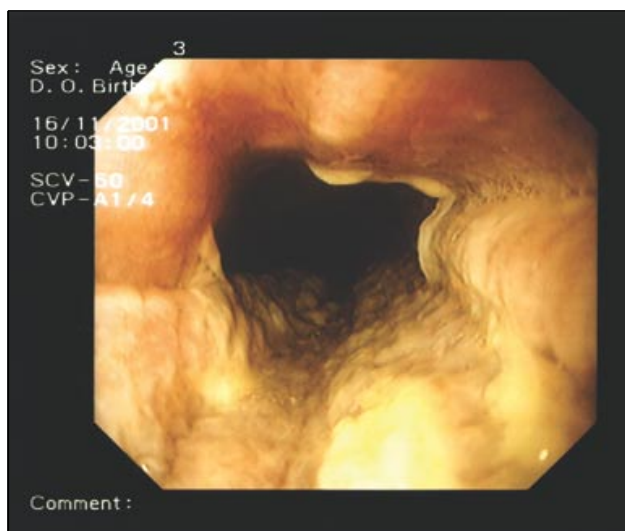


Fig 1. Tissue sloughing and white exudates in the middle of the oesophagus

salad dressing, preservative, mild disinfectant, medicinal tonic, and 'softener' or 'deodorant' in cooking. Vinegar can be made from almost any sugary liquid through two stages of fermentation.¹ In the first stage, the action of *Saccharomyces* yeast converts the sugar to alcohol. In the second stage, *Acetobacter* bacteria convert the alcohol to acetic acid.

The majority of caustic acid ingestions in adults are associated with suicide attempts, and usually involve strong acids.^{2,3} It is, however, the traditional Chinese folklore belief that vinegar can soften or dissolve fish bones or other foreign bodies stuck in the throat. Although this weak acid can cause corrosive and ulcerative injury to the upper digestive tract, it has rarely been reported in the medical literature.^{3,4} The most common sites of injury are at the natural anatomic narrowings in the oesophagus, namely, the cricopharyngeus, the aortic arch, and the cardia.² This was well illustrated in this patient. The stomach may also be involved.³ The clinical grading system for oesophageal caustic injuries is similar to that for skin burns. First-degree or superficial mucosal injury is associated with mild mucosal erythema and oedema. Second-degree or transmucosal injury involves severe erythema, white exudates, and ulceration. Third-degree or full thickness transmural injury is of a dusky or blackened appearance, with little remaining mucosa and possible obliteration of the lumen.^{2,5} Endoscopy is not only the tool of choice for diagnosis in such cases, but also aids in treatment and prognosis.⁶ The severity of the injury is best gauged by endoscopic findings and not by patient symptoms alone.^{2,7,8} The prognosis for weak acid injuries to the upper digestive tract is good since they are first-degree or, at worst, second-degree injuries.³ No treatment is necessary with first-degree injuries. Patients may be discharged if they can tolerate oral fluids.² The management of second- and third-degree corrosive injuries may include diet, parenteral nutrition, endoscopic, or surgical interventions. The role of corticosteroid and prophylactic antibiotic is controversial.^{2,8}

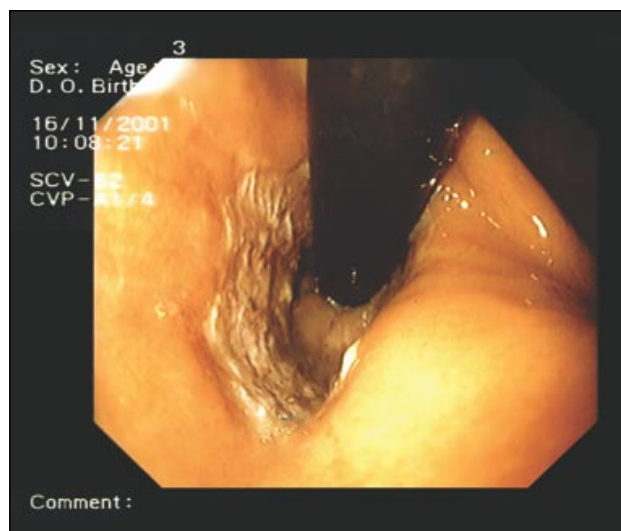


Fig 2. Retroflex view showing tissue sloughing and white exudates at the oesophago-gastric junction

Large amounts or more concentrated forms of acetic acid can cause serious systemic derangements in addition to local injuries such as disseminated intravascular coagulation, haemolysis, anaemia, and renal failure.^{9,10}

No foreign body has ever been discovered in reported cases of vinegar oesophageal injury,³ as in this case. This may be the result of the small number of reported cases of vinegar injuries or the possibility that most foreign bodies spontaneously pass without consequence. Further reports are necessary to clarify this issue.

Conclusion

This case report confirmed that vinegar could cause mucosal injury to the oropharynx and oesophagus. Its use in 'dislodging' a foreign body in the throat should be strongly discouraged.

References

1. Microsoft Encarta Online Encyclopedia 2000. Microsoft Encarta website: <http://encarta.msn.com>. Accessed 22 July 2002.
2. Spiegel JR, Sataloff RT. Caustic injuries of the esophagus. In: Castell DO, Richter JF, editors. *The esophagus*. 3rd ed. Philadelphia: Lippincott Williams & Wilkins; 1999;34:557-64.
3. Chen PC. Esophago-gastric mucosal injury following vinegar ingestion. *Chin J Gastroenterol* 1991;8:139-41.
4. Nuutinen M, Uhari M, Karvali T, Kouvalainen K. Consequences of caustic ingestions in children. *Acta Paediatr* 1994;83:1200-5.
5. Frank BA, Boyce HW. Caustic injury. In: Bayless TM, editor. *Current therapy in gastrointestinal and liver disease*. Vol 2. New York: BC Dekker; 1986:20.
6. Zargar SA, Kochlar R, Nagi B, Mehta S, Mehta SK. Ingestion of corrosive acids. Spectrum of injury to upper gastrointestinal tract and natural history. *Gastroenterology* 1989;97:702-7.
7. Cello JP, Fogel RP, Boland CR. Liquid caustic ingestion. Spectrum of injury. *Arch Intern Med* 1980;140:501-4.
8. Friedman EM, Lovejoy FH Jr. The emergency management of caustic ingestions. *Emerg Med Clin North Am* 1984;2:77-86.
9. Boseniuk S, Rieger C. Acute oral acetic acid poisoning—case report [in German]. *Anaesthesiol Reanim* 1994;19:80-2.
10. Greif F, Kaplan O. Acid ingestion: another cause of disseminated intravascular coagulopathy. *Crit Care Med* 1986;14:990-1.