

KH Mak 麥勤興 ■

# Distally based sural neurocutaneous flaps for ankle and heel ulcers

## 小腿遠側皮神經瓣片治療踝跟潰瘍

.....

**This study assessed the use of sural neurocutaneous flaps to repair chronic ulcers in difficult-to-cover areas around the ankle and heel. Follow-up of the 14 patients included in this study ranged from 6 months to 3 years after their operation. Total flap loss occurred in two patients, both of whom had rheumatoid arthritis complicated by vasculitis. Partial flap loss occurred in three patients; all were heel ulcers. Additional skin grafting procedures were required to cover their ulcers. A lateral malleolus ulcer in a patient with rheumatoid arthritis recurred after 1 year and had to be covered with a free parascapular flap. The sural neurocutaneous flap is thus a reliable means of resurfacing ulcers in the ankle and heel region. It requires no sacrifice of major peripheral vessels and may be a useful alternative for patients with poor peripheral pulses. Its use in the presence of vasculitis, however, needs further refinement.**

本研究評估使用小腿皮神經瓣片修補踝足跟周圍難於覆蓋表面的慢性潰瘍的方法，包括對14名患者的跟進，跟進期從手術後六個月到三年不等。其中兩名患者移植的瓣片全部損失，他們都患有類風濕性關節炎併發的血管炎。三名患者移植的瓣片有部份損失，他們都患有足跟潰瘍。這些病人需要另外的皮膚移植手術以覆蓋潰瘍的部份。一名患有類風濕性關節炎的病人在一年後側踝潰瘍復發，需要用肩胛骨附近的皮瓣植皮。由上述結果可見，小腿皮神經瓣片是一種踝跟區潰瘍面植皮的可靠方法。它無需損害重要的外圍脈管，且對外周脈搏弱的患者是有用的替代方法。然而，這種方法對血管炎患者的療效還有待改進。

### Key words:

*Achilles tendon;*  
*Foot ulcer/surgery;*  
*Leg ulcer/surgery;*  
*Sural nerve;*  
*Surgical flaps*

### 關鍵詞：

跟腱；  
足潰瘍／外科手術；  
腿潰瘍／外科手術；  
小腿肚的神經；  
外科手術瓣片

*HKMJ 2001;7:291-5*

Department of Orthopaedics and  
Traumatology, Kwong Wah Hospital, 25  
Waterloo Road, Kowloon, Hong Kong  
KH Mak, FRACS, FHKAM (Orthopaedics)

Correspondence to: Dr KH Mak

## Introduction

Soft tissue defects (ulcers) around the ankle and heel are usually found in areas with poor or marginal circulation. These defects are thus difficult to resurface because there is a lack of well-nourished soft tissue from which to take a skin graft. In addition, the recipient area demands that a durable soft tissue cover be used. Inappropriate treatment of these ulcers can lead to chronic inflammation, infection, and amputation.

Various procedures are available to repair soft tissue defects of the lower leg. The medial plantar neurovascular flap, for example, has been commonly used to repair weight-bearing areas, especially near the back of the heel. The abductor hallucis muscle flap with a pedicle from the posterior tibial artery has been used to cover ulcers on the dorsum of the foot or the malleolus, whereas the extensor digitorum muscle flap feeding onto the dorsalis pedis has been used to resurface ulcers on the lateral border of the foot. Free tissue transfer from procedures such as the groin flap, parascapular flap, and free myocutaneous flap are necessary when

there is a lack of local tissue available for transfer. These procedures are, however, often complicated in patients without peripheral pulses, and they require the sacrifice of a major source of blood supply to the foot. As these patients usually have arteriosclerosis and poor peripheral circulation, the need to preserve any perfusing vessel in the lower leg is paramount.

First described by Ponten in 1981,<sup>1</sup> the fasciocutaneous flap is very useful in the repair of soft tissue defects of the lower leg. The circulation is believed to depend on the suprafascial vascular network in the leg. The objective of this study was to assess the use of the sural neurocutaneous flap—a fasciocutaneous flap that is raised along the course of the sural nerve—to resurface chronic ulcers in difficult-to-cover areas of the ankle and heel.

### Subjects and methods

Between April 1997 and December 1999, 14 patients (6 men and 8 women) had their ankle and heel ulcers covered with distally pedicled sural neurocutaneous flaps. The patients aged from 23 to 92 years (mean, 66.3 years) [Table]. Five of the ulcers were located over the Achilles tendon. Three ulcers were located on the medial malleoli, two on the lateral malleoli, two on the lower shin, and one on the posterior heel. The ulcer on the posterior heel was around a discharging sinus of osteomyelitic fibula. Four of the patients had diabetes mellitus. In all but two patients, either the posterior tibial and/or dorsalis pedis pulses of the ankle were absent. The absence of peripheral pulses made the choice of a medial plantar neurocutaneous flap unsuitable.

The sural neurovascular flap is a fasciocutaneous flap that is raised along the course of the sural nerve.

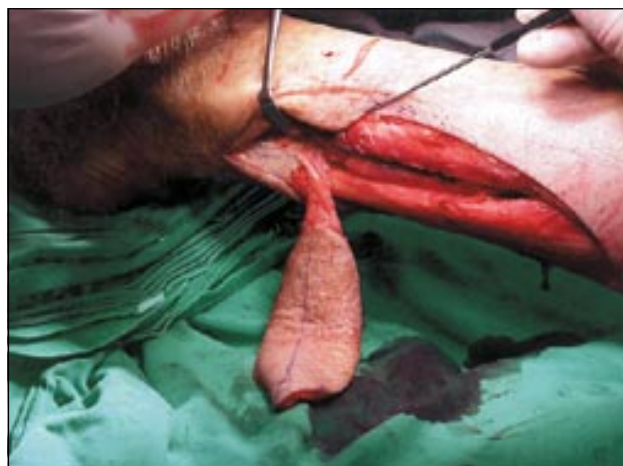


Fig 1. Sural neurocutaneous flap raised on its fascial pedicle and perforators from the peroneal vessels

The nerve emerges between the two heads of the gastrocnemius muscle in the middle of the popliteal fossa and travels to the lateral aspect of the heel between the lateral malleolus and the anterior margin of the Achilles tendon. Its blood supply depends on a constant sural artery that accompanies the nerve along its very proximal course. Distally, it depends on perforators coming from the peroneal artery. The most distal set of perforators leave the peroneal artery at about 5 cm above the lateral malleolus.

Briefly, the island flap was raised from proximal to distal after division of the sural nerve along its course (Fig 1). A 2-cm wide fascial pedicle was kept with the flap and dissected distally to the pivot point, which was about 5 cm above the lateral malleolus. Skin on both sides of the pedicle was dissected from the fascial pedicle, with care taken to include the sural nerve and the short saphenous vein. The viability of the flap was checked on release of the tourniquet before inseting. The island flap was then rotated to cover up the defect

Table. Characteristics of 14 patients with ankle and heel ulcers covered with sural neurocutaneous flaps

Patient	Sex	Age (years)	Location of ulcer	Ulcer size (cm x cm)	Palpable pedal pulse
1	M	67	Heel, TA* tendon	3 x 4	No
2	F	56	Heel, TA tendon	4 x 2	Dorsalis pedis only
3	M	60	Heel, TA tendon	4 x 4	No
4	F	69	Heel, TA tendon	4 x 2	No
5	F	23	Heel, TA tendon	5 x 5	Dorsalis pedis, posterior tibial
6	F	81	Lateral malleolus	6 x 7	No
7	F	68	Lateral malleolus	10 x 8	No
8	M	65	Medial malleolus	11 x 8	Dorsalis pedis, posterior tibial
9	M	41	Medial malleolus	8 x 8	Dorsalis pedis only
10	F	92	Medial malleolus	6 x 8	No
11	M	80	Plantar heel	6 x 4	No
12	F	76	Medial heel	4 x 4	No
13	F	90	Plantar heel, decubitus sore	4 x 4	No
14	M	61	Osteomyelitis, fibular involvement	5 x 3	No

\* Tendo-achilles

† Split-thickness skin graft

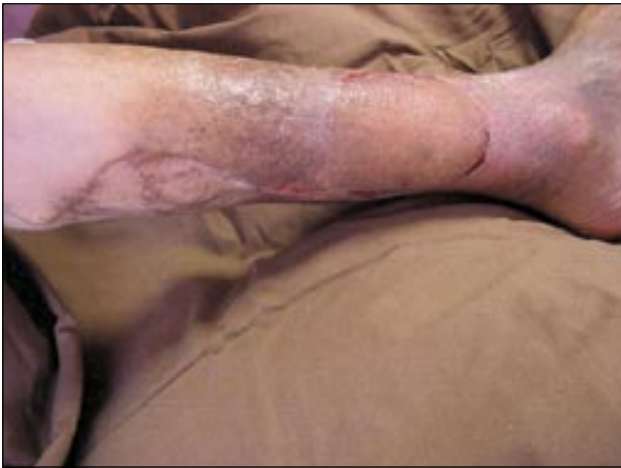

Fig 2. Sural neurovascular flap to repair a lateral malleolar ulcer

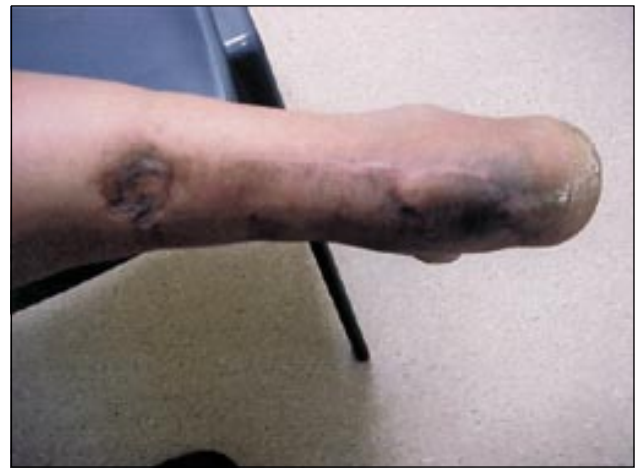

Fig 3. Sural neurovascular flap to repair an ulcer over the Achilles tendon

and a subcutaneous tunnel was created for the passage of the pedicle. Any twisting, kinking, or pressure on the pedicle was avoided during its transfer or tunnelling of the flap. The donor site was either closed primarily or covered with a split-thickness skin graft. The foot and ankle were then immobilised temporarily for approximately 2 weeks in a position that could relieve tension in the fascial pedicle, as well as pressure in the subcutaneous tunnel.

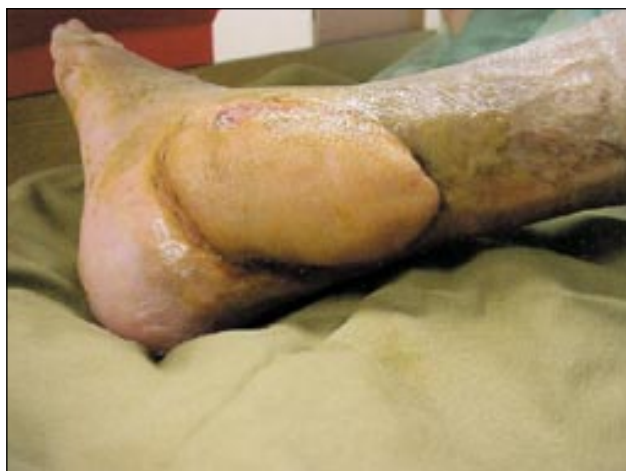### Results

Follow-up of the 14 patients in this study ranged from 6 months to 3 years after the operation. Nine of the fourteen flaps performed were successful, with good coverage of the ulcer obtained (Figs 2 and 3). There was no significant donor site morbidity. The largest flaps measured more than 10 cm x 8 cm in size and were in the malleolar region. There were three venous ulcers located on the medial malleoli and were associated with varicose veins and incompetent perforators.

All of these ulcers were covered successfully and without recurrence. Defects over the Achilles tendon tended to be smaller in size and excellent coverage was achieved, without affecting the integrity of the tendon. A total flap loss occurred in a 90-year-old woman. This patient had rheumatoid arthritis complicated by vasculitis. Coverage of her decubitus heel ulcer was attempted, but inflammation and oedema occurred in the surrounding skin and subcutaneous tissue, as well as around the subcutaneous tunnel made for the fascial pedicle, which possibly explained the failure of the procedure. She had a below-knee amputation due to the uncontrolled infection. Use of the flap to cover an infected and exposed Achilles tendon in a young woman also failed because of uncontrolled infection. The patient had been taking steroids for vasculitis. The exposed Achilles tendon was subsequently covered successfully with a pedicled medial plantar flap.

In addition to the above, three partial flap losses occurred, all in the heel region. The presence of

Previous surgery	Systemic illness	Complications
SSG <sup>†</sup> twice	Pulmonary tuberculosis; rheumatoid, vasculitis, infected, necrotic TA	Total loss, medial plantar flap
SSG twice SSG thrice	Rheumatoid, vasculitis Venous ulcer Venous ulcer	Partial loss, recurred in 1 year
	Rheumatoid, vasculitis	Partial loss Partial loss Total loss, below-knee amputation



**Fig 4. Lateral malleolus ulcer which recurred after a sural neurocutaneous flap, finally covered by a free parascapular flap**

wrinkles in the skin flap during the inseting may account for some of the partial losses. Partial loss defects were subsequently covered by direct suturing or with a split-thickness skin grafts.

One lateral malleolar defect recurred about 1 year after resurfacing. This was for a vasculitic ulcer on the lateral malleolus in a patient with rheumatoid arthritis. Split-thickness skin grafting failed repeatedly. A free parascapular flap was finally successful in covering the exposed lateral malleolus (Fig 4).

There were no complaints related to the sacrifice of the sural nerve. Paraesthesia on the lateral border of foot was not problematical and disappeared within 1 to 2 months.

## Discussion

This study assessed the use of distally pedicled sural neurocutaneous flaps to resurface chronic foot ulcers in difficult-to-cover areas, namely over the Achilles tendon, the lateral and medial malleoli, and the back of the heel. All but two of the 14 flaps performed survived, with both losses occurring in patients who had rheumatoid arthritis complicated by vasculitis (as commonly happens). Partial loss with shrinkage of the flap occurred in three patients with heel ulcers, and was usually due to technical considerations. Inevitable tension on and the length of the fascial pedicle are factors that can affect the viability of flaps used to resurface heel ulcers.

The sural neurocutaneous flap is a fasciocutaneous flap with the feeding vessel nourished by the perforators of the peroneal artery.<sup>1</sup> Masquelet et al<sup>2</sup> studied the vascular axis that follows the superficial sensory

nerves supplying the skin and identified a superficial sural artery that arises from the popliteal artery and accompanies the sural nerve in its course in the calf. He found that in 65% of patients, the artery descends to the ankle, whereas in the other 35%, it is reduced to an interlacing network in the distal third of the leg. Anastomoses with the peroneal artery are constant. Three to five septocutaneous vessels arise from the peroneal artery and anastomose with the vascular network of the nerve. There are also rich anastomoses located in the lower part of the tibiofibular space. These arterial arcades around the ankle nourish the fasciocutaneous tissue around the lateral malleolus and supply blood to the sural nerve and its neighbouring skin. Likewise, a vascular pedicle from a cutaneous branch of the perforating branch of the peroneal artery nourishes the lateral supramalleolar flap.<sup>3</sup> Owing to the presence of such anastomoses around the ankle joint, fasciocutaneous flaps that include perforators from the posterior tibial artery or the peroneal artery can be safely raised.

Hasegawa et al<sup>4</sup> were able to identify and follow the course of the superficial sural artery as described by Masquelet et al,<sup>3</sup> and reported successful treatment of 20 patients with distally based superficial sural artery flaps. Jeng and Wei<sup>5</sup> also confirmed that the vascular supply of the distally based sural island flap comes from the cutaneous perforating branches of the peroneal artery. These investigators raised four adipofascial flaps and 12 fasciocutaneous flaps to resurface defects in the ankle and in the non-weight-bearing area of the heel.

Oberlin et al<sup>6</sup> recommend using a fasciocutaneous flap based on the satellite vascular networks found accompanying the sural (or any fine cutaneous) nerve, rather than a defined artery. They emphasise the need to include in the flap the local subfascial fat that contains branches from the peroneal artery, and to have the flap raised with all the deep fat along the lateral margin of the Achilles tendon up to its point of insertion. This type of flap is very reliable, even in patients with distal arterial insufficiency, and thus is the flap of choice for the treatment of heel necrosis.

Ulcers in the ankle and heel area are usually a consequence of poor peripheral circulation. The success of the procedure, however, does not depend on the presence of peripheral pulses. In this study, for example, a 23-year-old patient with rheumatoid arthritis and a vasculitic ulcer in the lower heel had intact and good peripheral pulses, yet the procedure failed. By contrast, most of the successful procedures

were in older patients who had absence of either the posterior tibial and/or dorsalis pedis pulses of the ankle. Thus, the sural neurocutaneous flap healed all ulcers around the Achilles tendon insertions and the lateral malleoli, irrespective of the presence of palpable peripheral pulses. It appears that the circulation to these extremities might have been through the perforators, thus bypassing the major peripheral vessels. The patency of perforators in peripheral vascular disease is clearly essential for the success of sural neurocutaneous and other neurocutaneous flaps. Vasculitis per se causes the ulcer or is a complication of the ulcer and affects the circulation in the perforators, and hence the success of the procedure.

Neurocutaneous flaps other than the sural nerve flap have been described. These use the saphenous nerve, the superficial peroneal nerve,<sup>2</sup> and the cutaneous branches of the radial and ulnar nerves.<sup>7</sup> They too will surely evolve as important sources of soft tissue for the resurfacing of local skin defects without the need to sacrifice any major vessels.

## Conclusions

The distally based sural neurocutaneous flap with fascial pedicle, including the perforators of the peroneal artery around the ankle region, is a reliable source of soft tissue to cover defects in the ankle and heel, without the sacrifice of a major blood vessel. This procedure involves a single operation without the need for microsurgical anastomosis. Its success does not

depend on the presence of a good peripheral pulse and may prove useful for patients who have peripheral vascular insufficiency. The morbidity associated with the loss of the sural nerve is minimal. A long pedicle can be designed to allow the flap to be transferred as far as the instep area. For defects in the weight-bearing area of the sole or heel, however, the medial plantar neurocutaneous flap gives more durable and sensate skin cover. For larger defects in the ankle or foot, or to fill up a defect due to osteomyelitis, free tissue transfer such as the myocutaneous flap should be considered, as this brings in a new source of circulation.

## References

1. Ponten B. The fasciocutaneous flap: its use in soft tissue defects of the lower leg. *Br J Plast Surg* 1981;34:215-20.
2. Masquelet AC, Romana MC, Wolf G. Skin island flaps supplied by the vascular axis of the sensitive superficial nerves: anatomic study and clinical experience in the leg. *Plast Reconstr Surg* 1992;89:1115-21.
3. Masquelet AC, Beveridge J, Romana C, Gerber C. The lateral supramalleolar flap. *Plast Reconstr Surg* 1988;81:74-81.
4. Hasegawa M, Torii S, Katoh H, Esaki S. The distally based superficial sural artery flap. *Plast Reconstr Surg* 1994;93:1012-20.
5. Jeng SF, Wei FC. Distally based sural island flap for foot and ankle reconstruction. *Plast Reconstr Surg* 1997;99:744-50.
6. Oberlin C, Azoulay B, Bhatia A. The posterolateral malleolar flap of the ankle: a distally based sural neurocutaneous flap - a report of 14 cases. *Plast Reconstr Surg* 1995;96:400-5.
7. Bertelli JA, Khoury Z. Neurocutaneous island flaps in the hand: anatomical basis and preliminary results. *Br J Plast Surg* 1992;45:586-90.