

DKK Ng 吳國強
AKW Law 羅健華
SWW Cherk 卓蘊樺
KL Mak 麥江寧

First fatal case of enterovirus 71 infection in Hong Kong

香港首宗感染腸道病毒71而引致死亡的病例

Enteroviruses are a common cause of childhood infections, from hand, foot and mouth disease, to lethal brainstem encephalitis. Enterovirus 71 was first isolated in 1969. Brainstem encephalomyelitis and pulmonary oedema are postulated to be causally related and have been found to be a common feature of fatal enterovirus 71 cases. A fatal case of enterovirus 71 infection in a 2-year-old, previously healthy boy is reported. He presented to the Department of Paediatrics with clinical features of sepsis within 3 days of onset of fever. A few minutes after injection of midazolam, fentanyl and vecuronium for intubation, cardiac arrest developed and was not amenable to various treatment modalities. Pulmonary haemorrhage and oedema were noted during intubation, and postmortem examination confirmed the presence of brainstem encephalomyelitis.

腸道病毒是兒童傳染病一個常見的病因，它的病例從輕微的手、足、口病到致命的腦幹發炎。1969年首次辨認出腸道病毒71。致命的腸道病毒71案例的常見徵狀包括腦幹腦脊髓炎和肺水腫，這兩種病態曾被假設為有因果關係。本文報告了一名兩歲男童，其病歷紀錄顯示他過往是健康的。這名男童感染了腸道病毒71。他連續發燒三天，且有膿毒症的臨床徵狀。於是被送往兒科就診。利用靜脈注射把 midazolam，fentanyl 及 vecuronium 注入男童體內後幾分鐘，他的心臟開始停止跳動，利用各種治療的方法皆無效。在氣道插管期間，病人出現肺出血及肺水腫，屍體解剖證實病人患上腦幹腦脊髓炎。

Key words:

Child;

Disease outbreaks;

Enterovirus infections, epidemiology;

Hand, foot and mouth disease

關鍵詞：

兒童；

疾病爆發；

腸道病毒傳染，流行病學；

手、足、口病

HKMJ 2001;7:193-6

Kwong Wah Hospital, Waterloo Road, Hong Kong;

Department of Paediatrics

DKK Ng, M Med Sc, FRCP (Edin)

AKW Law, MRCP, FHKAM (Paediatrics)

SWW Cherk, MRCP, FHKAM (Paediatrics)

Department of Pathology

KL Mak, MB, BS, FHKAM (Pathology)

Correspondence to: Dr DKK Ng

Introduction

Enteroviruses cause a wide spectrum of diseases, however, most infections are asymptomatic. Enterovirus 71 (EV71) was first isolated in 1969.¹ An outbreak of EV71 was subsequently reported in Hong Kong in 1987.² In general, EV71 causes trivial illnesses but it has been known to spread to the central nervous system giving rise to encephalitis,³ and aseptic meningitis or occasionally paralysis.⁴

Pulmonary haemorrhage or oedema has been a common feature of fatal EV71 cases reported,^{5,6} and an aetiological link between brainstem encephalomyelitis and pulmonary oedema has been suggested.⁵ An epidemic of EV71 infection affecting thousands of Taiwanese children, was reported in 1999.⁶

This paper presents the case of a two-year-old Hong Kong Chinese boy, who died of brainstem encephalomyelitis and pulmonary haemorrhage due to enterovirus infection. The child's death was the first reported fatality from EV71 infection in Hong Kong.

Case report

A two-year-old boy was admitted to the Department of Paediatrics in May 1999, due to a fever of 2-day duration. Previous medical history revealed that the boy was born after a full-term pregnancy. His immunisations were up-to-date and there was no history of travel. At that time, eight children were reported to have hand, foot and mouth disease (HFMD) in the nursery where he attended.

The child became unwell 3 days before admission. He developed fever, nasal discharge, and a skin rash. On the first day of fever, he was seen by a private medical practitioner who prescribed amoxycillin, paracetamol, phenergan, a cough mixture, and an antiemetic. Fever persisted and the child was evaluated at the emergency department of another hospital the following day. He was noted to have mouth ulcers, and was discharged with a diagnosis of viral infection. The following day, he attended another private medical practitioner because of persistent high fever, anorexia, and decreased playfulness. A diagnosis of sepsis was made and he was referred to Kwong Wah Hospital.

On arrival at the emergency room, he was described as dull in appearance, with tachypnoea (respiratory rate 68 breaths per minute), and tachycardia (200 beats per minute). His pulse oximetry reading was 90% in room air, improving to 95% with a 24% oxygen supplement through a Venturi mask (Baxter Health Care, Valencia, USA). He was diagnosed with septic shock and admitted.

On arrival in the general paediatric ward, the child was drowsy but responsive to verbal commands. His temperature was 38.7°C. Central and peripheral cyanosis were noted but no skin rash was seen. Respiratory rate was 86 breaths per minute with subcostal insucking; his chest was clear on auscultation. Heart rate was 200 beats per minute and blood pressure was 80/60 mm Hg. His extremities were cold, with a capillary refill time of 4 to 5 seconds. Abdominal examination was unremarkable. Oxygen saturation was 80% in room air. An electrocardiogram showed sinus tachycardia. A chest radiograph showed haziness of the right lower zone and the heart size was normal. A provisional diagnosis of septic shock was made. Oxygen supplementation was given with 50% oxygen via Venturi mask, and a bolus of normal saline (20 mL/kg) was given over 20 minutes. He was transferred to the Paediatric Intensive Care Unit (PICU) for further management.

In the PICU, increasing drowsiness was noted. Respiratory rate was 86 breaths per minute and pulse oximetry was 74%, despite 50% oxygen supplementation via Venturi face mask. Heart rate was 202 beats per minute and blood pressure was 113/75 mm Hg. Peripheral circulation remained compromised. The boy vomited undigested food and blood-stained fluid. He was intubated with an endotracheal tube, after injection of midazolam, fentanyl, and vecuronium. Copious amounts of blood-stained fluid subsequently gushed from the endotracheal tube. Intravenous fluid resuscitation was continued. Bradycardia, with a heart rate reducing to 53 beats per minute, developed immediately after intubation. Blood pressure could not be recorded. External cardiac massage was started immediately, and intravenous adrenaline was injected. The response was transient, with heart rate increasing to 140 beats per minute but oxygen saturation remaining at 40%. Profound bradycardia recurred shortly afterwards and no pulse wave was detected by pulse oximeter. External cardiac massage and mechanical ventilation was continued. Multiple doses of intravenous adrenaline and sodium bicarbonate were administered. The response was unsatisfactory and there was no return of spontaneous effective circulation. Continuous adrenaline and isoprenaline were provided by intravenous infusion. The echocardiogram revealed very poor cardiac contractility. Transcutaneous pacing and subsequently, transvenous pacing were attempted but there was no ventricular capture. After 9 hours of active resuscitation, the child was certified dead.

Laboratory results showed a peripheral total white blood cell count of $26.7 \times 10^9/L$ (normal range, $6.0-16.0 \times 10^9/L$). Blood for antibody titres was sent and results were as follows. Complement fixation tests were performed for influenza A and B, chlamydia, mycoplasma pneumoniae, herpes simplex, and enteroviruses. Micro-neutralisation tests were performed for coxsackie B viruses B1, B2, B3, B4, B5, and B6. All antibody levels were less than 1:10. A reverse transcription polymerase chain reaction test (RT-PCR) based on primer specific for EV71, was used to detect virus RNA directly in brain tissue and gave a positive reaction for RNA extracts from the brain. This RT-PCR does not cross-amplify viral RNA from polio, coxsackie A (including coxsackie A16), coxsackie B, or selected echoviruses (JSM Peiris and WC Yam, personal communication). Enterovirus 71 was also isolated from the brain and stool by culture on vero cells and confirmed by immunofluorescence, using EV71 specific monoclonal antibodies (Chemicon, Temecula, California, USA.).

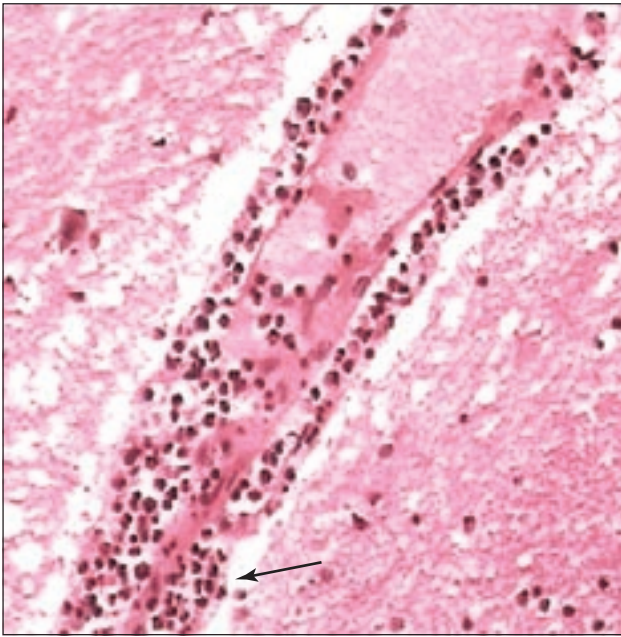


Fig. Perivascular cuffing (see arrow) by polymorphs and mononuclear cells, and oedema in the Virchow-Robin space (H&E x100)

An autopsy revealed encephalomyelitis. The medulla, pons, and cerebellum showed prominent mononuclear cells with perivascular cuffs, microglial nodules with neuronophagia, and necrosis involving mostly grey but also white matter (Fig). Mononuclear cells were seen in adjacent meninges, whereas no viral inclusion was seen. The basal ganglia was also involved focally. Histological examination was normal for other internal organs.

An elder sister of the boy was subsequently admitted to hospital in the following week, with suspected HFMD. She had fever, multiple mouth ulcers over the buccal mucosa and soft palate, a scattered papular rash, and a few vesicular eruptions over the trunk, buttocks, and limbs. Clinical recovery was complete and without complication. Throat swab culture of this child also yielded EV71.

Discussion

It is not uncommon for EV71 to invade the central nervous system. Fatal infection has been reported in Malaysia in 1997,^{5,7} and Taiwan in 1998.⁶ Brainstem encephalitis, non-cardiogenic pulmonary oedema, or both has been identified in some patients who died in these outbreaks. Most patients had clinical features suggestive of HFMD or herpangina. According to the experience in Taiwan, 90% of patients with central nervous system involvement had brainstem encephalitis.⁶ This resulted in widespread damage of the vasomotor and respiratory centres located in the brainstem. Rapid neurogenic pulmonary oedema and vasomotor

collapse apparently led to the outcome seen in these children.⁷

In the patient presented, the clinical course closely resembled that described in the Taiwanese patients. Brainstem encephalomyelitis was the cause of his rapidly deteriorating clinical course. This child was apparently healthy and was not immunocompromised. A remarkable feature was the rapid cardiovascular decompensation seen, which was resistant to all advanced life support measures. Cardiac arrest occurred 3 minutes after injection of midazolam, fentanyl, vecuronium, and the insertion of an endotracheal tube.

There is the possibility that brainstem encephalitis predisposes the vasomotor and respiratory centres to the cardiac and respiratory depressant effects of sedative agents, especially fentanyl and midazolam.⁸ Once the sympathetic drive is blocked by these drugs in a patient with shock, there would be a precipitous collapse in cardiovascular function. As the cardiovascular system is decompensated, administration of inotropes or other resuscitation medications may not be able to restore cardiac output and vasomotor tone. Consequently, when a clinical situation suggestive of enterovirus septicemic shock is encountered, one should be extremely cautious with the use of cardiac depressive agents like midazolam and fentanyl for intubation purposes. The authors suggest that awake bronchoscopic intubation, with judicious use of local anaesthetics, may be a safer alternative. Nonetheless, the patient outcome may not differ, as evidenced by the reported high mortality associated with brainstem involvement in such cases. This case also further supports the view that brainstem encephalomyelitis and pulmonary oedema are causally related.⁵

Conclusion

The case presented here is that of a previously healthy 2-year-old boy, with a rapidly fatal EV71 infection. The immediate cause of death was most likely brainstem encephalomyelitis. A high index of suspicion is essential for optimal management of such high-risk cases, in the event of an outbreak of enterovirus infection.

Acknowledgements

This paper was supported by a grant from the Tung Wah Group of Hospitals Research Fund. The authors thank Dr JSM Peiris and Dr WC Yam of the Department of Microbiology, Queen Mary Hospital, Hong Kong, for carrying out the virus isolation and RT-PCR tests for EV71 virus.

References

1. Schmidt NJ, Lennette EH, Ho HH. An apparently new enterovirus isolated from patients with disease of the central nervous system. *J Infect Dis* 1974;129:304-9.
2. Samuda GM, Chang WK, Yeung CY, Tang PS. Monoplegia caused by Enterovirus 71: an outbreak in Hong Kong. *Pediatr Infect Dis J* 1987;6:206-8.
3. Ishimaru Y, Nakano S, Yamaoka K, Takami S. Outbreaks of hand, foot, and mouth disease by enterovirus 71. High incidence of complication disorders of central nervous system. *Arch Dis Child* 1980;55:583-8.
4. Alexander JP Jr, Baden L, Pallansch MA, Anderson LJ. Enterovirus 71 infections and neurologic disease—United States, 1977-1991. *J Infect Dis* 1994;169:905-8.
5. Lum LC, Wong KT, Lam SK, et al. Fatal enterovirus 71 encephalomyelitis. *J Pediatr* 1998;133:795-8.
6. Ho M, Chen ER, Hsu KH, et al. An epidemic of enterovirus 71 infection in Taiwan. Taiwan Enterovirus Epidemic Working Group. *N Engl J Med* 1999;341:929-35.
7. Lum LC, Wong KT, Lam SK, Chua KB, Goh AY. Neurogenic pulmonary oedema and enterovirus 71 encephalomyelitis. *Lancet* 1998;352:1391.
8. Forster A, Gardaz JP, Suter PM, Gemperle M. Respiratory depression by midazolam and diazepam. *Anesthesiology* 1980; 53:494-7.

Coming in the **September** issue of
the *Hong Kong Medical Journal*

- ◇ Obstructive sleep apnoea in children
- ◇ Universal screening of human immunodeficiency virus infection in pregnant women
- ◇ Anaesthetic clinical indicators in 23 public hospitals
- ◇ A case of variant Creutzfeldt-Jakob disease in Hong Kong