

R Kay 祁理治  
A Wu 胡家倫

# Infections of the nervous system: an update on recent developments

## 神經系統感染：新近進展的更新

The past decade has seen major changes in the field of infectious diseases. In particular, many new infections of the nervous system have been recognised, including the lethal infections of Enterovirus 71, and the Nipah and West Nile viruses. Increased interest in prion diseases has occurred, following the recognition of animal-to-human transmission in Europe. Familiar bacteria such as the pneumococcus continue to cause problems due to increasing resistance to multiple antibiotics. Furthermore, human immunodeficiency virus-infected and other immunocompromised patients are under the constant threat of opportunistic infections, many of which are targeted towards the brain and spinal cord. This paper reviews the changing world of nervous system infection, highlighting some of the most significant recent developments.

過去的十年裡，傳染病領域發生了重大變化。尤其是許多新的神經系統感染得到了驗證，包括腸道病毒71，和尼帕與西尼爾病毒的致命感染。隨著在歐洲認識到動物與人類間的傳播，人們已增加了對朊病毒的關心。像肺炎球菌這樣的常見細菌，由於不斷增加對多種抗生素的抵抗力，仍繼續引起問題。此外，人類免疫缺陷病毒感染和其他缺乏免疫力的患者處於機會致病菌感染的持續威脅下，其中許多菌的目標是侵入大腦和脊髓。本文回顧了神經系統感染的變化狀況，並重點提出一些最重要的新進展。

### Key words:

*Central nervous system infections/  
diagnosis;*

*Central nervous system infections/  
treatment;*

*Opportunistic infections/  
epidemiology*

### 關鍵詞：

中樞神經系統感染／診斷；

中樞神經系統感染／治療；

機會致病菌感染／流行病

HKMJ 2001;7:67-72

Department of Medicine and Therapeutics,  
The Chinese University of Hong Kong,  
Prince of Wales Hospital, Shatin, Hong  
Kong

R Kay, MD, FRCP

A Wu, MB, ChB, MRCP (UK)

Correspondence to: Prof R Kay

## Introduction

To many physicians, the possibility of encountering a nervous system infection is always a source of anxiety. Not only are the physical signs of such infections often non-specific, but also the consequences of overlooking a treatable condition can be devastating. Moreover, the means of making a rapid diagnosis may be limited. The recognition in the past 2 decades of a number of new infectious agents, some of which are potentially lethal, adds further uncertainty to this difficult area of medicine. The purpose of this paper is to highlight some of these newer nervous system infections which are of regional or global interest. Recent developments in the management of older infections and opportunistic infections affecting human immunodeficiency virus (HIV)-infected individuals are also addressed.

## Bacterial infections

### *Pyogenic meningitis*

Pyogenic meningitis continues to be an important disease worldwide. Despite the availability of modern medical care, acute bacterial meningitis still carries a mortality rate for adults of 25%, which is similar to

the experience of the pre-antibiotic era.<sup>1</sup> Historically, the three most important pathogens are *Streptococcus pneumoniae*, *Neisseria meningitidis*, and *Haemophilus influenzae*. In North America and Europe, owing partly to immunisation practices, the incidence of meningitis caused by *H influenzae* has declined but *S pneumoniae* and *N meningitidis* remain important pathogens in children and young adults. In newborns, group B streptococcus is the most common pathogen associated with meningitis. *Listeria monocytogenes*, transmitted by contamination of processed food, is also recognised as a significant cause of meningitis in newborns and the elderly in the United States.<sup>2</sup>

Of particular interest to Southeast Asian physicians is the fact that the common bacteria causing meningitis in this region are somewhat different from those reported in the West. There are relatively few reports of meningitis caused by *N meningitidis* and *H influenzae* in this region and infections caused by *L monocytogenes* are also uncommon. In contrast, Gram negative bacilli such as *Klebsiella pneumoniae* and *Pseudomonas aeruginosa* are increasingly recognised as important pathogens, both in the context of community-acquired meningitis and nosocomial meningitis. This is particularly the case among the elderly and individuals with chronic debilitating diseases such as diabetes, cirrhosis, and malignancy.

Antibiotic-resistant strains of *S pneumoniae*, which remains the most important pathogen in community-acquired meningitis, are also increasingly recognised. For nosocomial meningitis (mainly related to head injury or neurosurgery), antibiotic-resistant strains of *Staphylococcus aureus* and *Acinetobacter baumannii* are causing problems for management.<sup>3</sup> Empirical treatment of community-acquired meningitis should include a third generation cephalosporin plus penicillin or ampicillin. For suspected penicillin-resistant *S pneumoniae*, however, vancomycin should be used in place of penicillin. In the treatment of neurosurgical or immunocompromised patients, vancomycin plus ceftazidime are the recommended agents.<sup>4</sup>

Uniquely in Hong Kong, two species of streptococci other than *S pneumoniae* have been identified as causes of community-acquired meningitis in adults. Meningitis caused by *Streptococcus suis*, once reported as the commonest cause of meningitis in Hong Kong, classically affects patients with occupational exposure to pigs or pork and causes early sensorineural hearing loss.<sup>5</sup> The incidence of this disease has declined in recent years and now only isolated cases are seen. Nonetheless, a high index of suspicion for this condition should be maintained since the hearing loss may be

averted by the early introduction of corticosteroids.<sup>6</sup> Of more topical interest, is the concurrent 1998 outbreak of meningitis in previously healthy adults, caused by the group B streptococcus, in Singapore and Hong Kong. This pathogen normally only causes meningitis in neonates.<sup>7</sup> Unlike *S suis* meningitis, no particular risk factor was noted for this streptococcal meningitis; nor was it confined to women, whom group B streptococci normally inhabit. It remains to be seen whether this neonatal pathogen will emerge as a significant cause of meningitis in Asia or elsewhere.

### **Tuberculous meningitis**

Tuberculous meningitis (TBM) is common in the Asian region. The annual incidence of TBM in Hong Kong is estimated at 1.8 per 100 000 population.<sup>8</sup> Although classically described as an indolent disease, with a prodromal illness of malaise, headache, and fever for 2 to 3 weeks, it is important to realise that TBM can present acutely with disease progression occurring within a few days. The diagnosis of TBM is not always straight-forward. Although imaging or cerebrospinal fluid (CSF) findings are helpful, definitive diagnosis can only be made if *Mycobacterium tuberculosis* is found in the CSF. Unfortunately, acid-fast staining of the CSF is only 5% to 30% sensitive, and culture has a sensitivity of only 20% to 50%.<sup>9</sup> Since isolation of *M tuberculosis* usually requires several weeks, various tests have been developed for rapid diagnosis of TBM. At present, the most promising is the polymerase chain reaction (PCR) assay for DNA fragments of the mycobacterium in the CSF, with a sensitivity close to or better than culture (50% to 85%).<sup>10</sup> In this era of increasing drug resistance, however, culture and sensitivity testing remains the cornerstone of management.

### **Lyme disease**

Lyme disease, like syphilis, is a multisystem disease with variable neurological manifestations. It is caused by a spirochaete, *Borrelia burgdorferi*, and transmitted by ticks. In the United States, Lyme disease is of great interest, as it accounts for over 90% of vector-borne infections. Although the disease is more prevalent in North America and Europe, it has also been seen in Japan and northeast China, and should be considered for patients returning from endemic areas with unexplained neurological syndromes. Diagnosis is often difficult as the CSF may be normal or show non-specific findings, and antibody tests vary in sensitivity and specificity. A prolonged course of antibiotic therapy (such as ceftriaxone 2 g/d for 2 to 6 weeks) is required for treatment. The prognosis is generally good and mortality rare, although some late neurological sequelae may persist.<sup>11</sup>

**Whipple's disease**

Whipple's disease is a much rarer systemic disorder which also has a variety of central nervous system (CNS) manifestations, including dementia, ophthalmoplegia, and myoclonus. It can also present as aseptic meningitis with CSF findings showing mild lymphocytic pleocytosis and elevated protein.

Until recently, the diagnosis of Whipple's disease has depended on the demonstration of macrophages containing periodic acid Schiff positive material in intestinal and other biopsies. Recently, however, a PCR technique for detection of the causative agent, *Tropheryma whippeli*, has been developed and successfully applied to the CSF. Treatment of Whipple's disease consists of intravenous ceftriaxone for a month, followed by an oral third generation cephalosporin or cotrimoxazole for up to 2 years; relapse is commonly reported.<sup>12</sup>

**Viral infections****Enterovirus 71**

Enterovirus 71 (EV 71) emerged as a significant nervous system pathogen in Asia following outbreaks in Sarawak (1997), Taiwan (1998), and most recently in Perth (1999). First recognised in California in 1969, this picornavirus is related to the Coxsackie A16 virus, both being causes of hand-foot-and-mouth disease in young children. In the 1998 outbreak in Taiwan, 78 patients died and another 405 had severe complications including brainstem encephalitis, poliomyelitis-like paralysis, myocarditis, and pulmonary oedema.<sup>13</sup> In Hong Kong, 427 patients were admitted to hospital with hand-foot-and-mouth disease in 1998, of whom four patients were identified with meningoencephalitis secondary to EV 71.

**Nipah and West Nile viruses**

Two zoonotic viruses, Nipah and West Nile, have attracted widespread publicity in recent years. In 1998, an outbreak of encephalitis occurred among pig-farmers in Malaysia. By 1999, a total of 258 cases were reported, with a mortality rate of almost 40%. The causative agent was not Japanese encephalitis virus which is endemic to the area, but a hitherto unknown virus subsequently named Nipah after the town in which the outbreak originated. Unlike Japanese encephalitis virus, which is transmitted by mosquitoes, Nipah virus appears to be transmitted by respiratory droplets from infected pigs.<sup>14</sup> The number of cases of Nipah encephalitis has fallen sharply since the Malaysian government implemented a number of control measures, but by that time, the disease had

spread to abattoir workers in Singapore. Nipah virus is a novel paramyxovirus similar to, but distinct from, the Hendra virus which has caused several deaths among Australian racehorse workers.

Likewise, there was an outbreak of West Nile virus infection in New York, in 1999.<sup>15</sup> Initial cases were reported by a physician who noted the unusual features of the disease, including encephalitis as well as profound weakness. The virus is now identified as an arbovirus belonging to the group of flaviviruses (other members include St. Louis and Japanese B encephalitis viruses), transmitted by mosquitoes from birds to humans. This viral infection had not been seen in the United States prior to 1999 and it has been postulated that the import of birds, either through natural migration or illegal means, may have been responsible for the introduction of the virus into the country.

**Dengue**

Dengue is the most important mosquito-borne virus disease in the world. It is prevalent in many parts of Asia and must be considered in any returning traveller with fever and rash. In its most severe form, it presents as haemorrhagic fever with shock. In recent years, milder CNS presentations such as headache, seizures, delirium, and cranial nerve palsies have been recognised. Although these neurological symptoms may be secondary to metabolic disturbances, the detection of IgM antibodies, and isolation of the virus from patient CSF, suggests that dengue may itself cause encephalitis.<sup>16</sup>

**Human T cell leukaemia viruses**

Human T cell leukaemia viruses (HTLV-1 and 2) belong to the large family of retroviruses, which includes the HIV-1 virus (indeed HIV-1 was previously known as HTLV-3). In 1985, HTLV-1 was serologically linked to a progressive spastic paraparesis, known as tropical spastic paraparesis in the West Indies. In Japan, a similar syndrome called HTLV-1 associated myelopathy (HAM) has been described. HTLV-1 is endemic in southern Japan and Taiwan but most seropositive individuals are asymptomatic, with less than 1% developing a neurological complication. Infection can be spread by sexual, parenteral, or vertical transmission. The incubation period for HTLV-1 can exceed 20 years, with HAM often recognised in the fifth decade as progressive spasticity of the legs, although occasionally acute cases resembling transverse myelitis may occur. Serological testing for HTLV-1 infection is available but definitive treatment for clinical cases remains to be determined.<sup>17</sup>



## Prion diseases

Prion diseases are neurodegenerative diseases caused by the accumulation of altered forms of normal host cell proteins, designated as prions (PRoteinaceous Infectious material). Until recently, four human prion diseases were known, namely, kuru, Creutzfeldt-Jakob disease (CJD), Gerstmann-Straussler-Scheinker syndrome, and fatal familial insomnia. Reports of variant Creutzfeldt-Jakob disease (vCJD) in the United Kingdom in 1996, suggested that cattle-to-human transmission of bovine spongiform encephalopathy (BSE or mad cow disease) had occurred. Variant CJD cases are characterised by a younger age of onset (mean is 29 years compared with 65 years for sporadic CJD) and a longer duration of disease (mean is 14 months versus 4 to 5 months),<sup>18</sup> although both diseases are uniformly fatal. A specific prion protein (type 4 PrP<sup>Sc</sup>) has been found in association with vCJD but rarely with other prion diseases, making it possible to diagnose this condition during life by tonsil biopsy.<sup>19</sup> Currently, there is no cure for any of the prion diseases. A number of actions implemented by the UK government have resulted in a decline in BSE. Only time will tell whether this will translate into a corresponding decline in the incidence of vCJD over the coming years.

## HIV-associated central nervous system infections

Opportunistic infections of the CNS in HIV-infected individuals are often the first sign of acquired immunodeficiency syndrome (AIDS). These 'AIDS-defining'

neurological illnesses include cerebral toxoplasmosis, cerebral nocardiosis (Fig), cryptococcal meningitis, tuberculous meningitis, cytomegalovirus encephalitis, progressive multifocal leukoencephalopathy, and HIV-associated dementia. Since the introduction of highly active antiretroviral therapy, the incidence of some of these infections has declined in some Western countries.<sup>20,21</sup>

### Cerebral toxoplasmosis

Cerebral toxoplasmosis is the result of reactivation of prior infection with the parasite *Toxoplasma gondii*. The typical presentation consists of focal cerebral dysfunction accompanied by fever, headache, and confusion, developing over days to weeks. Computed tomography (CT) or magnetic resonance imaging (MRI) reveals one or more ring-enhancing lesions. Empirical treatment commences with pyrimethamine, sulphadiazine, and folinic acid, followed by life-long maintenance prophylaxis.<sup>22</sup> Serial imaging should reveal regression of lesions after 10 to 14 days accompanied by clinical improvement. If this does not occur, primary CNS lymphoma must be considered.

### Syphilis

Syphilis occurs in HIV-negative individuals as well as in patients with AIDS. Although there has been a steady decline in the incidence of syphilis in the West in recent years, it is rising at an alarming rate in China, in parallel with the number of AIDS patients diagnosed.<sup>23</sup> In HIV-positive individuals, meningeal forms of early neurosyphilis may occur in patients previously treated for syphilis, suggesting a relapse of the condition. Syphilitic eye disease, gumma, and myelopathy

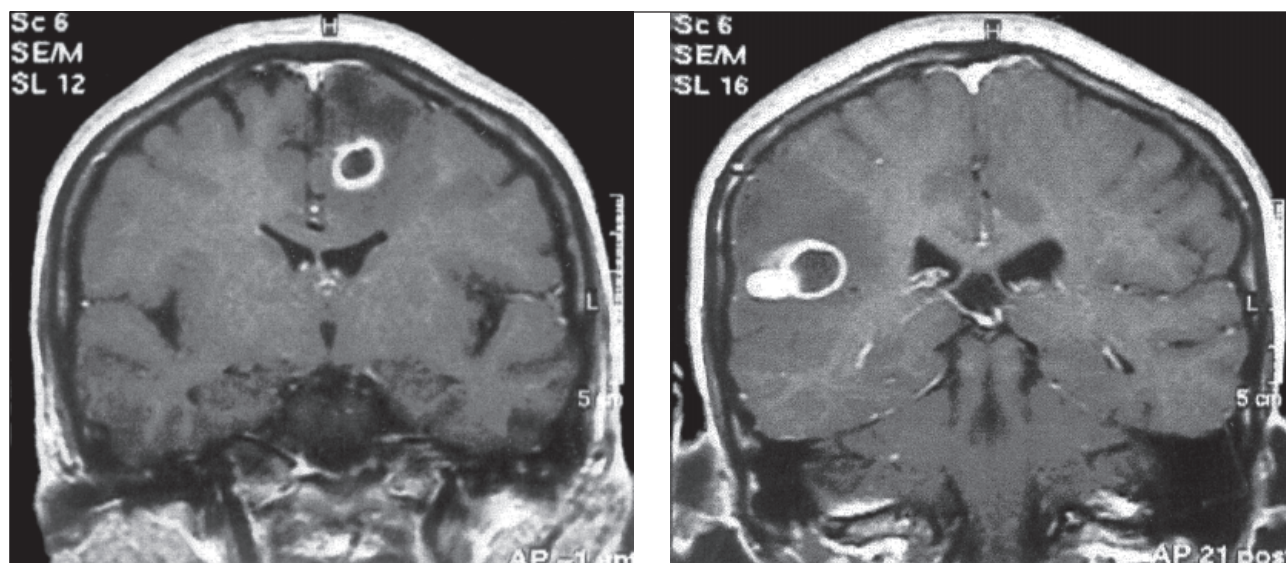


Fig. Cerebral nocardiosis: Magnetic resonance imaging of the brain of a 30-year-old woman who presented with fever and weight loss for 1 month, and generalised convulsion on the day of admission. She was found to have ulcers over the scalp and limbs from which *Nocardia asteroides* was isolated. Later she tested positive for HIV infection

are also reported to be more frequent in patients with AIDS. In the United States, it is recommended that HIV-positive individuals with suspected syphilis undergo a CSF examination before therapy.

### ***Cryptococcal meningitis***

Cryptococcal meningitis often occurs as a complication of advanced AIDS (CD4 count < 200/ml) or in other immunocompromised patients, although apparently healthy individuals can infrequently acquire the disease. Meningeal signs or symptoms may be absent in up to half of the patients. Instead, non-specific features such as failure to thrive, personality change, cognitive impairment, cranial neuropathy, and even coma may be the presenting complaint. Cryptococcal antigen testing of the CSF is the diagnostic method of choice, with a sensitivity exceeding 90%. It should routinely be performed for all AIDS patients undergoing a diagnostic CSF examination. Treatment includes amphotericin B plus flucytosine for 2 to 3 weeks, followed by fluconazole for patients who respond well, and then continuation of long term fluconazole as suppressive therapy.<sup>24</sup> The prognosis is good, provided the patient survives the initial stage of the disease.

### ***Cytomegalovirus***

Cytomegalovirus (CMV) may cause radiculomyelitis, peripheral neuropathy, retinitis, encephalitis, and ventriculitis, as well as non-neurological diseases such as colitis.<sup>25</sup> With CMV encephalitis, the patient typically presents with subacute confusion resembling HIV-associated dementia. CMV ventriculitis presents more acutely and carries a poorer prognosis. Given the poor prognosis of CMV ventriculoencephalitis, a trial of ganciclovir, foscarnet, and cidofovir, singly or in combination, may be justified.

### ***Progressive multifocal leukoencephalopathy***

Progressive multifocal leukoencephalopathy is a reactivated infection caused by a papovavirus, the JC virus. Prior to the AIDS era, it was an uncommon condition, occurring as a terminal event in patients with lymphoma or leukaemia. The virus causes little inflammation, only demyelination in the CNS, and the CSF is usually normal. Computed tomography or MRI reveals multiple non-enhancing white matter lesions with no mass effect, and brain biopsy is required for definitive diagnosis. Among advanced AIDS patients, mean survival is 2 to 4 months.<sup>26</sup> There is as yet no specific treatment for progressive multifocal leukoencephalopathy.

Human immunodeficiency virus itself can cause at least two distinct neurological syndromes: acute

aseptic meningitis and HIV-associated dementia. The former occurs at the time of seroconversion, causing the usual features of viral meningitis. Occasionally an encephalitic illness is seen and chronic forms of meningitis have been reported.<sup>27</sup> In addition, asymptomatic CSF abnormalities are common throughout the course of HIV infection. Patients with acute aseptic meningitis in whom HIV infection is suspected should undergo repeat serology for HIV after a few months if the initial test is negative.

Human immunodeficiency virus-associated dementia is a unique disorder to AIDS, with characteristic abnormalities consistent with a subcortical dementia. Mental slowing, impaired concentration and memory, impaired rapid limb movements, gait disorders, and spasticity with hyperreflexia are commonly seen, together with apathy, depression and even organic psychosis. Focal neurological deficits, as seen in progressive multifocal leukoencephalopathy, are uncommon and should prompt an alternative diagnosis. Human immunodeficiency virus-associated dementia frequently complicates advanced AIDS.<sup>28</sup> Direct invasion of neurons by the HIV virus may be the underlying pathology. Magnetic resonance imaging shows cerebral atrophy and symmetrical T2-intense white matter lesions. Since there are no other disease markers, exclusion of drug or metabolic effects and other infectious causes of dementia should be undertaken before the diagnosis of HIV-associated dementia is pronounced.

## **Conclusion**

Current problems facing physicians who may have to deal with nervous system infections include the emergence of novel pathogens, the spread of exotic infections, the increasing number of immunocompromised individuals, and the rapid development of microbial drug resistance. While new drug therapies and new technologies such as PCR can assist the current situation, these problems will persist and have the potential to become major public health issues in the 21st century.

## **References**

1. Durand ML, Calderwood SB, Weber DJ, et al. Acute bacterial meningitis in adults. A review of 493 episodes. *N Engl J Med* 1993;328:21-8.
2. Schuchat A, Robinson K, Wenger JD. Bacterial meningitis in the United States in 1995. *N Engl J Med* 1997;337:970-6
3. Lu CH, Chang WN, Chang HW. Adult bacterial meningitis in Southern Taiwan: epidemiologic trend and prognostic factors. *J Neurol Sci* 2000;182:36-44.

4. Tunkel AR, Scheld WM. Acute meningitis. In: Mandell, Douglas and Bennett's Principles and Practice of Infectious Diseases, 5th ed. Philadelphia: Churchill Livingstone; 2000.
5. Chau PY, Huang CY, Kay R. *Streptococcus suis* meningitis: an important underdiagnosed disease in Hong Kong. Med J Aust 1983;1:414-7.
6. Kay R, Cheng AF, Tse CY. *Streptococcus suis* infection in Hong Kong. Q J Med 1995;88:39-47.
7. Wilder-Smith E, Chow KM, Kay R, Ip M, Tee N. Group B streptococcal meningitis in adults: recent increase in South-east Asia. Aust N Z J Med 2000;30:462-5.
8. Mak W, Cheung RT, Ho SL, Tsang KL, Fong GC. Tuberculous meningitis in Hong Kong: experience in a regional hospital. Int J Tuberc Lung Dis 1998;2:1040-3.
9. Verdon R, Chevret S, Laissy JP, Wolff M. Tuberculous meningitis in adults: review of 48 cases. Clin Infect Dis 1996;22: 982-8.
10. Kox LF, Kuijper S, Kolk AH. Early diagnosis of tuberculous meningitis by polymerase chain reaction. Neurology 1995;45: 2228-32.
11. Coyle PK. Neurological aspects of Lyme disease. In: Davies LE, Kennedy PGE, editors. Infectious Diseases of the Nervous System. Oxford: Butterworth-Heinemann; 2000.
12. Anderson M. Neurology of Whipple's disease. J Neurol Neurosurg Psychiatry 2000;68:2-5.
13. Ho M, Chen ER, Hsu KH, et al. An epidemic of enterovirus 71 infection in Taiwan. N Engl J Med 1999;341:929-35.
14. Goh KJ, Tan CT, Chew NK, et al. Clinical features of Nipah virus encephalitis among pig farmers in Malaysia. N Engl J Med 2000;342:1229-35.
15. Asnis DS, Conetta R, Teixeira AA, Waldman G, Sampson BA. The West Nile Virus outbreak of 1999 in New York: the Flushing Hospital experience. Clin Infect Dis 2000;30:413-8.
16. Lam SK. Dengue infections with central nervous system manifestations. Neurol J Southeast Asia 1996;1:3-6.
17. Berger JR. HTLV-1 associated myelopathy. In: Johnson RT, Griffin JW, editors. Current therapy in neurologic disease. St. Louis: Mosby Year Book; 1997.
18. Zeidler M, Stewart GE, Barraclough CR, et al. New variant Creutzfeldt-Jakob disease: neurological features and diagnostic tests. Lancet 1997;350:903-7.
19. Collinge J. Variant Creutzfeldt-Jakob disease. Lancet 1999; 354:317-23.
20. d'Arminio Monforte A, Duca PG, Vago L, Grassi MP, Moroni M. Decreasing incidence of CNS AIDS-defining events associated with antiretroviral therapy. Neurology 2000;54: 1856-9.
21. Maschke M, Kastrup O, Esser S, Ross B, Hengge U, Hufnagel A. Incidence and prevalence of neurological disorders associated with HIV since the introduction of highly active antiretroviral therapy (HAART). J Neurol Neurosurg Psychiatry 2000;69:376-80.
22. Report of the Quality Standards Subcommittee of the American Academy of Neurology. Evaluation and management of intracranial mass lesions in AIDS. Neurology 1998; 50:21-6.
23. Chen XS, Gong XD, Liang GJ, Zhang GC. Epidemiologic trends of sexually transmitted diseases in China. Sex Transm Dis 2000;27:138-42.
24. Saag MS, Graybill RJ, Larsen RA, et al. Practice guidelines for the management of cryptococcal disease. Clin Infect Dis 2000;30:710-8.
25. McCutchan JA. Cytomegalovirus infections of the nervous system in patients with AIDS. Clin Infect Dis 1995;20:747-54.
26. Simpson DM, Berger JR. Neurologic manifestations of HIV infection. Med Clin North Am 1996;80:1363-94.
27. Price RW. Neurological complications of HIV infection. Lancet 1996;348:445-52.
28. Dal Pan GJ, McArthur JC. Neuroepidemiology of HIV infection. Neurol Clin 1996;14:359-82.