

# Percutaneous nephrostomy, nephrolithotomy and combined ureteroscopic lithotripsy using the supine approach

Raymond WM Kan 簡煒文  
Kenneth KF Fu 傅錦峯  
Bill TH Wong 黃德慶  
KL Ho 何崑崙  
MK Yiu 姚銘廣

**Objectives** (1) To evaluate the safety and efficacy of supine percutaneous nephrostomy, nephrolithotomy, and combined percutaneous nephrolithotomy and ureteroscopic lithotripsy. (2) To describe the skill-acquiring process in supine procedures and share our initial experience.

**Design** Three-staged case series with prospective data collection.

**Setting** Two public hospitals in Hong Kong.

**Patients and Interventions** Stage 1: Forty patients indicated for percutaneous renal access were recruited for supine percutaneous nephrostomy with prospective data collection. Stage 2: A prospective comparative study of percutaneous nephrolithotomy involving 60 patients allocated non-randomly to a supine (n=25) or prone (n=35) approach was conducted. Stage 3: Data of 11 patients who underwent simultaneous supine percutaneous nephrolithotomy and ureteroscopic lithotripsy were prospectively captured.

**Results** Stage 1: The procedural success rate was 100%. The mean operating time in unilateral procedures was 44 minutes; one patient had perinephric haematoma as a complication. Stage 2: Overall stone-free rates for prone and supine procedures were 46% and 68%, respectively ( $P=0.087$ ), and mean operating times were 122 and 123 minutes, respectively ( $P=0.905$ ). Stage 3: Of the 11 patients, six were rendered stone-free after the first combined procedure, and one experienced transient postoperative fever. There was no major complication.

**Conclusion** Percutaneous nephrolithotomy was feasible via both prone and supine approaches. With the exception of staghorn stones, the supine percutaneous approach was an equally safe and effective option for patients with specific conditions favouring such an approach. The ability to incorporate simultaneous ureteroscopic lithotripsy was an additional benefit of adopting the supine approach.

## Key words

Kidney calculi; Nephrostomy, percutaneous; Patient positioning; Supine position

*Hong Kong Med J* 2013;19:142-9

Department of Surgery, Queen Mary Hospital, Pokfulam, Hong Kong  
RWM Kan, MB, BS

KKF Fu, MB, ChB, FHKAM (Surgery)

KL Ho, MB, BS, FHKAM (Surgery)

MK Yiu, MB, BS, FHKAM (Surgery)

Department of Surgery, Queen Elizabeth Hospital, Jordan, Hong Kong  
BTH Wong, MB, BS, FHKAM (Surgery)

Correspondence to: Dr RWM Kan  
Email: kwm.raymond@yahoo.com

## New knowledge added by this study

- Supine percutaneous nephrolithotomy is a safe and effective option for patients with specific conditions favouring this approach.
- Incorporation of simultaneous ureteroscopic lithotripsy is an advantage of the supine approach.

## Implications for clinical practice or policy

- Competent endo-urolologists should be comfortable in performing percutaneous nephrolithotomy using the prone and supine approach.
- Learning curves for supine procedures were steep. Experience in prone procedures was a prerequisite to attempting supine procedures. Training in supine procedures should adopt a stepwise approach, from supine renal access to supine percutaneous nephrolithotomy, finally culminating in combined procedures.

## Introduction

Goodwin et al<sup>1</sup> first described percutaneous renal access in the prone position in 1955. In the next 20 years, techniques of tract formation and stone instrumentation matured. In 1976, Fernström and Johansson<sup>2</sup> reported their first case of stone extraction through a nephrostomy tract. Since its introduction, percutaneous nephrolithotomy has been

performed in the prone position, and probably due to promising results and low complication rates, the classic prone position has never been challenged. In 1987, Valdivia Uría et al<sup>3</sup> first described a 'simplified' technique of percutaneous nephrolithotomy in the supine position. Within 10 years, they also reported their experience in more than 500 patients treated in the supine position,<sup>4</sup> thus unquestionably establishing that both positions were feasible.

Over the ensuing years, however, the supine position has not secured the popularity it deserves. This could be explained by a more demanding learning curve for supine tract formation, and an unproven concern that such an approach increased the risk of visceral injury.

Owing to advancements in ureteroscopy that provide better vision, simultaneous percutaneous nephrolithotomy and ureteroscopic lithotripsy has become a new area to be explored for the treatment of upper tract urolithiasis. To facilitate this combination, in the last 5 years urologists have rekindled their interest in using the supine position. The literature has echoed this interest with several comparative studies<sup>5-8</sup> and reviews.<sup>9,10</sup> The advantages of supine and prone approaches are briefly summarised in Table 1.

We started adopting the supine approach in late 2007 to expand the scope and flexibility of our service. To uphold our standard of service and validate the presumed advantages of the supine approach, we captured the data from our initial experience. Herein, we describe our operative routines and present our data with the supine approach to share the steps undertaken to master the necessary skills, as a means of providing a guide for other interested urologists.

## Peri-operative preparation and intra-operative details

### Supine percutaneous nephrostomy

These procedures were performed in both emergency and semi-elective settings. All the patients received prophylactic intravenous antibiotics 30 minutes before operation. In the supine position, the ipsilateral loin was elevated by 40 to 50 degrees with two radiolucent plastic cushions placed under the upper back and at the iliac crest, thus placing the patient in a Valdivia position (Fig 1). The patient was positioned as close to the edge of operating table as possible, to ensure minimal conflict of instruments with the operating table.

The lower posterior calyx was the ideal puncture site. The end-arterial supply of the posterior branch of the renal vasculature permitted a relatively lower bleeding risk at this site. Using real-time ultrasonography, intervening bowel loops could be clearly visualised and avoided. The initial

## 採用仰臥姿勢進行經皮腎造瘻、腎穿刺取石術、和聯合輸尿管鏡碎石取石術

**目的** (一) 評估仰臥經皮腎造瘻、腎穿刺取石術、和聯合經皮輸尿管鏡碎石取石術的安全性和成效。(二) 描述仰臥程序中獲得的技能，以及分享初步經驗。

**設計** 利用前瞻性收集的數據分三個階段進行的病例系列研究。

**安排** 香港兩間公立醫院。

**患者及介入治療** 第一階段邀請40名以仰臥姿勢進行經皮腎臟造瘻的患者。第二階段前瞻性比較60名進行經皮腎穿刺取石術的病人，其中25人用仰臥姿勢，另35人用俯臥姿勢。第三階段前瞻性收集11名用仰臥姿勢同時進行經皮腎穿刺取石術及輸尿管鏡碎石取石術的病人數據。

**結果** 第一階段中，手術成功率100%，平均手術時間44分鐘；一名患者出現腎週血腫的併發。第二階段中，用俯臥和仰臥姿勢進行手術的病人的結石廓清率分別為46%及68% ( $P=0.087$ )，相應的平均手術時間為122及123分鐘 ( $P=0.905$ )。第三階段的11名病人中，6人接受第一次聯合手術後證實結石廓清，另1人術後出現短暫性發燒。病人中並無嚴重併發症。

**結論** 腎穿刺取石術無疑可以仰臥或俯臥姿勢進行。除了鹿角結石的情況外，以仰臥姿勢進行經皮術對於適合的病人來說既安全又有效。採取仰臥姿勢進行手術的另一個好處是可以同時進行輸尿管鏡碎石取石術。

estimation of the distance between the skin and the targeted pole facilitated the choice of instruments for the appropriate length.

After identifying the lower posterior calyx by ultrasound, the surgeon could rest his/her forearm and wrist on the patient while stabilising the ultrasound probe, and make a small stab skin incision near the probe. A 22-gauge skinny needle was inserted under ultrasound guidance, aiming it at the targeted pole. Visualising the echogenic needle tip facilitated a correct course for the puncture. As the kidney travelled cranio-caudally with each inspiration, forward advancement of the needle was only attempted when the targeted pole was in-line with the puncture course. A limited antegrade pyelogram delineating the pelvicalyceal system was used to confirm the correct positioning of the needle. A parallel puncture was performed with an 18-gauge nephrostomy needle, through which an Amplatz guidewire (Boston Scientific, Natick, US) was inserted. The tract was then dilated with Teflon dilators (Cook Medical, Bloomington, US) to 10 French for adequate renal drainage. A pigtail nephrostomy tube, or less often a Malecot nephrostomy tube (Cook Medical, Bloomington, US) was inserted and secured with an anchoring stitch. Free urine drainage

TABLE I. Advantages of prone and supine positions

Supine	Prone
Patient selection	
Accommodate patients who cannot assume prone position:	
Limb contracture	
Significant kyphosis	
Better position for obese patients:	
Cardiopulmonary compromise secondary to prone position is more pronounced in obese patients	
Anaesthetic concern	
Less cardiopulmonary compromise	
Less venous thromboembolic event	
Easy airway access in case of conversion to general anaesthesia	
Theatre staffing	
Less labour-demanding for patient mobilisation	
Entire procedure entails one draped position	
Surgeons' concern	
Comfortable sitting position	Traditional and familiar standing position
Less radiation exposure	
Time-saving in patient positioning	
Nephrostomy tract formation	
Facilitates simultaneous ureteroscope to access upper pole calyces	Easy access to upper pole calyces
Lower risk of colonic injury	Flexible working space allowing angulation of instruments and multiple access channels
Colon floats away instead of being pushed against the kidneys	Less caudal displacement of kidneys during respiration
	Less antero-medial movement of kidneys during tract dilatation
Stone manipulation	
Low pressure filling of collecting system minimising urosepsis	Good filling of collecting system to enhance nephroscopic vision and enlarge working space
Tract position encourages spontaneous stone evacuation	Better position for staghorn stones
	Shorter operating time
	Slightly better stone-free rates

or an optional completion antegrade pyelogram was used to confirm that the final position of the catheter was appropriate.

### Supine percutaneous nephrolithotomy

Patients were admitted to our urology ward 1 day before the operation for preoperative and anaesthetic assessment. They all received intravenous prophylactic antibiotics 30 minutes before operation, based on previous urine culture results; cefuroxime 750 mg was used for culture-negative patients.

The patient was placed in Lloyd Davis position and draped, whereupon 10 mL of 2% Lignocaine gel (AstraZeneca, Wilmington, US) was applied per urethra as a local anaesthetic agent and lubricant. A 21-French rigid cystoscopy was introduced. With the aid of a fluoroscopic C-arm X-ray, a Terumo guidewire (Terumo Medical Corporation, Somerset, US) was

inserted through the ureteric orifice. A 6-French ureteric catheter was then introduced over the guidewire to reach the renal pelvis retrogradely. A 14-French urethral catheter was placed for anchorage. Remaining in supine posture, the ipsilateral loin was elevated by 40 to 50 degrees with two radiolucent plastic cushions placed at the upper back and at the iliac crest, thus placing the patient in a Galdakao-modified Valdivia position.<sup>11</sup>

In addition to real-time ultrasonography, tract formation was also guided by the fluoroscopic C-arm X-ray with contrast injected via the ureteric catheter. The pyelographic images in the supine approach differed from those in prone position (Fig 2). In the prone position using real-time fluoroscopy, the lower posterior calyx was identified as the most medial lower calyx. This is because on fluoroscopy the medial lower calyx is almost always posterior-pointing. In the supine approach, instead of the

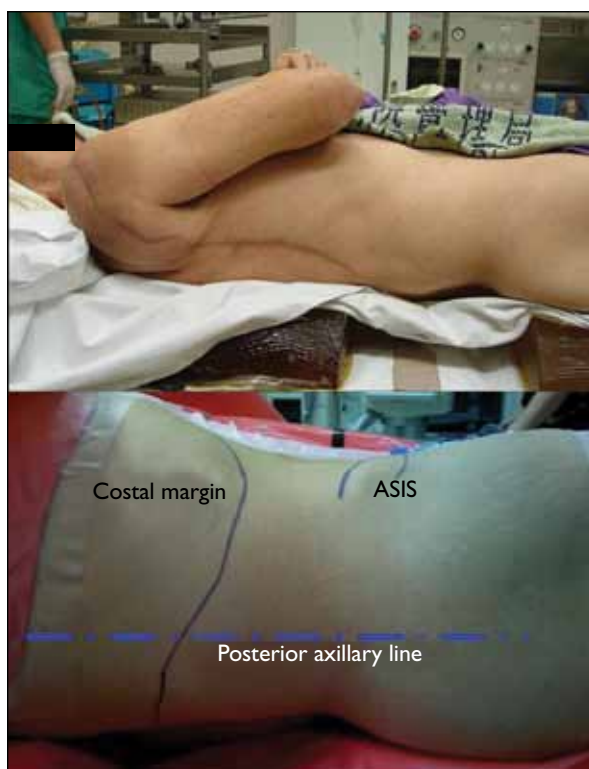


FIG 1. Patient positioning and outline of anatomical landmarks  
ASIS denotes anterior superior iliac spine

most medial lower calyx (evident on fluoroscopy), the lateral lower calyx indicates the true posterior-pointing lower pole calyx.

The technique of tract formation was similar to that used for percutaneous nephrostomy. Except that after tract dilatation with Teflon dilators to 10 French, the tract was further dilated with serial telescopic coaxial Alken dilators (Karl Storz, Tuttlingen, Germany) to 24-30 French. An extra-stiff guidewire was inserted over a dual-lumen catheter as a 'safety guide-wire'.

All stone manipulation procedures in our series were accomplished via a single nephrostomy tract. After insertion of a working sheath, the main stone burden was accessed with a 24-French rigid nephroscope and fragmented with an ultrasonic lithotripter or lithoclast. For distant and smaller stone fragments, a 16-French flexible nephroscopy and Holmium laser were employed.<sup>12</sup> At the end of the operation, a 16-to-20-French nephrostomy tube was inserted and the ureteric catheter was removed. The urethral catheter was removed 24 hours postoperation. After confirming stone clearance on plain films, the nephrostomy tube was spigotted and removed 24 to 48 hours postoperatively. If there was peri-catheter leakage, pain or persistent fever, the nephrostomy tube was unclamped and an early antegrade pyelogram was performed via the nephrostomy tube.

### Simultaneous supine percutaneous nephrolithotomy and ureteroscopic lithotripsy

After establishing a nephrostomy tract using a similar technique, a Terumo guidewire was inserted and the ureteric catheter was removed. A semi-rigid ureteroscope was introduced by another endourologist. Communication and cooperation of the two endo-urologists were of utmost importance, to ensure adequate stone clearance and avoid inadvertent complications. The stone burden was managed by fragmentation with an ultrasonic lithotripter or Holmium laser. At the end of the procedure, a 16-to-20-French nephrostomy tube was inserted with the intension of removing it 24 to 48 hours postoperatively.

### Methods

We started our prospective data collection in late 2007. Before commencement of data capture, the chief surgeon had performed over 100 prone position percutaneous nephrostomies with or without stone manipulation, and over 10 cases of percutaneous nephrostomies using the supine approach.

### Stage 1: supine percutaneous nephrostomy

From October 2007 to May 2010, we collected data

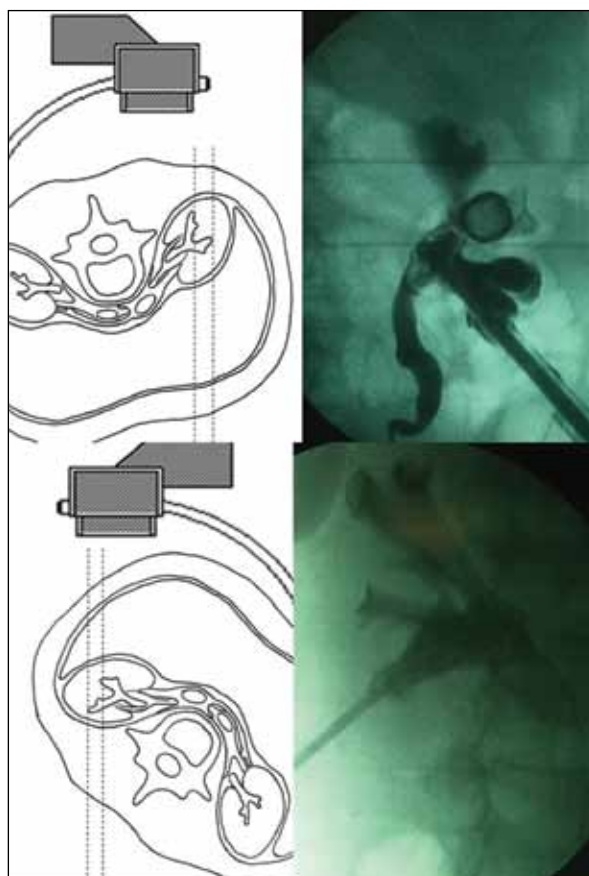


FIG 2. Prone and supine positions with real-time fluoroscopy



TABLE 2. Supine percutaneous nephrostomy

Patient characteristic	No. of patients (n=40)
Gender (male/female)	20/20
Median age (years)	66
Laterality (left/right/bilateral)	19/15/6
Indications	
Pyonephrosis	10 (25%)
Failed ureteric access	8 (20%)
Malignant obstructive uropathy	22 (55%)
Specific condition favouring supine posture	
Respiratory: COPD*, ventilatory support	7 (18%)
Abdominal: stoma in situ, recent laparotomy, large abdominal mass	6 (15%)
Limb contracture	3 (8%)
Mean operating time (mins)	
Unilateral	44
Bilateral	60
Overall	46
Complications	
Pseudoaneurysm requiring embolisation	0
Perinephric haematoma	1 (3%)
Pleural or bowel injury	0
Pelvic perforation	0

\* COPD denotes chronic obstructive pulmonary disease

of 20 men and 20 women on whom we performed percutaneous nephrostomy using the supine approach in our operating theatre (Table 2). Ten of these procedures were performed in an emergency setting to drain pyonephrosis, and the remaining 30 were semi-elective to manage malignant obstructive uropathy and failed ureteric access. In all, 16 of these patients had good or even compelling reasons favouring the supine procedure. These were poorly controlled chronic obstructive pulmonary disease, being on ventilator support, being post recent laparotomy with stoma created, having a bulky intra-abdominal malignancy, and limb contracture.

### Stage 2: supine versus prone percutaneous nephrolithotomy

From October 2007 to March 2010, 60 patients with urolithiasis were non-randomly assigned to undergo either supine (n=25) or prone (n=35) percutaneous nephrolithotomy (Table 3). Nine patients with specific conditions favouring or mandating a supine approach were allocated to the supine arm. These conditions included: limb contracture; previous myocardial infarction and asthma (to minimise cardiopulmonary stress); and abdominal stoma in situ. All 12 patients with staghorn stones were assigned to prone

procedures, as the latter enable shorter operating times and better stone-free rates for these patients.<sup>13</sup> For patients without specific conditions favouring either approach, the choice was at the discretion of the surgeon. Patients in both arms were similar in terms of gender, age, side affected, and mean stone burden. As expected, for prone procedures, there was significant skewing towards staghorn calculi.

### Stage 3: simultaneous supine percutaneous nephrolithotomy and ureteroscopic lithotripsy

From June 2009 to October 2010, we recruited 11 patients to undergo simultaneous percutaneous nephrolithotomy and ureteroscopic lithotripsy (Table 4). These patients had stones, which were expected to be difficult to manage via a single approach. They included: large (>2 cm) single-pole stones (n=4), heavy-burden multiple-pole stones (n=1), large (>1.5 cm) upper ureteric stones (n=5), and a large (>1.5 cm) middle ureteric stone. Among these patients, two underwent a planned second-stage percutaneous nephrolithotomy, and one patient with an upper ureteric stone was lost to follow-up (with no available information on the extent of stone clearance).

In stages 2 and 3, stone clearance was assessed by immediate postoperative plain radiography and follow-up computed tomography (CT).

Data input and statistical analysis was performed using the Statistical Package for the Social Sciences (Windows version 10.0; SPSS Inc, Chicago [IL], US), using *t* tests and Chi squared tests as appropriate. A *P* value of 0.05 was considered statistically significant.

## Results

### Stage 1: supine percutaneous nephrostomy

Unilateral percutaneous nephrostomy in the prone position, as documented in some published series,<sup>14,15</sup> were reported to be 48 to 49 minutes, on average. Our mean operating time for unilateral supine procedures was 44 minutes, and for bilateral procedures it was 60 minutes (Table 2). We attained a 100% procedural success rate for our 40 procedures, though one was complicated by perinephric haematoma for which the patient received blood transfusion. No bowel or pleural injury was encountered.

### Stage 2: supine versus prone percutaneous nephrolithotomy

In the 35 patients having prone procedures, the stone-free rates for single-pole, multiple-pole, partial staghorn, and staghorn stones were 90%, 33%, 50%, and 17%, respectively (Table 3). In our 25 patients having supine procedures, the respective rates were 75%, 50%, and 67%. The overall stone-free rates were

46% and 68% for prone and supine procedures, respectively, there being no statistical significance between the two groups. The overall residual stone sizes were 21 mm and 23 mm after prone and supine procedures, respectively. The mean operating durations for prone and supine procedures were 122 minutes and 123 minutes, respectively. The respective mean lengths of stay in hospital were 4.1 days and 4.2 days and the corresponding mean reductions in haemoglobin level were 9.3 g/L and 7.8 g/L, of which the differences were not statistically significant. One patient in the prone group and five in the supine group experienced transient postoperative fever, though none had culture-positive urosepsis. Two patients in the prone group and one in the supine group developed pseudoaneurysms on the operated kidney, all of which were treated by transcatheter embolisation. One patient in the prone group developed a postoperative perinephric haematoma and received blood transfusion. No bowel or pleural injury was encountered.

### Stage 3: simultaneous supine percutaneous nephrolithotomy and ureteroscopic lithotripsy

The mean length of hospital stay was 2.7 days and the mean operating duration was 106 minutes; one patient who had an upper ureteric stone was lost to follow-up. In all, six patients were confirmed stone-free after the first combined procedure, and two underwent a planned second-stage supine percutaneous nephrolithotomy. On further follow-up imaging, eight patients were confirmed stone-free, one was lost to follow-up, and two had single residual stones (2 mm and 4 mm). Both of the latter patients remained asymptomatic and opted not to undergo further interventions. Another patient experienced transient postoperative fever, but there was no instance of culture-positive urosepsis or adjacent organ injury.

## Discussion

Our three-staged progression model adequately described our exploration and learning curve in supine renal access and stone manipulation. These stages served as a learning guide for young urologists as well as for establishing urology units.

For percutaneous nephrostomy via the supine approach, we positioned our patients in Valdivia's position (Fig 1), with the ipsilateral loin elevated by 40 to 50 degrees. For supine percutaneous nephrolithotomy and combined procedures, we adopted the Galdakao-modified Valdivia's position,<sup>11</sup> besides ipsilateral loin elevation, this entailed keeping the ipsilateral leg extended and the contralateral leg well abducted. A cushion elevating the ipsilateral hip further facilitated the placement of a ureteroscope.

From patient positioning to kidney mobility, the supine approach differed substantially from the traditional prone position. In the latter position, the

TABLE 3. Supine versus prone percutaneous nephrolithotomy

Patient characteristic	Prone (n=35)	Supine (n=25)	P value
Gender (male/female)	21/14	14/11	0.757
Median age (years)	63	67	0.284
Laterality (left/right)	17/18	9/16	0.333
Stone characteristics			
Single pole	10	16	0.005
Multiple ( $\geq 2$ ) poles	9	6	
Partial staghorn	4	3	
Staghorn	12	0	
Mean (range) stone burden (mm)			
Single pole	22.5 (13-30)	33.2 (10-90)	0.174
Multiple ( $\geq 2$ ) poles	52.0 (20-110)	43.7 (28-70)	
Partial staghorn	39.5 (25-55)	43.0 (34-54)	
Staghorn	59.7 (45-100)	-	
Overall	44.8 (13-110)	36.9 (10-90)	
Specific condition favouring supine posture			
Limb contracture	-	4 (16%)	
Cardiac: previous myocardial infarction	-	3 (12%)	
Respiratory: asthma	-	1 (4%)	
Abdominal: stoma in situ	-	1 (4%)	
Complete stone clearance (rate)			
Single pole	9 (90%)	12 (75%)	0.345
Multiple ( $\geq 2$ ) poles	3 (33%)	3 (50%)	0.519
Partial staghorn	2 (50%)	2 (67%)	0.659
Staghorn	2 (17%)	-	-
Overall	16 (46%)	17 (68%)	0.087
Mean (range) residual stone size (mm)			
Single pole	8 (8)	23 (8-55)	0.851
Multiple ( $\geq 2$ ) poles	19 (5-70)	29 (10-42)	
Partial staghorn	10 (5-15)	3 (3)	
Staghorn	26 (6-80)	-	
Overall	21 (5-80)	23 (3-55)	
Mean (range) operating time (mins)	122 (25-235)	123 (60-207)	0.905
Mean (range) length of stay (days)	4.1 (1-10)	4.2 (1-8)	0.916
Mean (range) blood loss (mL)	71 (0-400)	84.3 (10-300)	0.629
Mean (range) haemoglobin drop (g/L)	9.3 (1-20)	7.8 (1-28)	0.538
Complications			
Postoperative fever	1	5	-
Culture-positive urosepsis	0	0	
Pseudoaneurysm requiring embolisation	2	1	
Perinephric haematoma	1	0	
Pleural or bowel injury	0	0	
Renal pelvis perforation	0	0	

**TABLE 4.** Simultaneous supine percutaneous nephrolithotomy (PCNL) and ureteroscopic lithotripsy

Patient characteristic	No. of patients (n=11)		
Gender (male/female)	7/4		
Median age (years)	61		
Laterality (left/right)	4/7		
Stone characteristics			
Single pole	4		
Multiple (≥2) poles	1		
Upper ureteric	5		
Middle ureteric	1		
Mean (range) stone burden (mm)			
Single pole	26 (20-40)		
Multiple (≥2) poles	57 (57)		
Upper ureteric	26 (15-54)		
Middle ureteric	15 (15)		
Overall	28 (15-57)		
Anaesthesia			
Local anaesthesia	10 (91%)		
General anaesthesia	1 (9%)		
Stone clearance after 1st procedure		Patients with residual stone	Lost to follow-up
Single pole	2 (50%)	2	
Multiple (≥2) poles	0 (0%)	1	
Upper ureteric	3 (60%)	1	1
Middle ureteric	1 (100%)	0	
Overall	6 (55%)	0	
Ultimate stone clearance (2 patients undergone 2nd-stage PCNL)		Patients with residual stone	Lost to follow-up
Single pole	3 (75%)	1	
Multiple (≥2) poles	1 (100%)	0	
Upper ureteric	3 (60%)	1	1
Middle ureteric	1 (100%)	0	
Overall	8 (73%)	0	
Residual stone size (mm)			
Single pole	4		
Multiple (≥2) poles	0		
Upper ureteric	2		
Middle ureteric	0		
Mean (range) length of stay (days)	2.7 (1-10)		
Mean (range) operating time (mins)	106 (64-132)		
Complications			
Postoperative fever	1		
Culture-positive urosepsis	0		
Pseudoaneurysm requiring embolisation	0		
Perinephric haematoma	0		
Pleural or bowel injury	0		
Renal pelvis perforation	0		

kidney is relatively immobile during puncture and tract dilatation. In the supine approach, however, the lack of abdominal compression allows anterior and medial displacement of the kidney during telescopic tract dilatation. We explored the use of two different instruments for tract formation: the Amplatz balloon dilators and the Alken telescopic dilators. In theory, the former minimised the chance of tract loss by avoiding repeated pushes on a free-floating kidney. We reckoned that the controversies regarding Alken telescopic dilators and Amplatz balloon dilators warranted further clinical evaluation.

In the first stage, we achieved a 100% procedural success rate and attained a low complication rate. We established that supine percutaneous nephrostomy was a safe and a preferred option for patients with specific conditions favouring such an approach. The technique of tract formation acquired in supine percutaneous nephrostomy was an important stepping stone for our next stage of stone manipulation.

Surgeons who were keen to perform supine procedures should be adept in the use of real-time ultrasonography. This form of visualisation during renal puncture was crucial to ensure an accurate puncture and avoid bowel or pleural injury. In traditional urology training for prone percutaneous nephrolithotomy, there was minimal application of real-time ultrasonography. The under-utilisation of this handy, low-cost, and readily available tool was probably a hurdle to many surgeons wishing to explore supine procedures.

In the second stage of our study, we compared percutaneous nephrolithotomy using the prone and supine approach. With the exception of staghorn stones, supine percutaneous nephrolithotomy seemed to be as safe and effective for patients with specific conditions favouring this approach. For staghorn stones, existing evidence suggests that adoption of the prone position is preferable.<sup>12</sup> There was an increased rate of transient postoperative fever after supine procedures, but we do not have an explanation for this observation as no patient had culture-positive urosepsis.

A number of intangible advantages also support adoption of the supine approach. Besides the obvious advantages in patients who were physically or physiologically deprived, advantages also exist in terms of anaesthetic concerns, theatre staffing, and surgeons' concerns (Table 1).

In the third stage of our study, we explored the use of combined procedures for 'difficult' single-pole stones that were mainly larger than 2 cm and upper ureteric stones larger than 1.5 cm. We were able to achieve a reasonable stone-free rate; only two out of 11 patients had small (<4 mm) residual stones revealed by follow-up CT. Based on our initial

experience, simultaneous procedures appeared well-tolerated and promising.

When performing ureteroscopic lithotripsy for large ureteric stone in the Lloyd Davis position, a surgeon with experience in combined procedures enjoys practical advantages. If the ureteric stone migrates into a hydronephrotic kidney after ureteroscopic manipulation, the surgeon could opt to perform a supine percutaneous nephrolithotomy, thus converting the operation into a combined procedure.

Overall, our study was an unprecedented description of a stepwise model in the training for supine procedures, and a sharing of our valuable experience on the steps which a surgeon needs to become proficient at supine procedures.

### Limitations

One obvious limitation of our study was that it represented the experience and learning curve of a single surgeon. Secondly, our small sample size invariably limited the power of our comparisons. Thirdly, allocation of patients in stage 2 into prone or supine procedures was subjective and non-randomised. Finally, the selection of patients to undergo combined procedures was also dependent on the surgeon's preference, which meant that

selection bias was inevitable.

### Future directions

A step forward in the evaluation of supine procedures could be constructive. A multi-centred, randomised trial would be ideal to achieve this goal.

### Conclusion

Percutaneous nephrolithotomy is unquestionably feasible using both prone and supine approaches. With the exception of staghorn stones, supine percutaneous nephrolithotomy seemed to be an equally safe and effective option for patients with specific conditions favouring this approach. The ability to incorporate simultaneous ureteroscopic lithotripsy was an additional benefit of adopting the supine approach. We described our three-staged skills acquisition exercise as a reference for young urologists as well as for establishing urology units.

### Declaration

All operative procedures were performed or supervised by Dr Fu, one of the co-authors. Other co-authors contributed in skills transfer and expert opinion. No conflict of interest was declared by the authors.

### References

1. Goodwin WE, Casey WC, Woolf W. Percutaneous trocar (needle) nephrostomy in hydronephrosis. *J Am Med Assoc* 1955;157:891-4.
2. Fernström I, Johansson B. Percutaneous pyelolithotomy. A new extraction technique. *Scand J Urol Nephrol* 1976;10:257-9.
3. Valdivia Uría JG, Lachares Santamaría E, Villarroya Rodríguez S, Taberner Llop J, Abril Baquero G, Aranda Lassa JM. Percutaneous nephrolithotomy: simplified technic (preliminary report) [in Spanish]. *Arch Esp Urol* 1987;40:177-80.
4. Valdivia Uría JG, Valle Gerhold J, López López JA, et al. Technique and complications of percutaneous nephroscopy: experience with 557 patients in the supine position. *J Urol* 1998;160:1975-8.
5. Neto EA, Mitre AI, Gomes CM, Arap MA, Srougi M. Percutaneous nephrolithotripsy with the patient in a modified supine position. *J Urol* 2007;178:165-8.
6. Steele D, Marshall V. Percutaneous nephrolithotomy in the supine position: a neglected approach? *J Endourol* 2007;21:1433-7.
7. De Sio M, Autorino R, Quarto G, et al. Modified supine versus prone position in percutaneous nephrolithotomy for renal stones treatable with a single percutaneous access: a prospective randomised trial. *Eur Urol* 2008;54:196-202.
8. Falahatkar S, Moghaddam AA, Salhei M, Nikpour S, Esmaili F, Khaki N. Complete supine percutaneous nephrolithotripsy comparison with the prone standard technique. *J Endourol* 2008;22:2513-7.
9. Duty B, Okhunov Z, Smith A, Okeke Z. The debate over percutaneous nephrolithotomy positioning: a comprehensive review. *J Urol* 2011;186:20-5.
10. Wu P, Wang L, Wang K. Supine versus prone position in percutaneous nephrolithotomy for kidney calculi: a meta-analysis. *Int Urol Nephrol* 2011;43:67-77.
11. Ibarluzea G, Scoffone CM, Cracco CM, et al. Supine Valdivia and modified lithotomy position for simultaneous antegrade and retrograde endourological access. *BJU Int* 2007;100:233-6.
12. Fu KF, Lo HK, Kan CF, Chan KK. Percutaneous nephrolithotomy outcomes: re-audit in 2005. *Surg Pract* 2008;12:84-8.
13. de la Rosette JJ, Tsakiris P, Ferrandino MN, Elsakka AM, Rioja J, Preminger GM. Beyond prone position in percutaneous nephrolithotomy: a comprehensive review. *Eur Urol* 2008;54:1262-9.
14. Pearle MS, Pierce HL, Miller GL, et al. Optimal method of urgent decompression of the collecting system for obstruction and infection due to ureteral calculi. *J Urol* 1998;160:1260-4.
15. Sood G, Sood A, Jindal A, Verma DK, Dhiman DS. Ultrasound guided percutaneous nephrostomy of obstructive uropathy in benign and malignant diseases. *Int Braz J Urol* 2006;32:281-6.