

Diagnosing the cause of vertigo: a practical approach

CME

Alex TH Lee 李定漢

Dizziness is among the commonest of chief complaints. It often presents a significant challenge to the attending physician, because the symptoms and signs are often vague and non-specific. However, a robust systematic approach can usually arrive at the diagnosis. Maintaining balance requires sensory inputs from the vestibular, visual, and somatosensory systems and the cerebellum fine-tunes inaccurate motor outputs. Causes of vertigo are most commonly otological, followed by central, somatosensory, and visual. The first question in approaching patients with dizziness is to categorise dizziness into one of the four groups: lightheadedness, pre-syncope, disequilibrium, and vertigo. Secondly, central vertigo has to be differentiated with peripheral vertigo. For peripheral vertigo, the most common cause is benign paroxysmal positional vertigo and should be specifically looked for. The tempo of the vertiginous attacks and other associated symptoms can help differentiate the other causes of peripheral vertigo, including Meniere's disease, vestibular neuronitis, labyrinthitis, and a perilymph fistula.

Introduction

Dizziness is one of the most common chief complaints, especially in the geriatric age-group. The incidence of dizziness in the general population is about 20 to 30%.¹ This chief complaint often provokes a sense of fear and dizziness in the doctor, because the number of possible differential diagnoses is extensive. Often the symptoms and signs are vague, non-specific and hard to define, which presents a significant challenge to the attending physician.² Nevertheless, a robust systematic approach can usually arrive at the diagnosis. The following is not a comprehensive review, but provides a practical approach to dealing with patients presenting with vertigo.

Physiology

Maintaining balance is a complex task requiring sensory inputs from the vestibular, visual, and somatosensory systems. These sensory inputs are integrated at the vestibular nuclei and entail two major reflexes—the vestibulo-ocular reflex, which stabilises our vision during movement, and the vestibulo-spinal reflex, which helps us to stabilise posture. The cerebellum serves to fine-tune inaccurate motor outputs.

The vestibular organs consist of three semicircular canals (superior, lateral, posterior) and two otolithic organs (utricle and saccule) [Fig 1]. Each semicircular has a dilatation (ampulla) at the anterior end. In each ampulla, sensory cells (hair cells) are situated on a saddle-shaped ridge called the crista. Cilia of hair cells are embedded in a gelatinous mass called the cupula. Flow of the endolymph causes movement of the cupula, which in turn causes depolarisation of hair cells. Each afferent neuron has a baseline firing rate. Shearing of stereocilia on the hair cell towards the kinocilium is excitatory and results in an increased firing rate; deflection away from it causes reduction in the firing rate (Fig 2). The neural output from a semicircular canal on one side is compared to the other side. The brain interprets the difference in discharge rates as movement.

The otolithic sensory organs are located at the maculae of the utricle and the saccule. They sense gravity and linear acceleration. Cilia from hair cells are embedded in gelatinous layer with otoliths (otoconia) on the upper surface. Otoconia is heavier than the endolymph. When we tilt our heads, the cilia in the otoconial membrane are displaced relative to the sensory epithelium and cause a change in the firing rate of the afferent neuron.

Approach to vertigo

For many doctors, the task of making a satisfactory diagnosis of the cause of vertigo

Key words

Benign paroxysmal positional vertigo;
Dizziness; Reflex, vestibulo-ocular;
Vertigo; Vestibular neuronitis

Hong Kong Med J 2012;18:327-32

Department of ENT, Tuen Mun Hospital,
Tuen Mun, Hong Kong
ATH Lee, FRCS

Correspondence to: Dr Alex Lee
Email: alexth.lee@gmail.com

診斷眩暈病因的實用方法

眩暈是病人看病時主訴症狀中最普遍的一種。由於其症狀體徵模糊及未夠具體，對醫生來說往往造成診斷的挑戰。使用實在而系統化的方法有助診斷眩暈。人類需靠前庭、視覺和體感系統輸入感覺，加上小腦對於不準確的動作信號作出微調，才可保持平衡。眩暈的病因大多與耳部、中樞、體感及視覺系統有關。要診斷眩暈的病人要先把其眩暈歸類，分別是頭暈、近似暈厥、不平衡和眩暈。其次，要把中樞性眩暈與周圍性眩暈區分。屬周圍性眩暈的，要特別找出是否屬於良性發作性位置性眩暈，因為這種是最常見的。憑藉發作性眩暈的頻率與其他有關症狀可分辨不同類型的周圍性眩暈，包括梅尼埃病、前庭神經元炎、迷路炎及外淋巴瘻管。

is daunting. In most cases, laboratory tests and radiological investigations are not helpful to making a diagnosis. In fact, a detailed history with a systematic approach is the most important component in evaluating patients with dizziness. Causes of vertigo are most commonly otological, followed by central, somatosensory, and visual.^{3,4} In obtaining the history, there are several questions that are of great help to sort out the causes.

What does the patient mean by dizziness?

The first question is "What does the patient mean by dizziness?" Is it giddiness or true vertigo? The term 'dizziness' is often used to describe a variety of subjective symptoms and should be avoided. It is useful to ask the patient to describe the experience using words other than 'dizziness'. Dizziness can usually be categorised into one of the four groups: lightheadedness, pre-syncope, disequilibrium, and vertigo (Table 1).^{5,6}

Non-specific lightheadedness is the most common form of dizziness. Often the patient's symptom is vague and subjective. They might use terms such as giddiness or wooziness to describe their imbalance. An important aspect is that the patient never actually falls or veers. Causes of non-specific lightheadedness include hyperventilation, hypoglycaemia, anaemia, head trauma, and associated with psychogenic disorders such as depression, anxiety, or phobia.^{7,8}

Pre-syncope is a sensation of impending faintness or loss of consciousness. The patient may also experience generalised weakness. Often the symptom occurs when the patient rises from a lying or sitting position. Symptom is typically worse in the morning. No symptom is experienced when the patient is supine. Causes include orthostatic hypotension, autonomic dysfunction which can be the result of diabetes, and cardiovascular diseases like arrhythmias, myocardial infarction, and carotid artery stenosis.⁹ Medications like anti-hypertensive and anti-arrhythmic drugs can sometimes cause pre-syncope.

Disequilibrium means an impaired balance and gait without abnormal head sensation. The patient has a feeling of unsteadiness but there is no illusion of movement or sensation of faintness. The most common cause is ageing. Ageing produces multi-sensory deficits that affect balance. Degeneration is evident in the ampullae of the semicircular ducts and the otolith organs,^{10,11} as well as in the vestibular nuclei and brainstem pathways.¹² Visual acuity and proprioception also decrease with ageing. Vestibular sedatives are not useful in this situation. Instead, a vestibular rehabilitation programme or even just a walking stick can help the patient a great deal.

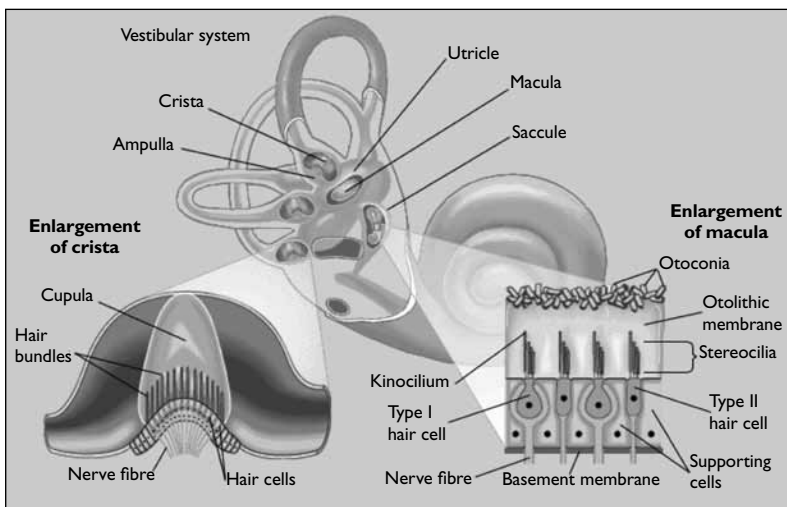


FIG 1. Vestibular organs
By courtesy of Encyclopaedia Britannica, Inc., copyright 1997; used with permission

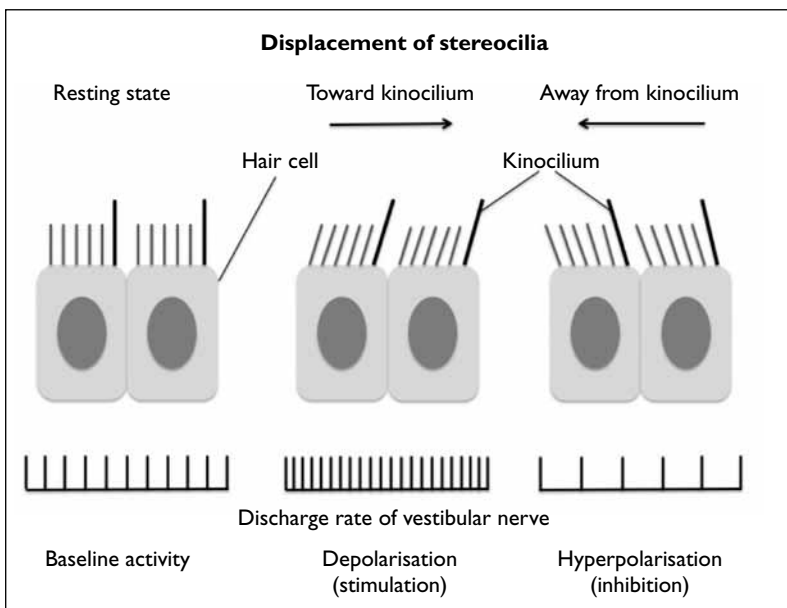


FIG 2. Change in firing rate in relation to displacement of stereocilia

Other causes of disequilibrium include peripheral neuropathy, musculoskeletal disorder, gait disorder, and Parkinson's disease. If the patient complains of disequilibrium and has a poor gait at the same time, a central cause like a cerebellar problem is possible and the patient should be referred for neurological evaluation.

Vertigo is a hallucination of movement. It is typically but not necessarily rotatory and suggests a lesion in the vestibular system.

Is the vertigo central in origin?

The second question is: "Is the vertigo central in origin?" The semicircular canals, the saccule, the utricle, and the vestibular nerve constitute the peripheral vestibular system. The vestibular nuclei, cerebellum, brainstem, spinal cord, and the vestibular cortex made up the central vestibular system. Peripheral vertigo is always temporary. Even in the most severe form of peripheral vertigo experienced in vestibular nerve section, the vertigo might last for a few days to weeks and will get better. The vertigo may be recurrent or episodic but it will not last continuously for a few months. Peripheral vertigo is usually sudden in onset and is always made worse by head movement.^{13,14} Patients do not have peripheral vertigo if they are dizzy all the time and are happy to move around whilst dizzy. Peripheral nystagmus can

be horizontal or torsional but never vertical and it decreases with visual fixation. Central vertigo is more gradual or subacute in onset, and may be constant. The vertigo and nystagmus can be in all directions including vertical and is not suppressed by visual fixation (Table 2).¹⁵ Central vertigo may be associated with other neurological symptoms like cerebellar signs, ataxia, dysarthria, diplopia, visual disturbance, or limb weakness. The patient might have other risk factors of cerebrovascular diseases. Some of the causes of central vertigo include migraine, vertebrobasilar insufficiency, stroke, transient ischaemic attack, tumour, and multiple sclerosis. Although central cause of vertigo is less common, some of the central causes can be potentially fatal and the patient should be referred for neurological assessment if central vertigo is suspected. Causes of peripheral vertigo include benign paroxysmal positional vertigo (BPPV), Meniere's disease, vestibular neuronitis, perilymph fistula, labyrinthitis, herpes zoster oticus, labyrinthine concussion, and superior canal dehiscence syndrome.

How long does the vertigo last?

The third question is: "How long does the vertigo last?" Vertigo lasting for seconds is likely to be BPPV. If lasting for minutes, it can be vertebrobasilar insufficiency or transient ischaemic attack. Vertigo of minutes to hours suggests Meniere's syndrome

TABLE 1. Categories of dizziness^{5,6}

Category	Characteristics	%
Vertigo	Hallucination of movement, commonly rotatory	45-54
Disequilibrium	Impaired balance or gait, wobbly, sense of unsteadiness	Up to 16
Pre-syncope	Sensation of impending faint or loss of consciousness	Up to 14
Lightheadedness	Vague symptom, giddiness or wooziness, feeling disconnected	~10

TABLE 2. Central versus peripheral vertigo

	Central vertigo	Peripheral vertigo
Direction	Can be vertical or other direction, may change direction with change in gaze	Horizontal or torsional, never vertical, same direction in all gazes
Onset	Subacute or slow	Acute
Visual fixation	Not suppressed	Suppressed
Nausea, vomiting	Varies	May be severe
Otological symptoms	Rare	Common
Neurological symptoms	Common	Rare
Instability	Severe, unable to stand	Mild to moderate
Fatigability	Not fatigable	Fatigable
Duration	Persists	Short duration, may decrease after a few days

or migraine. If it continues for hours to days, it points more to acute vestibular failure, like infective labyrinthitis, vestibular neuronitis or ototoxicity. Vertigo that is constant for weeks suggests psychogenic causes or central lesions.¹⁶ The patient's medications, any recent surgery or trauma, otological symptoms like hearing loss, tinnitus, and otorrhoea may provide clues.

Other causes of peripheral vertigo

Benign paroxysmal positional vertigo

It is the commonest cause of vertigo, and deserves special attention as it is very characteristic and highly treatable.^{1,4,13,17} It is caused by loose otoconia displaced into the semicircular canal, known as canalithiasis. Otoconia may also be dislodged after head trauma or vestibular damage,¹⁸ eg vestibular neuronitis or a vascular insult. The posterior canal is involved in 85 to 95% of instances and the lateral canal in less than 10%.¹⁹ Classically, the patient experiences rotatory vertigo lasting for seconds when they look up rapidly, lying down or rolling over onto the affected ear in bed. The change in head position results in displacement of the loose canalith in response to gravity. The vertigo stops once the canalith (mal-positioned particle) settles in the most dependent position. This usually lasts for seconds. There is no tinnitus or hearing loss. The patient experiences nausea but the vertigo is too transient to evoke vomiting. The diagnosis of BPPV can readily be confirmed with Dix-Hallpike manoeuvre. Patient's head is turned 45 degrees to the testing side in order to maximally stimulate the posterior semicircular canal. With the head supported, the patient lies down rapidly and is placed into a head-hanging position about 15 to 20 degrees over the end of the table. This will provoke nystagmus and vertigo. The nystagmus is typically up-beating and geotropic (fast phase towards the ground), with a latency of 2 to 15 seconds. It lasts 15 to 45 seconds and fatigues easily. If one repeats the manoeuvre, the nystagmus will become less, and might even be absent after three to four attempts. Medication is usually not useful for controlling BPPV symptoms. The treatment of choice is Epley's manoeuvre,^{20,21} which is a canalith repositioning technique that moves it from the semicircular canal into the vestibule. It has a success rate of over 90%.²¹ If repeated attempts failed to correct the canalithiasis, the patient should be referred to an ear, nose and throat (ENT) specialist for assessment.

Meniere's disease

Meniere's disease is characterised by episodes of rotatory vertigo lasting minutes to hours, associated with low-tone sensorineural hearing loss, tinnitus, aural fullness, nausea, and vomiting.²² Most patients

are middle-aged, and symptoms rarely start in persons aged 60 years or older. The underlying pathogenesis is over-accumulation of endolymph within the inner ear. The exact aetiology of this hydrops is unknown.^{22,23} The endolymphatic hydrops leads to distortion and build up of pressure in the membranous labyrinth resulting in micro-ruptures, which are responsible for the episodic nature of attacks. The healing of ruptures accounts for the return of hearing. The natural history is for spontaneous remission in 60 to 80% of the patients, whilst 10 to 20% have intractable symptoms.²² Bilateral disease is encountered in about 24% of patients.²⁴ Medical treatment includes vestibular sedatives and anti-emetics, like diazepam and promethazine (during the acute attack). A low-salt diet, diuretics (eg amiloride), vasodilators (eg betahistine), and avoidance of caffeine are commonly used for prophylaxis. To date, no conclusive studies have shown efficacy for drugs intended to alter the disease course of Meniere's disease.²⁵⁻²⁷ Systematic reviews have shown that intra-tympanic gentamycin was useful in severe disease.²⁸ In patients with intractable symptoms, endolymphatic sac surgery or ablative surgery (vestibular neurectomy, and labyrinthectomy) can be considered.

Vestibular neuronitis

Vestibular neuronitis is an inflammation of the vestibular nerve, presumably of viral origin that results in an acute vestibular dysfunction. It is characterised by a rapid onset of severe rotatory vertigo with nausea, vomiting, and severe imbalance lasting days. There are no other otological symptoms. It commonly follows an episode of flu. The involved ear has a decreased caloric response. The vertigo usually lasts for days, and the patient may experience unsteadiness that can last up to 3 months.²⁹ Treatment includes vestibular sedatives for a few days during the acute phase. Long-term use of vestibular sedatives is not recommended as it prevents central compensation and slows recovery.^{30,31} Patients should be encouraged to mobilise. If central compensation is incomplete, the patient may have recurrent transient giddiness during rapid head movements. Vestibular rehabilitation could speed recovery and was shown to improve symptoms in up to 80% of patients.³²⁻³⁴

Acute suppurative labyrinthitis and perilymph fistula

Two uncommon but important to recognise peripheral disorders are acute suppurative labyrinthitis and perilymph fistula.

Acute suppurative labyrinthitis is a severe bacterial infection of inner ear. Typically the patient has severe vertigo, hearing loss, and ear discharge. To control acute symptoms and the disease, vestibular

TABLE 3. Characteristics of common causes of dizziness*

Cause	Type of dizziness	Clinical characteristics	Treatment
BPPV	Vertigo, lasting seconds	Episodic vertigo on lying down or looking up, without hearing loss Positive Dix-Hallpike test	Canalith repositioning manoeuvre
Meniere's disease	Vertigo, minutes to hours	Episodic vertigo associated with hearing loss, tinnitus, or aural fullness	Vestibular sedative, low-salt diet, diuretics, vasodilator, intratympanic gentamicin, surgery
Vestibular neuritis	Vertigo, hours to days	Vertigo without hearing loss	Vestibular sedative in acute phase, vestibular rehabilitation
Hyperventilation	Lightheadedness	Associated with perioral or limb numbness; reproduce on hyperventilation	Rebreathing into paper bag, treat underlying psychiatric problem
Orthostatic hypotension	Pre-syncope	SBP decrease >20 mm Hg, DBP decrease >10 mm Hg, or pulse increase of 30 bpm	Review medication; fludrocortisone, midodrine in severe cases
Cardiovascular	Pre-syncope	Exertional chest pain, palpitation	Need cardiovascular assessment
Vestibular migraine	Vertigo	Episodic vertigo with migrainous aura or headache	Migraine prophylaxis
Peripheral neuropathy	Disequilibrium	Decreased extremities sensation	Treatment of underlying cause
Labyrinthitis	Vertigo	With hearing loss and ear discharge	Treat infection, vestibular sedative
Perilymph fistula	Vertigo	Episodic vertigo with hearing loss, fistula sign positive	Surgical repair, bed rest
Cerebrovascular disorder	Vertigo	Persistent vertigo with other neurological signs	Need neurological assessment
Disequilibrium of ageing	Disequilibrium	Multi-sensory deficits	Walking aid, vestibular rehabilitation

* BPPV denotes benign paroxysmal positional vertigo, SBP systolic blood pressure, DBP diastolic blood pressure, and bpm beats per minute

sedatives and antibiotic should be given. More importantly, these patients should have an early ENT assessment as surgical treatment of any underlying cholesteatoma or chronic suppurative otitis media may be indicated.

Perilymph fistula is a violation of the barrier between the middle and the inner ear. It occurs most commonly at the round or oval windows, which are the weakest areas of the bony labyrinth. Typically, the vertigo presents after direct trauma or barotrauma. It can also result from a cholesteatoma or previous ear surgery. There may be fluctuating hearing loss and episodic attacks of vertigo. These patients require urgent ENT referral and surgical repair of the fistula may be needed to preserve the hearing.

Physical examination

Physical examination does not make the diagnosis but merely confirms it. Otoscopy should be performed to look for chronic suppurative otitis media, cholesteatoma or otitis media with effusion. A positive fistula sign suggests a perilymph fistula or superior canal dehiscence. Nystagmus should be checked for. Peripheral nystagmus may be horizontal or torsional, and can be suppressed with visual fixation. Pure vertical nystagmus suggests a central cause.³⁰ Frenzel glasses or video nystagmography can be used to eliminate visual fixation, making nystagmus

more prominent. Cranial nerves and cerebellar signs should be checked. More specialised tests (Romberg/sharpened Romberg, Unterberger/Fukuda stepping, the Dix-Hallpike manoeuvre, head thrust) as well as evaluation for head-shake nystagmus or dynamic visual acuity can be helpful depending on the diagnosis. General examination should include cardiovascular and neurological assessments, as well as evaluation for orthostatic hypotension.

A number of other vestibular tests are available to further evaluation, eg audiometry, electronystagmography or video-nystagmography, posturography, rotatory chair, and vestibular-evoked myogenic potential. These tests are not discussed here due to the scope of this article.

Conclusion

Due to the numerous possible causes, patients with vertigo present a diagnostic challenge. Characteristics of some of the common causes of dizziness are summarised in Table 3. The key to arriving at the diagnosis is to differentiate vertigo from other causes of dizziness or imbalance and to distinguish central from peripheral causes of vertigo. An accurate diagnosis is essential in life-threatening causes. Appropriate treatment can significantly improve the quality of life in patients suffering from vertigo.

References

- Karatas M. Central vertigo and dizziness: epidemiology, differential diagnosis, and common causes. *Neurologist* 2008;14:355-64.
- Hanley K, O'Dowd T, Considine N. A systematic review of vertigo in primary care. *Br J Gen Pract* 2001;51:666-71.
- Newman-Toker DE, Hsieh YH, Camargo CA Jr, Pelletier AJ, Butchy GT, Edlow JA. Spectrum of dizziness visits to US emergency departments: cross-sectional analysis from a nationally representative sample. *Mayo Clin Proc* 2008;83:765-75.
- Kroenke K, Hoffman RM, Einstadter D. How common are various causes of dizziness? A critical review. *South Med J* 2000;93:160-7; quiz 168.
- Drachman DA. A 69-year-old man with chronic dizziness. *JAMA* 1998;280:2111-8.
- Post RE, Dickerson LM. Dizziness: a diagnostic approach. *Am Fam Physician* 2010;82:361-8, 369.
- Ruckenstein MJ, Staab J. Chronic subjective dizziness. *Otolaryngol Clin North Am* 2009;42:71-7, ix.
- Staab JP, Ruckenstein MJ. Expanding the differential diagnosis of chronic dizziness. *Arch Otolaryngol Head Neck Surg* 2007;133:170-6.
- Gupta V, Lipsitz LA. Orthostatic hypotension in the elderly: diagnosis and treatment. *Am J Med* 2007;120:841-7.
- Rauch SD, Velazquez-Villaseñor L, Dimitri PS, Merchant SN. Decreasing hair cell counts in aging humans. *Ann NY Acad Sci* 2001;942:220-7.
- Walther LE, Westhofen M. Presbyvertio-aging of otoconia and vestibular sensory cells. *J Vestib Res* 2007;17:89-92.
- Hirvonen TP, Aalto H, Pyykkö I, Juhola M, Jäntti P. Changes in vestibulo-ocular reflex of elderly people. *Acta Otolaryngol Suppl* 1997;529:108-10.
- Halmagyi GM. Diagnosis and management of vertigo. *Clin Med* 2005;5:159-65.
- Tracis S, Zoruddu GF, Zecca MT, Cau T, Solinas MA, Masuri R. Evaluating patients with vertigo: bedside examination. *Neurol Sci* 2004;24 Suppl:S16-9.
- Labuguen RH. Initial evaluation of vertigo. *Am Fam Physician* 2006;73:244-51.
- Kentala E, Rauch SD. A practical assessment algorithm for diagnosis of dizziness. *Otolaryngol Head Neck Surg* 2003;128:54-9.
- Furman JM, Cass SP. Benign paroxysmal positional vertigo. *N Engl J Med* 1999;341:1590-6.
- Mandalà M, Santoro GP, Awrey J, Nuti D. Vestibular neuritis: recurrence and incidence of secondary benign paroxysmal positional vertigo. *Acta Otolaryngol* 2010;130:565-7.
- Bhattacharyya N, Baugh RF, Orvidas L, et al. Clinical practice guideline: benign paroxysmal positional vertigo. *Otolaryngol Head Neck Surg* 2008;139(5 Suppl 4):S47-81.
- Fife TD, Iverson DJ, Lempert T, et al. Practice parameter: therapies for benign paroxysmal positional vertigo (an evidence-based review): report of the Quality Standards Subcommittee of the American Academy of Neurology. *Neurology* 2008;70:2067-74.
- Hilton MP, Pinder DK. The Epley (canalith repositioning) manoeuvre for benign paroxysmal positional vertigo. *Cochrane Database Syst Rev* 2010;(9):CD003162.
- Semaan MT, Megerian CA. Ménière's disease: a challenging and relentless disorder. *Otolaryngol Clin North Am* 2011;44:383-403, ix.
- Coelho DH, Lalwani AK. Medical management of Ménière's disease. *Laryngoscope* 2008;118:1099-108.
- House JW, Doherty JK, Fisher LM, Derebery MJ, Berliner KI. Meniere's disease: prevalence of contralateral ear involvement. *Otol Neurotol* 2006;27:355-61.
- James AL, Thorp MA. Ménière's disease. *Clin Evid (Online)* 2007; pii: 0505.
- Burgess A, Kundu S. Diuretics for Ménière's disease or syndrome. *Cochrane Database Syst Rev* 2010;(4):CD003599.
- James A, Burton MJ. Betahistine for Ménière's disease or syndrome. *Cochrane Database Syst Rev* 2011;(3):CD001873.
- Diamond C, O'Connell DA, Hornig JD, Liu R. Systematic review of intratympanic gentamicin in Meniere's disease. *J Otolaryngol* 2003;32:351-61.
- Baloh RW. Clinical practice. Vestibular neuritis. *N Engl J Med* 2003;348:1027-32.
- Baloh RW. Vertigo. *Lancet* 1998;352:1841-6.
- Grup C, Gleeson M, Rudge P. The inner ear and the neurologist. *J Neurol Neurosurg Psychiatry* 2007;78:114-22.
- Hillier SL, Hollohan V. Vestibular rehabilitation for unilateral peripheral vestibular dysfunction. *Cochrane Database Syst Rev* 2011;(2):CD005397.
- Venosa AR, Bittar RS. Vestibular rehabilitation exercises in acute vertigo. *Laryngoscope* 2007;117:1482-7.
- Strupp M, Arbusow V, Maag KP, Gall C, Brandt T. Vestibular exercises improve central vestibulospinal compensation after vestibular neuritis. *Neurology* 1998;51:838-44.