

Using bevacizumab in the fight against malignant glioma: first results in Asian patients

Jenny KS Pu 浦勤孫
Raymond TT Chan 陳子棠
Gloria KB Ng 吳嫻寶
Gilberto KK Leung 梁嘉傑
KN Hung 洪君毅
CF Fung 馮正輝

- Objectives** To investigate the efficacy and safety profile of bevacizumab in combination with irinotecan in Hong Kong Chinese patients with recurrent malignant glioma and to determine whether their response differed from that reported in other populations.
- Design** Retrospective study.
- Setting** Two private clinics and a public hospital in Hong Kong.
- Patients** Fourteen individuals who presented with recurrent glioma presenting to the hospital between November 2005 and November 2009.
- Intervention** Salvage therapy with bevacizumab (10 mg/kg) and irinotecan (125 mg/m² [340 mg/m² for those taking enzyme-inducing antiepileptic drugs]) on a 14-day schedule.
- Results** A radiological response was observed in 12 (86%) of the patients, four (33%) of whom had a complete response. The median progression-free survival was 6 (range, 1-15) months; 71% remained progression-free at 6 months. The median overall survival was 18 (range, 9-61) months. The most common adverse events during the bevacizumab and irinotecan treatment period were haematological; five patients had grade 2/3 adverse events. Pulmonary embolism occurred in two patients, one of whom died. Intracranial haemorrhage was not detected in any of the 14 treated patients.
- Conclusions** Bevacizumab plus irinotecan was at least as effective at treating Chinese patients with recurrent glioma as previously reported in clinical trials in different patient populations.

New knowledge added by this study

- This is the first report on the efficacy and safety of bevacizumab in Asian patients with recurrent malignant gliomas.

Implications for clinical practice or policy

- Use of bevacizumab and irinotecan in combination may be a feasible treatment option for Asian patients with recurrent malignant gliomas.

Key words

Antineoplastic combined chemotherapy protocols; Brain neoplasms; Glioblastoma; Neoplasm recurrence, local; Treatment outcome

Hong Kong Med J 2011;17:274-9

Department of Surgery, Li Ka Shing
Faculty of Medicine, University of
Hong Kong, Queen Mary Hospital, 102
Pokfulam Road, Hong Kong

JKS Pu, FRCS(SN)(Edin), FHKAM (Surgery)

GKB Ng, BSc, MPH

GKK Leung, MB, BS, MS

KN Hung, FRCS (Edin), FHKAM (Surgery)

Room 1205-6, Argyle Centre 1,

Mongkok, Hong Kong

RTT Chan, FRCR, FHKAM (Radiology)

Room 1705, Grand Centre, 8 Humphreys

Avenue, Tsimshatsui, Hong Kong

CF Fung, FRCS (Edin, Glasg), FHKAM (Surgery)

Correspondence to: Dr JSK Pu

Email: ksipu@hkucc.hku.hk

Introduction

According to an ad-hoc survey of neurosurgical centres in Hong Kong carried out by the author with the assistance of The Hong Kong Neurosurgical Society, around 70 patients with high-grade malignant glioma (World Health Organization [WHO] grade III and IV) were seen by local neurosurgeons in the year July 2008 to July 2009. This gives an annual incidence of around 1 per 100 000 inhabitants. The most frequently encountered glioma subtype was glioblastoma multiforme (GBM), which constituted 5% of all brain tumours encountered in Hong Kong. Prognosis for patients with recurrent GBM is poor; the typical response rate to chemotherapy alone is 5 to 10% and yields a 6-month progression-free survival (PFS) of 10 to 24%.¹ Surgery is commonly the initial therapeutic approach and aims to debulk the lesion and obtain a tissue diagnosis.² In Hong Kong, the Stupp regimen³ has been widely adopted for post-surgical treatment of newly diagnosed malignant glioma. However, a standard therapeutic paradigm has yet to be established for recurrent malignant gliomas.² Several recent publications report the use of the anti-vascular endothelial growth factor (VEGF) monoclonal antibody bevacizumab as a treatment for malignant glioma.⁴⁻¹² The potential for therapeutic benefit from using it in this disease is promising, as GBM tumours have been shown to secrete substantial amounts of VEGF in comparison to other tumour types.¹³ In phase II studies, bevacizumab administered as a single agent to patients

with recurrent GBM demonstrated objective benefits for a clinically meaningful duration (4-6 months).^{5,6} Based upon that data, single-agent bevacizumab has been approved by the Food and Drug Administration and the Hong Kong Department of Health for the treatment for recurrent GBM.

Response to temozolomide in patients with recurrent glioma is generally poor; in a phase II trial of continuous dose-intense use in patients with recurrent GBMs and anaplastic gliomas, 6-month PFS rates were 24% and 36%, respectively.¹⁴ In a study of Chinese patients with recurrent malignant gliomas in which 13 had GBMs and 9 had anaplastic gliomas, 6-month PFS rates with temozolomide treatment were 21% and 46%, respectively, and the mean PFS for all glioma subtypes was 7 months.¹⁵ These data indicate that response to treatment in patients with recurrent gliomas was similar regardless of ethnicity. Although clinical data on treatment responses to bevacizumab in Chinese patients with recurrent glioma are scarce; a subgroup analysis of 198 Chinese patients with non-small-cell lung cancer enrolled in the SAiL trial gave similar median times to progression (TTP) and median overall survival (OS) values when compared to other populations; respective values for TTP were 8.8 vs 7.8 months, and for OS were 18.5 vs 15.3 months.¹⁶ The safety profile of bevacizumab plus chemotherapy in the Chinese population was consistent with that reported in the global SAiL population,¹⁷ the E4599¹⁸ and AVAiL trials.¹⁹ These data indicated that favourable clinical responses to bevacizumab might also be encountered in Chinese patients. Therefore, the objective of this paper was to review our local experience of bevacizumab as an adjuvant treatment in recurrent malignant glioma in Chinese patients, and how it compared to previous studies in the global population. To our knowledge, this is the first article to examine the use of bevacizumab in Asian patients with glioma.

Methods

Between November 2005 and November 2009, 14 Hong Kong Chinese patients presenting with recurrent glioma at three centres (two private clinics and a public hospital) were treated with bevacizumab plus irinotecan. Bevacizumab was approved for use as a single agent in patients with relapsed GBM by the Department of Health in Hong Kong in September 2009. These patients received salvage therapy with bevacizumab plus irinotecan, as an off-label drug, prior to this approval. Ethics committee approval was obtained from the University of Hong Kong for this treatment strategy and all patients provided written informed consent before receiving bevacizumab.

Histological classification of high-grade malignant gliomas was performed according to the WHO brain tumour classification system.²⁰ Patients

貝伐單抗治療惡性腦膠質瘤： 亞洲病人的初步結果

目的 研究使用貝伐單抗 (bevacizumab) 聯合伊立替康 (irinotecan) 治療惡性腦膠質瘤復發的華籍患者的療效和安全性，以及研究他們的治療反應是否與其他國家的患者不同。

設計 回顧研究。

安排 香港其中兩間私立醫院及一間公立醫院。

患者 2005年11月至2009年11月期間因復發性腦膠質瘤到醫院求診的14名患者。

介入治療 連續14天使用貝伐單抗 (10 mg/kg) 及伊立替康 (125 mg/m² [正服用酶誘導抗癲癇藥物的病人的劑量為340 mg/m²]) 的搶救治療。

結果 12名 (86%) 患者對治療有影像學的反應，其中4名 (33%) 有完全緩解跡象。無惡化生存期中位數為6個月 (介乎1至15個月)；有71%患者在治療後的6個月內未有惡化。總存活率中位數為18個月 (介乎9至61個月)。治療期間最普遍的不良事件均與血液學有關；5名患者出現不良事件的嚴重程度達2/3級。兩名患者出現肺動脈栓塞，其中一人死亡。14名患者均未有發現顱內出血。

結論 本研究結果顯示使用貝伐單抗聯合伊立替康治療惡性腦膠質瘤復發的華籍患者，其療效與其他國家文獻中報告的病人相若。

underwent resection and their cranial lesions were confirmed to be high-grade malignant gliomas by a certified pathologist. Patients received radiotherapy and chemotherapy after surgery. Bevacizumab and irinotecan were administered until disease progression or discontinuation due to complications, according to a schedule adapted from Vredenburgh et al.¹¹ Bevacizumab (10 mg/kg) and irinotecan (125 mg/m² [dose modified to 340 mg/m² for those taking enzyme-inducing antiepileptic drugs]) were both administered as an intravenous (IV) infusion on day 1 of a 14-day schedule. Irinotecan was administered intravenously (>90 minutes) before IV bevacizumab (>30 minutes).

Post-contrast-enhanced magnetic resonance imaging (MRI) reports before surgery, post-surgery, after initial treatment and during treatment with bevacizumab and irinotecan were evaluated, and the exact tumour size was recorded according to the Response Evaluation Criteria in Solid Tumours (RECIST) criteria.²¹ Additional information from other imaging sequences including T2-weighted fast-spin echo and axial T2 fluid-attenuated inversion recovery (FLAIR) were taken into account when evaluating the response to bevacizumab and irinotecan. Radiologists who reviewed the images were all blinded to clinical outcomes. Response assessment was performed using MRI scans. Due to the retrospective nature of

Table 1. Patient characteristics at baseline

Patient characteristic	No. of patients (n=14)
Median (range) age (years)	50 (18-69)
Sex (male/female)	11/3
Histology	
Glioblastoma multiforme	11
Anaplastic astrocytoma	1
Anaplastic oligodendroglioma	1
Anaplastic oligoastrocytoma	1
Tumour location	
Eloquent cortex	13
Non-eloquent area	8
MGMT* methylation status	
Positive	2
Negative	8
Unknown	3
Prior salvage treatment	
Surgery	14
1 Procedure	5
2 Procedures	6
≥3 Procedures	3
Prior chemotherapy	
Stupp regimen (completed)	12 (3)
Procarbazine, CCNU and vincristine	4
Residual disease at commencement of bevacizumab therapy	
Minimal	2

* MGMT denotes O-methylguanine DNA methyltransferase

the study, assessment frequencies differed between patients but ranged from 4 to 10 weeks. Once the response category was determined (according to RECIST criteria), a confirmatory MRI scan was performed 4 to 6 weeks later.

Survival analyses were conducted using life tables and survival plots. The endpoints evaluated were the 6-month PFS, the overall response rate (ORR) and OS. Adverse events (AEs) were recorded and graded according to the National Cancer Institute (NCI) Common Terminology Criteria for Adverse Events version 3.0 (CTCAE). Any laboratory result anomaly fulfilling the criteria for a serious AE was also documented.

Results

At diagnosis, multifocal tumours were present in nine patients, there being a total of 21 tumours in the 14 patients; 13 tumours were located in eloquent areas and 8 in non-eloquent areas. Relevant demographic and clinical characteristics of these 14 patients are shown in Table 1, none of whom were lost to follow-up. At the time of receiving bevacizumab and irinotecan, two of the five patients with a single tumour had minimal residual disease, and three had gross residual disease. All nine patients with multifocal tumours were classified as having gross residual disease as it was not possible to remove all tumour tissue in one operation (Table 1).

Radiological resolution was observed in 12 patients giving an ORR of 86%; of these four had a complete response rate of 29%. The response rates for all 14 patients and the GBM subgroup are given in Table 2; corresponding survival analyses are shown in the Figure. Median PFS was 6 (range, 1-15) months with 71% remaining progression-free at 6 months. Median OS was 18 (range, 9-61) months. Subgroup analysis of GBM patients (n=11) yielded a median PFS of 6 (range, 1-15) months, with a 6-month PFS rate of 64%. Median OS for patients with GBM was 17 (range, 9-38) months.

The most commonly observed AEs during salvage therapy with bevacizumab plus irinotecan were haematological, with five of the patients enduring grade 2/3 AEs according to CTCAE. Pulmonary embolism occurred in two patients, one of whom was fatal. Other common bevacizumab-related side-effects such as hypertension and proteinuria were also noted (Table 3). Intracranial haemorrhage was not detected in any of the 14 treated patients.

Discussion

Bevacizumab in Asian patients

Previous data in metastatic/recurrent²² or previously untreated cancers¹⁹ have shown that bevacizumab

Table 2. Response of treatment

	All patients (n=14)*	Glioblastoma multiforme (n=11)*
Overall response rate	12 (86)	9 (82)
Complete response	4 (29)	3 (27)
Partial response	8 (57)	6 (55)
Stable disease	0	0
Progressive disease	1 (7)	1 (9)
Unknown	1 (7)	1 (9)
Median progression-free survival (months)	6.0	6.0

* Data are shown as No. (%) of patients, except otherwise indicated

Table 3. Most commonly observed adverse events during the bevacizumab and irinotecan treatment period

Adverse event	No. of patients (n=14)
Haematological complication	5
Pulmonary embolism	2
Hypertension	2
Proteinuria	2

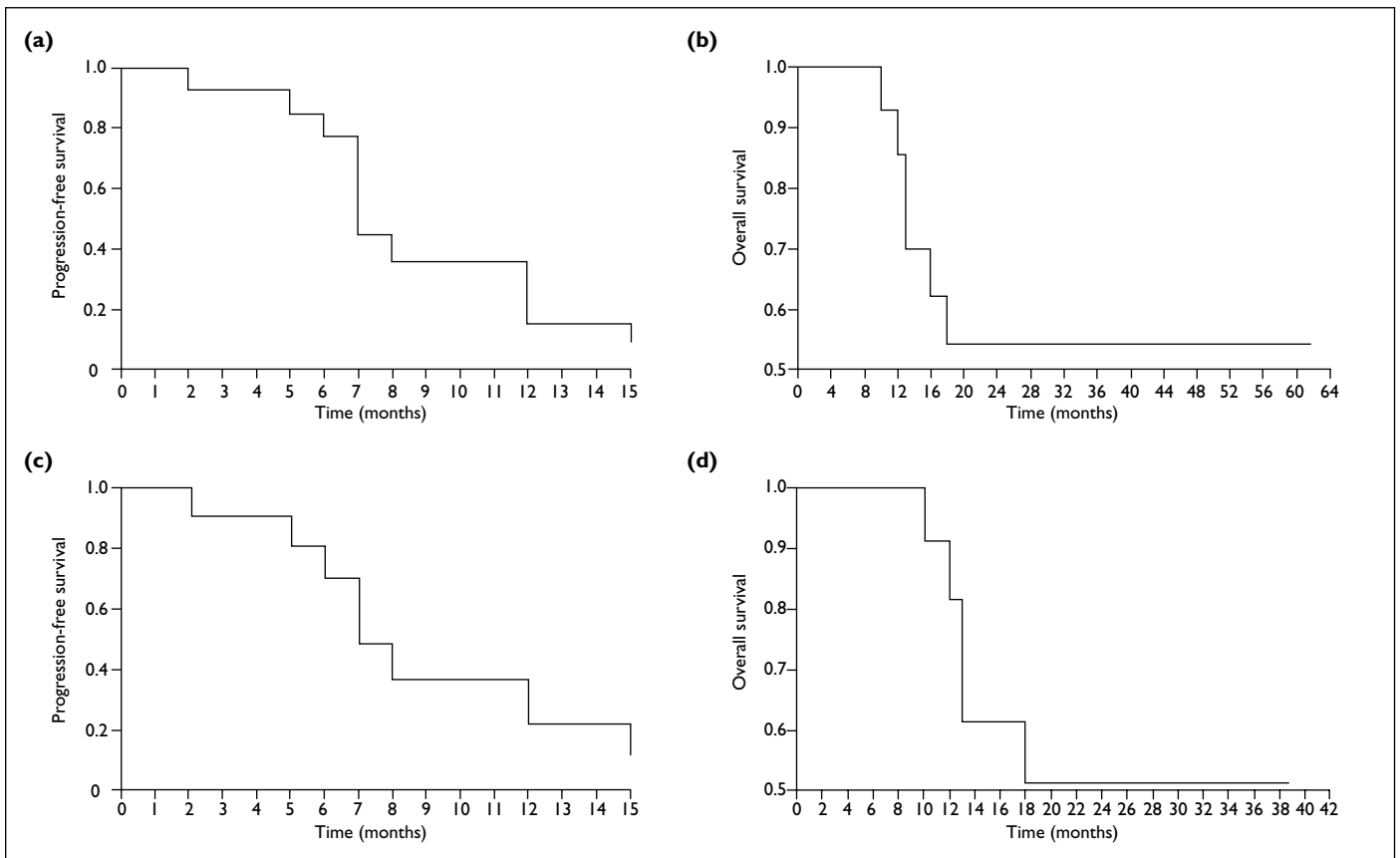


FIG. Survival analyses with Kaplan-Meier methods

(a) Progression-free survival and (b) overall survival in all patients, and (c) progression-free survival and (d) overall survival in patients with glioblastoma multiforme

is well-tolerated in Asians and that there is no racial difference in the pharmacokinetics of this drug. This current case series reports the first use of bevacizumab in Asian patients with glioma and shows that good objective responses were achieved. The 6-month PFS observed in our series was comparable to previously published data on this condition from elsewhere.^{5,11}

Bevacizumab in recurrent gliomas

A pioneering study of bevacizumab in combination with irinotecan was the first to demonstrate a remarkable radiological response using contrast-enhanced MRI in patients with recurrent malignant gliomas.¹⁰ In that series of 29 patients, the combination was well-tolerated and efficacious; 66% of those treated achieved a partial radiological response. These results were confirmed by a second small series of 14 patients²³ and a retrospective review of data on 55 others with recurrent glioma.⁸ In the 14-patient case series, the ORR as assessed by MRI was 50%, all responses being partial.²³ The retrospective review of 55 patients found that 2% of the patients

achieved complete response, 32% achieved partial response, 30% had a minimal response, and 30% had stable disease (no change); the 6-month PFS and OS rates were 39% and 65%, respectively.⁸ The ORR of 86% in our patients was comparable to these data and indicated that ethnicity had no bearing on responsiveness to bevacizumab in patients with recurrent malignant glioma. The current case series had too few patients to allow robust comparison of PFS and OS data, although it does appear that responses in the Chinese patients are comparable to those reported in the populations.

Bevacizumab in recurrent glioblastoma multiforme

Recurrent GBM is associated with a dismal prognosis, with a 6-month PFS rate of 15% to 21% and a median survival of 25 weeks.¹ In patients with relapsed GBM, current standard care with temozolomide has yielded a 6-month PFS of 21%, but with bevacizumab the response is more favourable with 6-month PFS rates of 32 to 64%.^{7,9,12} A significant breakthrough in the treatment of recurrent GBM came with the publication of Vredenburgh et al's phase II prospective trial of

bevacizumab and irinotecan (n=35).¹¹ Such study reported a 6-month PFS rate of 46% and a 6-month OS rate of 77%, whilst 57% of the patients achieved at least a partial response. Later studies validated the efficacy and safety of single-agent bevacizumab in recurrent GBM. A report of an industry-sponsored phase II trial randomising 163 patients to treatment with either bevacizumab alone (n=84) or in combination with irinotecan (n=79) did not show any statistical difference between the arms.⁴ Whereas, in patients with recurrent GB, a phase II study of single-agent bevacizumab followed by bevacizumab plus irinotecan at tumour progression conducted by the NCI, the former resulted in significant biologic and anti-glioma activity.⁶ These findings were confirmed in a large multicentre randomised non-comparative phase II study, in which 167 patients with recurrent GBM were randomised to either bevacizumab alone or in combination with irinotecan.⁵ The randomised design of this trial was intended to prevent bias in treatment assignment and no formal comparison of the two arms was planned. However, with bevacizumab alone or in combination with irinotecan, the ORR was 28% and 38%, respectively, and corresponding 6-month PFS rates were 43% and 50%, whilst median PFS and OS rates were 4 and 9 months as opposed to 6 and 9 months. In addition, bevacizumab as a single agent was associated with fewer discontinuations due to AEs.⁵ Subgroup analyses within our cohort found that the median PFS and 6-month PFS rate for the 11 patients with GBM were 6 months and 64%, respectively. Such findings compared favourably with the results discussed above and indicated that bevacizumab was a good treatment option for Chinese patients with recurrent GBM, the median OS for such patients being 17 months. As our estimate was based on a small number of patients, it should not be considered as robust. Nevertheless, the OS rate in our series was consistent with previously reported figures from two larger trials (with >80 patients) that both yielded median OS rates of 9 months,^{4,5} and from three smaller case series (each involving <40 patients) that yielded medians ranging from 7 to 12 months.^{9,11,12}

Assessment of response to bevacizumab therapy

When assessing the response in malignant glioma patients, bevacizumab's mechanism of

action presents a problem.²⁴ The drug targets neovasculature, inhibiting regrowth.²⁵ As it also normalises surviving tumour vasculature, it helps reduce cerebral oedema (caused by seepage from abnormal vessels).²⁶ Thus, responses obtained from conventional imaging according to Modified Macdonald's Criteria appeared very significant,²⁷⁻²⁹ and is known as a 'pseudoresponse', which may in part explain the lack of a significant increase in survival despite the apparent response to anti-angiogenic therapy.²⁹ A recent update to the Macdonald criteria³⁰ has suggested that, given the limitations of two-dimensional tumour assessments, volumetric tumour assessments may offer a more accurate measurement of lesions, though this may be difficult to achieve in routine clinical use and even in clinical trials involving treatment of brain tumours.²⁴ The observation of linear changes in T2- or FLAIR-weighted MRI sequences (as employed in our case series) has been determined to be the best current method of assessing response in high-grade gliomas.²⁴

Conclusions

Salvage therapy with bevacizumab plus irinotecan appeared to be an effective treatment option in Hong Kong Chinese patients with recurrent malignant gliomas, and yielded a favourable 6-month PFS rate. Despite advances in the Macdonald criteria for malignant glioma, a number of questions still remain and the development of new techniques for assessment as well as investigations into the mechanisms of resistance may improve our ability to assess responses and treat those who develop cancers resistant to anti-angiogenic therapy.

Declaration

No conflicts of interest were declared by the authors.

Acknowledgements

No financial support was provided for the design, undertaking or interpretation of this case series and all content represents the authors' opinions. Preparation of the first draft of the manuscript was completed by Dr J Pu; technical editing was provided by Dr Rachel Edwards of Prism Ideas Ltd., and was supported by a grant from Roche Hong Kong Ltd.

References

1. Wong ET, Hess KR, Gleason MJ, et al. Outcomes and prognostic factors in recurrent glioma patients enrolled onto phase II clinical trials. *J Clin Oncol* 1999;17:2572-8.
2. Stupp R, Roila F; ESMO Guidelines Working Group. Malignant glioma: ESMO clinical recommendations for diagnosis, treatment and follow-up. *Ann Oncol* 2008;19 Suppl 2:ii83-5.
3. Stupp R, Hegi ME, Mason WP, et al. Effects of radiotherapy with concomitant and adjuvant temozolomide versus radiotherapy alone on survival in glioblastoma in a

- randomised phase III study: 5-year analysis of the EORTC-NCIC trial. *Lancet Oncol* 2009;10:459-66.
4. Cloughesy TF, Prados MD, Wen PY, et al. A phase II, randomized, non-comparative clinical trial of the effect of bevacizumab (BV) alone or in combination with irinotecan (CPT) on 6-month progression free survival (PFS6) in recurrent, treatment-refractory glioblastoma (GBM) [abstract 2010b]. *J Clin Oncol* 2008;26:S15.
 5. Friedman HS, Prados MD, Wen PY, et al. Bevacizumab alone and in combination with irinotecan in recurrent glioblastoma. *J Clin Oncol* 2009;27:4733-40.
 6. Kreisl TN, Kim L, Moore K, et al. Phase II trial of single-agent bevacizumab followed by bevacizumab plus irinotecan at tumor progression in recurrent glioblastoma. *J Clin Oncol* 2009;27:740-5.
 7. Nghiemphu PL, Liu W, Lee Y, et al. Bevacizumab and chemotherapy for recurrent glioblastoma: a single-institution experience. *Neurology* 2009;72:1217-22.
 8. Norden AD, Young GS, Setayesh K, et al. Bevacizumab for recurrent malignant gliomas: efficacy, toxicity, and patterns of recurrence. *Neurology* 2008;70:779-87.
 9. Poulsen HS, Grunnet K, Sorensen M, et al. Bevacizumab plus irinotecan in the treatment patients with progressive recurrent malignant brain tumours. *Acta Oncol* 2009;48:52-8.
 10. Stark-Vance V. Bevacizumab and CPT-11 in the treatment of relapsed malignant glioma (abstract 342). *Neuro-Oncology* 2005;7:S3.
 11. Vredenburgh JJ, Desjardins A, Herndon JE 2nd, et al. Bevacizumab plus irinotecan in recurrent glioblastoma multiforme. *J Clin Oncol* 2007;25:4722-9.
 12. Zuniga RM, Torcuator R, Jain R, et al. Efficacy, safety and patterns of response and recurrence in patients with recurrent high-grade gliomas treated with bevacizumab plus irinotecan. *J Neurooncol* 2009;91:329-36.
 13. Takano S, Yoshii Y, Kondo S, et al. Concentration of vascular endothelial growth factor in the serum and tumor tissue of brain tumor patients. *Cancer Res* 1996;56:2185-90.
 14. Perry JR, Bélanger K, Mason WP, et al. Phase II trial of continuous dose-intense temozolomide in recurrent malignant glioma: RESCUE study. *J Clin Oncol* 2010;28:2051-7.
 15. Chan DT, Poon WS, Chan YL, Ng HK. Temozolomide in the treatment of recurrent malignant glioma in Chinese patients. *Hong Kong Med J* 2005;11:452-6.
 16. Wu YL, Zhou C, Jiang G, et al. First-line bevacizumab plus chemotherapy in Chinese patients with advanced or recurrent nonsquamous NSCLC: subanalysis of SAiL (MO19390). *Proceedings of the 20th Asia Pacific Cancer Conference*; 2009 Nov 12-14; Tsukuba, Japan.
 17. Dansin E, Tsai CM, Pavlakis N, et al. Safety and efficacy of first-line bevacizumab-based therapy in advanced non-small cell lung cancer (NSCLC): results of the SAiL study (MO19390) [abstract 9168]. *Eur J Cancer* 2009;7(Suppl):2S.
 18. Sandler A, Gray R, Perry MC, et al. Paclitaxel-carboplatin alone or with bevacizumab for non-small-cell lung cancer. *N Engl J Med* 2006;355:2542-50.
 19. Reck M, von Pawel J, Zatloukal P, et al. Phase III trial of cisplatin plus gemcitabine with either placebo or bevacizumab as first-line therapy for nonsquamous non-small-cell lung cancer: AVAiL. *J Clin Oncol* 2009;27:1227-34.
 20. Louis DN, Ohgaki H, Wiestler OD, Cavenee WK, editors. *WHO classification of tumours of the central nervous system*. Geneva: WHO; 2007.
 21. Therasse P, Arbuck SG, Eisenhauer EA, et al. New guidelines to evaluate the response to treatment in solid tumors. European Organization for Research and Treatment of Cancer, National Cancer Institute of the United States, National Cancer Institute of Canada. *J Natl Cancer Inst* 2000;92:205-16.
 22. Wu JY, Wu XN, Ding L, et al. Phase I safety and pharmacokinetic study of bevacizumab in Chinese patients with advanced cancer. *Chin Med J* 2010;123:901-6.
 23. Pope WB, Lai A, Nghiemphu P, Mischel P, Cloughesy TF. MRI in patients with high-grade gliomas treated with bevacizumab and chemotherapy. *Neurology* 2006;66:1258-60.
 24. Shah GD, Kesari S, Xu R, et al. Comparison of linear and volumetric criteria in assessing tumor response in adult high-grade gliomas. *Neuro Oncol* 2006;8:38-46.
 25. Gerber HP, Ferrara N. Pharmacology and pharmacodynamics of bevacizumab as monotherapy or in combination with cytotoxic therapy in preclinical studies. *Cancer Res* 2005;65:671-80.
 26. Chamberlain MC, Raizer J. Antiangiogenic therapy for high-grade gliomas. *CNS Neurol Disord Drug Targets* 2009;8:184-94.
 27. Macdonald DR, Cascino TL, Schold SC Jr, Cairncross JG. Response criteria for phase II studies of supratentorial malignant glioma. *J Clin Oncol* 1990;8:1277-80.
 28. Sorensen AG, Batchelor TT, Wen PY, Zhang WT, Jain RK. Response criteria for glioma. *Nat Clin Prac Oncol* 2008;5:634-44.
 29. van den Bent MJ, Vogelbaum MA, Wen PY, Macdonald DR, Chang SM. End point assessment in gliomas: novel treatments limit usefulness of classical Macdonald's Criteria. *J Clin Oncol* 2009;27:2905-8.
 30. Wen PY, Macdonald DR, Reardon DA, et al. Updated response assessment criteria for high-grade gliomas: response assessment in neuro-oncology working group. *J Clin Oncol* 2010;28:1963-72.