

Surgical management of primary non-small-cell carcinoma of lung with synchronous solitary brain metastasis: local experience

CK Lo 勞卓堅
CH Yu 余志雄
CC Ma 馬燦忠
KM Ko 高啟明
Samuel CL Leung 梁昌倫

- Objective** To report the surgical experience in the management of patients with synchronous primary lung cancer and solitary brain metastasis.
- Design** Retrospective cohort study.
- Setting** Regional hospital, Hong Kong.
- Patients** Seventeen patients with synchronous primary lung cancer and solitary brain metastasis were treated by pulmonary resection and neurosurgical intervention between 1994 and 2007.
- Results** Median patient survival was 52 months (95% confidence interval, 9-95 months) and the 5-year survival was 27%. The univariate analysis yielded no significant prognostic factor. Four out of six patients who had lymph node metastases developed tumour recurrence.
- Conclusion** In view of encouraging survival results, aggressive therapy including pulmonary resection and neurosurgical intervention should be recommended for patients with synchronous presentation with primary lung cancer and solitary brain metastasis.

Introduction

The prognosis of primary lung cancer is poor because metastases develop early in the subclinical stage. The brain is one of the most common sites of metastases. About 25 to 30% of patients develop brain metastases during the course of the disease and at autopsy the prevalence is up to 60%.¹ Neurological symptoms due to peri-lesional cerebral oedema can be relieved rapidly by corticosteroids but median survival is usually less than 3 months.² Depending on the size and site of the lesion, it can also be treated by surgical resection, or stereotactic radiosurgery (SRS). Yet the prognosis remains poor with a median survival of less than 6 to 8 months.^{3,4} A unique group of the patients has solitary brain metastasis and capacity for longer survival if the brain metastases can be removed completely.⁵⁻⁷ For synchronous tumour, the question arises as to whether to also treat the lung primary aggressively. There is a belief that patients with solitary synchronous brain metastasis have poorer survival than those with metachronous brain metastases. Under such circumstances, pulmonary resection is thought to be palliative in nature. However, pulmonary resection is usually not justified since the lung primary is relatively less symptomatic than the brain metastasis, and pulmonary symptoms can be controlled by non-surgical therapy. Patients are usually treated with thoracic radiation, chemotherapy, or a combination of both but long-term survival is seldom achieved. In the last 10 years, there have been a few reports about survival benefit, and even 5-year survival after aggressive combined thoracic resection and neurosurgical therapy for patients with synchronous lung primary and a solitary brain metastasis. So combined aggressive therapy for synchronous solitary brain metastasis from lung primary is no longer considered palliative. In this report, we describe our experience of combined pulmonary resection and neurosurgical therapy for patients with synchronous primary lung non-small-cell carcinoma and a solitary brain metastasis.

Methods

From January 1994 to December 2007, 17 patients (3 female and 14 male) had curative pulmonary resections for primary lung non-small-cell carcinomas and curative neurosurgical interventions for synchronous solitary brain metastases. Synchronous

Key words

Brain neoplasms; Carcinoma, non-small-cell lung; Lung neoplasms; Survival rate

Hong Kong Med J 2010;16:186-91

Queen Elizabeth Hospital, Kowloon,
Hong Kong:
Department of Cardiothoracic Surgery

CK Lo, MB, BS, FHKAM (Surgery)

CC Ma, MB, BS, FHKAM (Surgery)

KM Ko, MB, BS

Department of Neurosurgery

CH Yu, MB, ChB, MRCS (Edin)

SCL Leung, MB, BS, FHKAM (Surgery)

Correspondence to: Dr CH Yu
Email: yuchihung@hotmail.com

tumour was defined as simultaneous diagnosis of both lung primary and brain secondary within 1 month. Solitary metastasis was defined as a single brain metastasis representing the sole extra-thoracic metastasis revealed by computed tomography (CT) of the whole body, bone scan, magnetic resonance imaging (MRI) of the brain, and/or positron emission tomography (PET). Curative neurosurgical resection was defined as gross complete removal of the brain metastasis by means of craniotomy, or SRS. The precise neurosurgical intervention depended on the size, the anatomical site, and the potential for neurological effects after removal of the lesion. Our policy was to carry out neurosurgical intervention first to achieve early symptomatic relief. Subsequently, patients underwent further assessment, including tumour staging and cardiopulmonary assessment to determine whether they were suitable candidates for pulmonary resection. Staging procedures included whole body CT, bone scan, MRI brain, PET scan, and if necessary, mediastinoscopy. Pulmonary resection was not offered to those with multiple brain metastases, extra-cranial distant metastases, regional lymph node metastases, inadequate cardiopulmonary reserve, or poor Karnofsky performance status (KPS, <90). Curative pulmonary resection was defined as no involvement of bronchial, vascular, and parenchymal margins. Such patients also underwent whole brain irradiation therapy before or after pulmonary resection. All relevant hospital and out-patient clinical records were reviewed. Statistical analysis was carried out using the Statistical Package for the Social Sciences (Windows version 16.0; SPSS Inc, Chicago [IL], US). The survival interval was defined as the interval between the last date of the operation and the date of death or last clinic visit. Survival was calculated by the Kaplan-Meier method. Any P value of less than 0.05 was considered statistically significant.

Results

The mean age of the entire cohort was 58 (range, 37-77) years. Fifteen (88%) patients had neurological symptoms including: hemiparesis (n=7), headache (n=5), diplopia (n=2), seizure (n=2), and confusion (n=1); two of them had multiple neurological symptoms. Only two (12%) patients had respiratory symptoms, and one had neither respiratory nor neurological symptoms. Nine (53%) patients had brain MRI scans before their neurosurgical intervention in addition to CT. Only 11 patients had PET, as such scanning was not available before 2001.

All but one patient had their neurological intervention before the pulmonary resection, as relief of neurological symptoms was considered more urgent. Brain metastases were found in the frontal lobes (n=9), parietal lobes (n=3), occipital

lobes (n=2), cerebellum (n=1), pons (n=1), and thalamus (n=1). Craniotomy and complete removal was performed in 14 patients (Fig 1), and all the specimens were confirmed to be metastases from lung. Three patients received SRS. The median interval between the neurological intervention and pulmonary resection was 40 (range, 8-97) days. Pneumonectomy was performed in one patient, wedge resection with an adequate margin in one (Fig 2), and lobectomy in 15 patients. The most common histological type was adenocarcinoma (n=15; 88%). One patient had a squamous cell carcinoma and one an adenosquamous carcinoma. Lymph node metastases were found in six (35%) patients, which included mediastinal lymph nodes (N2) in one patient and hilar/lobar lymph nodes (N1) in five patients. There was no mortality or morbidity after the neurosurgical interventions. One patient died 14 days after lobectomy due to pneumonia, one had a persistent air leak, and one had an infection of the thoracotomy wound. Sixteen patients received whole brain radiation therapy, and one received mediastinal irradiation for mediastinal N2 nodal involvement. No patient received chemotherapy. The characteristics of these patients are summarised in Table 1.

Follow-up was complete in 16 patients; the median follow-up being 13 (range, 4-68) months. Eleven patients had tumour recurrence, including in the brain (n=9), lungs (n=1), and at multiple sites (n=1). Seven of them died of cancer progression during follow-up, and five were alive without overt disease. The median survival to date was 52 (95% confidence interval, 9-95) months. The overall 1-year, 2-year, and 5-year survivals were: 63%, 54%, and 27%, respectively. The univariate analysis yielded

非小細胞肺癌併單發性腦轉移的外科治療： 本地經驗

- 目的** 報告為原發性肺癌及單發性腦轉移病人進行外科手術的經驗。
- 設計** 隊列式回顧研究。
- 安排** 香港一所地區醫院。
- 患者** 1994年至2007年期間，共17名患有原發性肺癌及單發性腦轉移，並接受肺切除及神經干預的病人。
- 結果** 病人的生存期中位數為52個月（95%置信區間：9至95個月），5年生存率為27%。單元分析未能發現任何明顯的預後因子。6位患有淋巴結轉移的病人中，有4位出現腫瘤復發。
- 結論** 本研究的生存率令人鼓舞。醫生應考慮為患有原發性肺癌及單發性腦轉移的病人進行包括肺切除及神經干預的積極療法。

TABLE 1. Patient characteristics*

Patient No.	Sex	Age (years)	Neurology	Magnetic resonance image of brain	Site of brain metastasis
1	M	37	Yes	Yes	Parietal
2	M	40	Yes	Yes	Frontal
3	F	44	Yes	-	Parietal
4	M	45	Yes	-	Frontal
5	M	49	Yes	Yes	Frontal
6	M	50	Yes	-	Frontal
7	M	52	Yes	Yes	Frontal
8	M	59	-	Yes	Frontal
9	F	61	Yes	-	Occipital
10	M	64	Yes	Yes	Frontal
11	M	65	Yes	Yes	Parietal
12	M	65	Yes	-	Frontal
13	M	68	Yes	Yes	Frontal
14	M	69	Yes	Yes	Pontine
15	M	70	Yes	-	Cerebellum
16	M	75	Yes	-	Occipital
17	F	77	-	-	Thalamus

* Patient 7 had a large cell carcinoma and patient 15 had an adenosquamous carcinoma; all others had adenocarcinoma

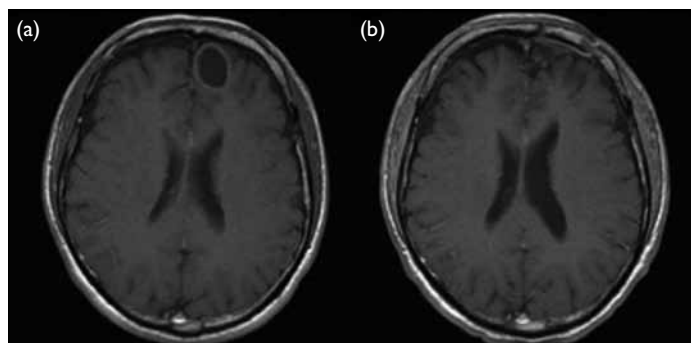


FIG 1. Contrast magnetic resonance brain images of patient 8 (a) before and (b) after craniotomy

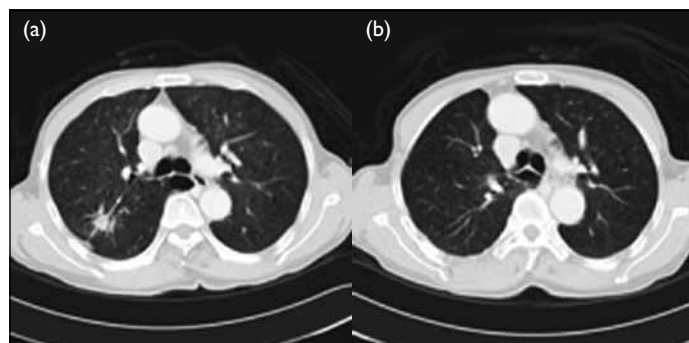


FIG 2. Contrast computed tomographic thorax images of patient 8 (a) before and (b) after lobectomy

TABLE 2. Surgical results of combined management for synchronous solitary brain metastasis and primary lung cancer^{1,11,12,16-19}

Author	Year	No.	Therapy for brain metastasis	5-Year survival (%)	Median survival (months)	Poor prognostic factors
Torre et al ¹⁶	1988	27	Craniotomy	15	26	Lymph node metastasis
Burt et al ¹⁷	1992	65	Craniotomy	16	21	Incomplete resection
Billing et al ¹	2001	28*	Craniotomy	21	24	Lymph node metastasis
Bonnette et al ¹⁸	2001	103 [†]	Craniotomy	11	12.4	Non-adenocarcinoma
Granone et al ¹⁹	2001	20	Craniotomy	-	23	Non-adenocarcinoma and lymph node metastasis
Flannery et al ¹²	2008	26 [‡]	SRS [§]	35	26.4	Karnofsky performance status
Yang et al ¹¹	2008	16	SRS	56	64.9	-
Current study	2008	17	Craniotomy and SRS	27	52	-

* Two patients had two brain metastases

[†] Four patients had multiple brain metastases

[‡] Had pulmonary resections, or radiation therapy for lung primary

[§] SRS denotes stereotactic radiosurgery

Neurosurgical intervention	Pulmonary resection	TNM stage	Survival interval (months)	Status	Site of recurrence
Craniotomy	Lobectomy	T2N1	52.1	Cancer death	Brain
Craniotomy	Lobectomy	T2N0	62.4	Alive	-
Craniotomy	Pneumonectomy	T2N2	6.9	Cancer death	Brain and liver
Craniotomy	Lobectomy	T2N0	12.6	Alive	Brain
Craniotomy	Lobectomy	T2N1	7.2	Alive	-
Craniotomy	Lobectomy	T2N1	-	Operative death	-
Craniotomy	Wedge resection	T1N0	24.4	Alive	-
Craniotomy	Lobectomy	T2N0	4.5	Alive	-
Craniotomy	Lobectomy	T2N1	12.8	Cancer death	Brain
Craniotomy	Lobectomy	T2N0	12.2	Alive	Liver and bone
Stereotactic radiosurgery	Lobectomy	T2N0	20.4	Alive	-
Craniotomy	Lobectomy	T1N1	28.1	Alive	Brain
Craniotomy	Lobectomy	T1N0	20.4	Alive	Lungs
Stereotactic radiosurgery	Lobectomy	T2N0	9.1	Cancer death	Brain
Craniotomy	Lobectomy	T1N0	3.9	Cancer death	Brain
Craniotomy	Lobectomy	T2N0	13.4	Cancer death	Brain
Stereotactic radiosurgery	Lobectomy	T2N0	17.3	Cancer death	Brain

no significant prognostic factor. Of six patients who had lymph node metastases, four developed tumour recurrence, but this did not attain statistical significance in terms of survival ($P=0.282$). Neither gender ($P=0.254$), age ($P=0.312$), histology ($P=0.269$), nor degree of differentiation ($P=0.415$) affected survival. Seven out of eight patients who had preoperative CT had brain recurrence, but only two out of nine who had preoperative MRI had brain recurrence. Whether or not patients had a preoperative MRI brain scan did not affect survival.

Discussion

Without any treatment, the median survival of patients with brain metastases from primary lung cancer was less than a few months. For solitary brain metastasis, survival can be improved after craniotomy and complete removal.⁵ In randomised trials, survival after craniotomy and whole brain radiation therapy was significantly better than brain radiotherapy alone.⁸⁻¹⁰ Recently, SRS was reported to be an alternative to the craniotomy, especially for the management of patients with small or deep lesions. Apart from being less invasive and having less morbidity than open surgery, the local tumour control rate was consistently greater than 85%, and survival was comparable to that with open surgery.^{11,12}

For patients presenting with a synchronous solitary brain metastasis, however, clinicians face a dilemma with regard to treatment of the thoracic primary. Patients with a solitary synchronous brain metastasis have shorter survival than those with

metachronous metastases, if both are treated only with neurosurgical resection.¹ Some clinicians consider synchronous presentation as a prognostic factor for poor outcomes.¹³ Therefore, pulmonary resection was seldom performed, owing to its invasive nature, uncertain survival benefit, and paucity of pulmonary symptoms. Alternatively, patients received thoracic radiation, chemotherapy, or both. Although the prognosis was better than those not receiving any thoracic therapy (overall survival, 15.5 vs 5.9 months; $P=0.046$), it was nevertheless poor.^{14,15} This lead clinicians to evaluate the role of surgery for the thoracic primary. A few case series showed a survival benefit after aggressive combined neurosurgical and pulmonary resections. The reported mean overall survival ranged from 12 to 65 months (Table 2).^{1,11,12,16-19} Flannery et al¹² demonstrated that patients who underwent definitive thoracic therapy (either pulmonary resection or thoracic radiation therapy) had better survival than those not receiving any thoracic therapy (5-year actuarial overall survival being 36% vs 0%, $P<0.001$). Based on multivariate analysis, they also noted that definitive thoracic therapy was one of the prognostic factors ($P=0.020$). In a retrospective case-control study, patients having both SRS and pulmonary resection survived significantly longer than those having SRS alone (mean survival, 65 vs 18 months; $P<0.001$).¹¹ Thus, in the presence of encouraging survival results, combined thoracic resection and neurosurgical intervention for synchronous lung primary and brain metastasis appeared justified. In our study, the median survival till latest follow-up

was 52 months and the 5-year survival rate was 27%. These results appear comparable to other series reporting on combined surgical resection of both lesions in patients presenting synchronously with a lung primary and a brain metastasis.

Intra-thoracic lymph node metastases, non-adenocarcinoma histology, and poor performance status were reported to be prognosticators of poor outcomes.^{1,12,16-19} We could not demonstrate any prognostic factor in our series, possibly because of the small number of patients. There was no long-term survival among patients with lymph node metastasis; the 5-year survival in those without and with such metastases being 35% and 0%, respectively ($P=0.001$).^{1,16,19} We intended to offer pulmonary resection to those who had clinical N0 disease. Patients with clinical evidence of lymph node metastases were not recruited for pulmonary resection. As mediastinoscopy is not a routine procedure in our centre, a majority of the patients (64%) had pre-pulmonary resection PET for mediastinal staging. Patients with radiological evidence of lymph node metastasis were excluded from having pulmonary resections or subjected to mediastinoscopy. Hence, all six patients with lymph node metastases could be regarded as having reached a certain subclinical stage. This may explain why lymph node metastases did not figure as significant in the univariate analysis. Moreover, almost all of our patients had adenocarcinoma.

In our study, there were selection biases. Patients with inadequate cardiopulmonary reserve or poor performance status did not undergo pulmonary resection. Karnofsky performance status was reported to be one of the prognostic factors,

and none of patients with a KPS of less than 90 survived more than 5 years after receiving combined definitive brain and pulmonary therapy for the lung primary and solitary brain metastasis.¹² From a study of 271 patients having brain surgery for solitary brain metastasis from various primaries, Tendulkar et al²⁰ reported that the survival of patients with higher KPS scores was better than those with lower scores. Thus, pulmonary resection is not recommended for persons with a poor performance status. In our series, the rate of local brain tumour recurrence was high. Only 59% of our patients had undergone MRI before neurological intervention, indicating that brain CT underestimates the extent of intra-cranial metastasis and that diagnostic accuracy is poorer than with MRI.²¹ We believe that brain metastasis may escape detection with initial CT. Recently we have recommended that all patients undergo aggressive staging, based on imaging that includes both brain MRI and PET. In our series, we failed to identify any specific prognostic factor, possibly because our patients were carefully selected according to strict selection criteria.

In conclusion, aggressive combined modality treatment—including neurosurgical resection (Fig 1)/SRS, whole brain irradiation therapy, and pulmonary resection (Fig 2)—should be recommended for patients presenting synchronously with a lung primary and solitary brain metastasis, provided they have a good performance status and no clinical evidence of intra-thoracic nodal metastases. A synchronous solitary brain metastasis is not common enough to mount a large-scale study. Hence, a multi-institutional trial is necessary to further evaluate this problem.

References

1. Billing PS, Miller DL, Allen MS, Deschamps C, Trastek VF, Pairolero PC. Surgical treatment of primary lung cancer with synchronous brain metastases. *J Thorac Cardiovasc Surg* 2001;122:548-53.
2. Horton J, Baxter DH, Olson DB. The management of metastases to the brain by irradiation and corticosteroids. *Am J Roentgenol Radium Ther Nucl Med* 1971;111:334-6.
3. Posner JB. Management of central nervous system metastases. *Semin Oncol* 1977;4:81-91.
4. Penel N, Brichet A, Prevost B, et al. Prognostic factors of synchronous brain metastases from lung cancer. *Lung Cancer* 2001;33:143-54.
5. Albain KS, Crowley JJ, LeBlanc M, Livingston RB. Survival determinants in extensive-stage non-small-cell lung cancer: the Southwest Oncology Group experience. *J Clin Oncol* 1991;9:1618-26.
6. Hankins JR, Miller JE, Salzman M, et al. Surgical management of lung cancer with solitary cerebral metastasis. *Ann Thorac Surg* 1988;46:24-8.
7. Magilligan DJ Jr, Duvernoy C, Malik G, Lewis JW Jr, Knighton R, Ausman JI. Surgical approach to lung cancer with solitary cerebral metastasis: twenty-five years' experience. *Ann Thorac Surg* 1986;42:360-4.
8. Patchell RA, Tibbs PA, Walsh JW, et al. A randomized trial of surgery in the treatment of single metastases to the brain. *N Engl J Med* 1990;322:494-500.
9. Patchell RA, Tibbs PA, Regine WF, et al. Postoperative radiotherapy in the treatment of single metastases to the brain: a randomized trial. *JAMA* 1998;280:1485-9.
10. Vecht CJ, Haaxma-Reiche H, Noordijk EM, et al. Treatment of single brain metastasis: radiotherapy alone or combined with neurosurgery? *Ann Neurol* 1993;33:583-90.
11. Yang SY, Kim DG, Lee SH, et al. Pulmonary resection in patients with nonsmall-cell lung cancer treated with gamma-knife radiosurgery for synchronous brain metastases. *Cancer* 2008;112:1780-6.
12. Flannery TW, Suntharalingam M, Regine WF, et al. Long-term survival in patients with synchronous, solitary brain metastasis from non-small-cell lung cancer treated with radiosurgery. *Int J Radiat Oncol Biol Phys* 2008;72:19-23.
13. Getman V, Devyatko E, Dunkler D, et al. Prognosis of patients with non-small cell lung cancer with isolated brain

- metastases undergoing combined surgical treatment. *Eur J Cardiothorac Surg* 2004;25:1107-13.
14. Ampil F, Caldito G, Milligan S, Mills G, Nanda A. The elderly with synchronous non-small cell lung cancer and solitary brain metastasis: does palliative thoracic radiotherapy have a useful role? *Lung Cancer* 2007;57:60-5.
15. Hu C, Chang EL, Hassenbusch SJ 3rd, et al. Nonsmall cell lung cancer presenting with synchronous solitary brain metastasis. *Cancer* 2006;106:1998-2004.
16. Torre M, Barbieri B, Bera E, et al. Surgical therapy in lung cancer with single brain metastasis. *Eur J Cardiothorac Surg* 1988;2:336-9.
17. Burt M, Wronski M, Arbit E, Galicich JH. Resection of brain metastases from non-small-cell lung carcinoma. Results of therapy. *Memorial Sloan-Kettering Cancer Center Thoracic Surgical Staff. J Thorac Cardiovasc Surg* 1992;103:399-411.
18. Bonnette P, Puyo P, Gabriel C, et al. Surgical management of non-small cell lung cancer with synchronous brain metastases. *Chest* 2001;119:1469-75.
19. Granone P, Margaritora S, D'Andrilli A, Cesario A, Kawamukai K, Meacci E. Non-small cell lung cancer with single brain metastasis: the role of surgical treatment. *Eur J Cardiothorac Surg* 2001;20:361-6.
20. Tendulkar RD, Liu SW, Barnett GH, et al. RPA classification has prognostic significance for surgically resected single brain metastasis. *Int J Radiat Oncol Biol Phys* 2006;66:810-7.
21. Schellinger PD, Meinck HM, Thron A. Diagnostic accuracy of MRI compared to CCT in patients with brain metastases. *J Neurooncol* 1999;44:275-81.