

# Imageless computer navigation in total knee arthroplasty

KW Cheung 張堅穎  
KH Chiu 趙國慶

- Objectives** To study the difference in clinical and radiological outcomes between imageless computer-navigated and the conventional technique for performing total knee arthroplasty.
- Design** Prospective case-control study.
- Setting** University teaching hospital, Hong Kong.
- Patients** Forty-seven patients with imageless computer-navigated total knee arthroplasty were matched with 47 patients with total knee arthroplasty using conventional technique over the period 2003 to 2007.
- Main outcome measures** Postoperative radiological alignment, tourniquet time, Knee Society knee score and functional score, and range of motion.
- Results** The femoral anteroposterior, tibial anteroposterior, overall anteroposterior alignment of the lower limb, and lateral femoral lateral flexion angle had significantly less deviation from neutral alignment in those having computer-assisted total knee arthroplasty than conventional total knee arthroplasty. The former had significantly fewer outliers ( $>3^\circ$  from neutral alignment) than the latter, in both the coronal and sagittal planes of the femoral and tibial sides. The mean tourniquet time was significantly longer in the former (111 minutes) than in those having a conventional arthroplasty (98 minutes). There was no tracker/pin tract complication or wound infection in either group.
- Conclusion** Computer-assisted navigation can give a better alignment than the conventional technique, but the tourniquet time was significantly longer. Computer-assisted navigation surgery can help the surgeon in determining limb alignment during the operation.

## Introduction

Total knee arthroplasty (TKA) with more than  $3^\circ$  of varus alignment was associated with rapid failure and less satisfactory functional outcomes.<sup>1,2</sup> Stulberg et al<sup>3</sup> reported that more than 10% of TKAs performed by experienced surgeons had varus alignments of more than  $3^\circ$  (Fig 1). Computer-assisted orthopaedic surgery (CAOS) has evolved since the late 1990s. It aims to replay the surgical action on a computer in real time, and may improve alignment of the prosthesis. We aimed to study the difference in alignments between the computer-assisted and conventional techniques for TKA.

## Methods

From 2003 to 2007, 47 patients with osteoarthritis of knee had TKA performed with CAOS (CAOS-TKA group). The navigation system used was the Stryker Knee Navigation 3.0. Extra-medullary femoral and tibial guides were used in these patients. This was a prospective, non-randomised study. The results were compared with 47 matched patients having TKA performed using the conventional technique (TKA group). Intra-medullary femoral and extra-medullary femoral guides were used in the TKA group. All patients had cemented posterior stabilised prosthesis (Scorpio PS, Osteonics, Allendale/ NJ/ US) implanted.

The patients all had primary osteoarthritis of knee with no previous history of osteotomy, unicompartmental knee arthroplasty and fractures around the knee. Patients with varus or valgus deformity of more than  $20^\circ$ , flexion contractures of more than  $20^\circ$ ,

### Key words

Arthroplasty, replacement, knee;  
Recovery of function; Surgery, computer-assisted

*Hong Kong Med J* 2009;15:353-8

Department of Orthopaedics and  
Traumatology, The Chinese University of  
Hong Kong, Prince of Wales Hospital,  
Shatin, Hong Kong

KW Cheung, FRCSOrth, FHKAM (Orthopaedic  
Surgery)

KH Chiu, FRCS, FHKAM (Orthopaedic Surgery)

Correspondence to: Dr KW Cheung  
E-mail: kwcheung@ort.cuhk.edu.hk

## 無影像電腦導航全膝關節置換術

**目的** 研究無影像電腦導航及傳統全膝關節置換術的術後臨床及X光片的結果。

**設計** 前瞻性病例對照研究。

**安排** 香港一所大學教學醫院。

**患者** 2003年至2007年期間，47例無影像電腦導航全膝關節置換術跟相配47例傳統全膝關節置換術。

**主要測量結果** 術後X光列線、止血帶使用時間、Knee Society膝關節評分和膝功能評分，以及膝關節的運動範圍。

**結果** 電腦導航全膝關節置換術之股骨前後及側列線、脛骨前後列線，及下肢整體前後列線較傳統膝關節置換術明顯地較少偏離中立位列線。電腦導航全膝關節置換術的界外離異值明顯地較傳統全膝關節置換術為少。電腦導航全膝關節置換術的平均止血帶使用時間為111分鐘，較傳統全膝關節置換術的98分鐘明顯長。兩種技術均沒有追蹤系統釘位骨折及傷口感染。

**結論** 電腦導航全膝關節置換術較傳統全膝關節置換術的術後X光列線為佳。但是，電腦導航全膝關節置換術的止血帶使用時間較傳統方法明顯長。電腦導航系統能輔助骨科醫生於全膝關節置換術從中如何決定最理想的列線。

bone defects treated with bone grafts or metal augmentation were excluded from this study. Severe flexion contracture or severe varus deformity may increase the chance of using a constrained type prosthesis, which requires the use of femoral and tibial intra-medullary rods.<sup>4</sup> These rods could hinder the placement of tracker anchoring pins.

Tracker anchoring pins were inserted into the distal femur and proximal tibia, and incorporated via the same surgical wound. Anatomical landmarks were registered with the computer (Fig 2). The computer generated a model of the knee with a desired mechanical axis of both the tibia and femur (Fig 3a). The surgeon made the bone cut using these pre-determined axes as the guide (Fig 3b). The initial osteotomy plane was checked with the computer and rectified if necessary, and then rechecked with the computer.

Tourniquet time, postoperative range of motion, Knee Society knee scores and functional scores in the two groups were compared.<sup>5</sup> Standard anteroposterior (AP) and lateral views and standing long films were taken for postoperative radiographic evaluation.<sup>6</sup> The postoperative X-ray alignments in both the coronal and sagittal planes in the two groups were compared using the Knee Society Roentgenographic Evaluation and Scoring System.<sup>7</sup> The degree of deviation from neutral alignment in the two groups was compared in the femoral AP plane, the tibial AP plane, the overall AP plane, the

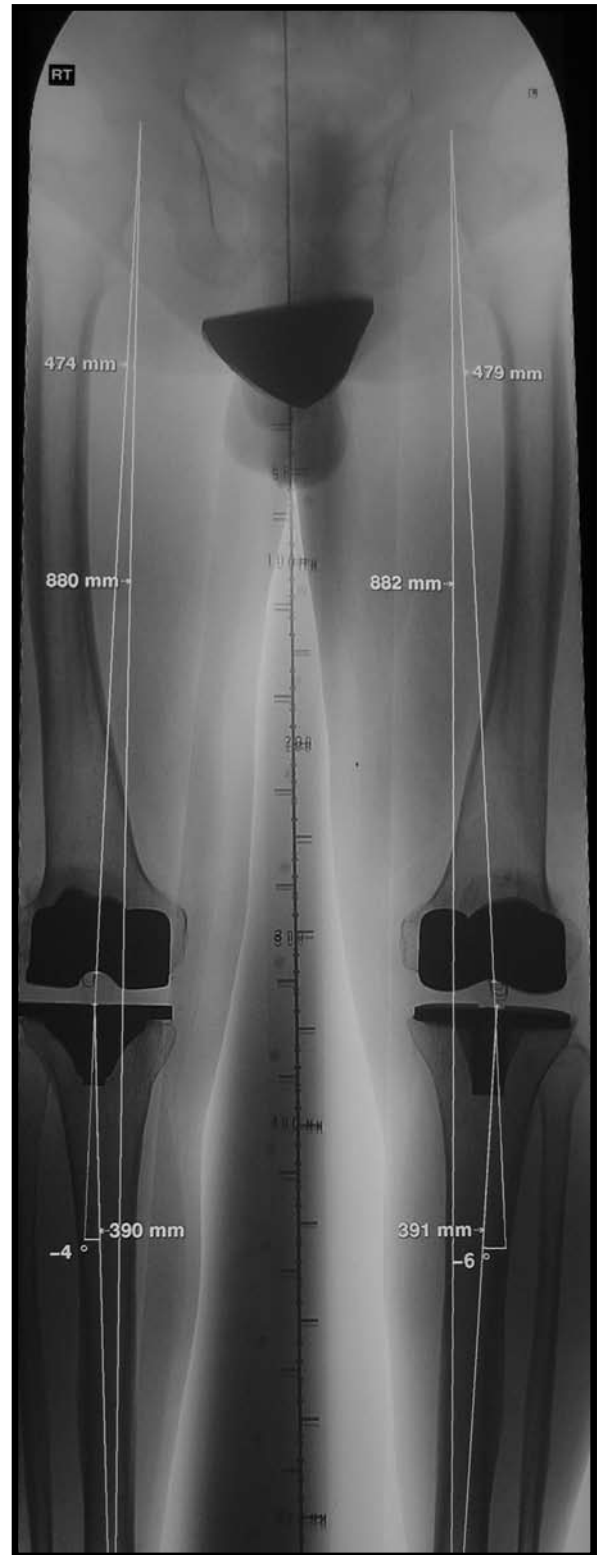


FIG 1. Total knee arthroplasty in varus position

femoral sagittal (lateral) plane and the tibial sagittal plane. Only the absolute value of the deviation from neutral alignment was used for calculation, because the deviation in either direction should not cancel each other out and result in an underestimate of

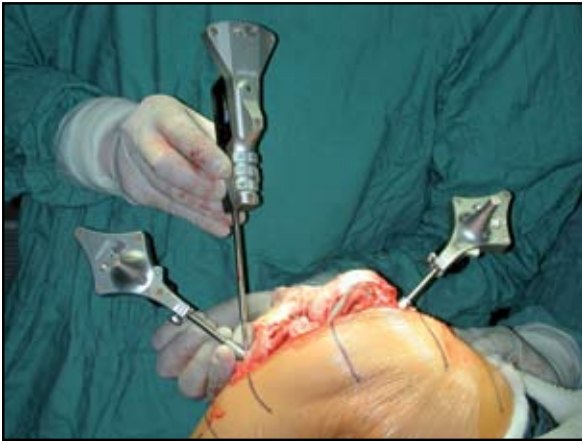

FIG 2. Trackers anchored to the distal femur and proximal tibia and the landmarks registered with the computer

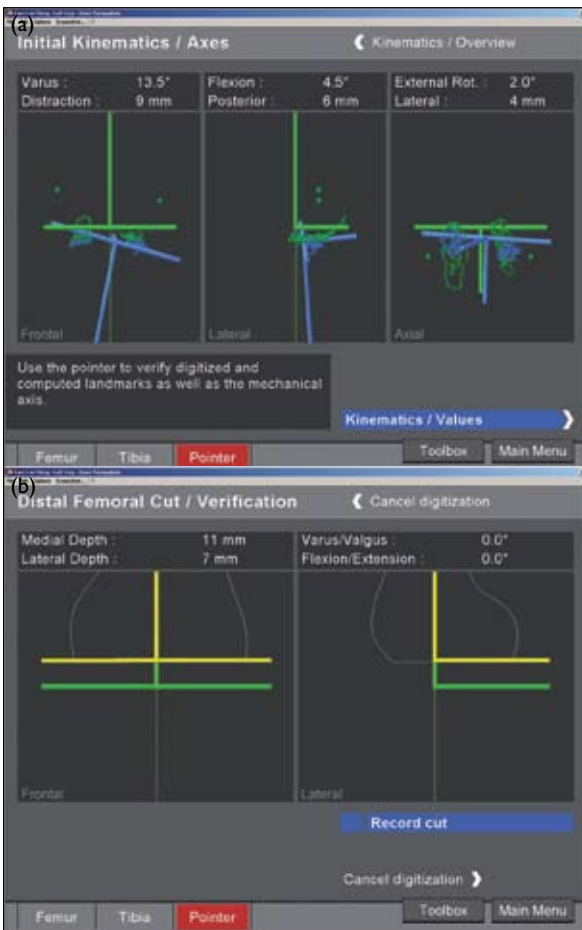


FIG 3. (a) Model generated by the computer after all anatomical landmarks were registered, which showed up the limb deformity and the range of motion of the knee. (b) Bone cut was made with reference to the computer

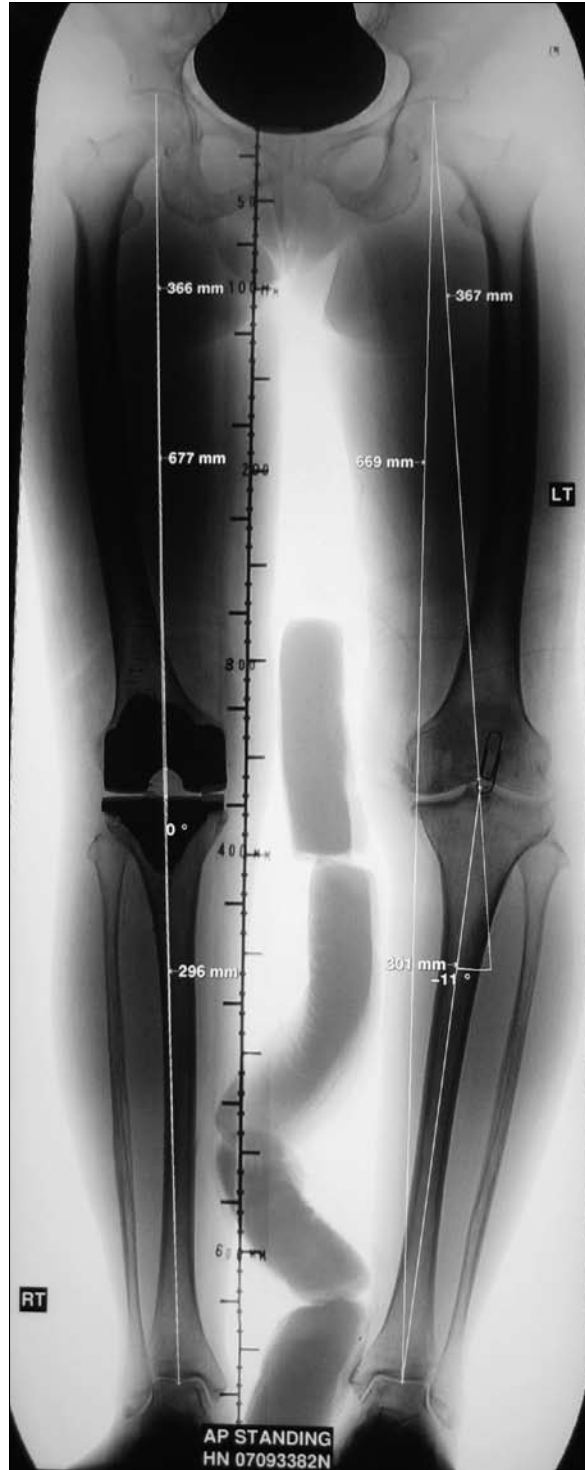

FIG 4. Total knee arthroplasty done with computer-assisted position showing a neutral coronal position

the actual deviation. Deviation of more than 3° from neutral alignment in the coronal and sagittal plane was defined as an outlier. Student's *t* test was

used to test continuous variables, and Fisher's exact test for outliers (categorical variables); a P value of less than 0.05 was set as statistically significant. The Statistical Package for the Social Sciences (Windows version 14.0; SPSS Inc, Chicago [IL], US) was used for analysis.

TABLE. Summary of patients' demographic and clinical data

Demographic/clinical characteristic	Mean (range)*		P value
	CAOS-TKA group	TKA group	
Age (years)	67 (50-79)	67 (52-78)	0.675
Preoperative			
Varus deformities (degrees)	11 (5-20)	11 (5-20)	0.70
Range of motion (degrees)	94 (50-125)	91 (30-120)	0.413
Knee Society knee score	29 (0-61)	29 (0-63)	0.966
Knee Society functional score	45 (5-80)	50 (5-80)	0.128
Tourniquet time (minutes)	111 (59-143)	98 (45-143)	0.003
Postoperative			
Range of motion (degrees)	100 (55-130)	94 (70-125)	0.04
Knee Society knee score	91 (65-100)	89 (69-97)	0.267
Knee Society functional score	67 (45-100)	65 (15-100)	0.581
Deviation in different planes from neutral alignment (degrees)			
Femoral coronal plane (femoral AP <sup>†</sup> plane)	1 (0-3.5)	1.8 (0-6)	0.014
Tibial coronal plane (tibial AP angle)	1.3 (0-5)	2.4 (0-6)	0.001
Overall coronal plane (overall AP plane)	2.3 (0-8)	4.2 (0-10)	<0.001
Femoral sagittal plane (femoral lateral flexion angle)	1.7 (0-10)	3.9 (0-9)	<0.001
Tibial sagittal plane (tibial lateral flexion angle)	1.9 (0-10)	2.2 (0-9)	0.375

\* CAOS-TKA group refers to patients having total knee arthroplasty (TKA) performed with computer-assisted orthopaedic surgery, and TKA group refers to those having TKA performed using the conventional technique

† AP denotes anteroposterior

## Results

There were 41 female and six male patients in each group. The demographic and clinical data pertaining to these patients are summarised in the Table.

The CAOS-TKA group had significantly fewer outliers than in the TKA group in the overall AP plane (21 vs 57%,  $P<0.001$ ; Fig 4), and with respect to the femoral lateral flexion angle (15 vs 55%,  $P<0.001$ ). With respect to the mean deviation in the tibial sagittal plane (tibial lateral flexion angle) from neutral alignment, the CAOS-TKA and TKA groups had 19 and 17% outliers, respectively ( $P=0.789$ ). There were no wound infections and tracker anchoring pin tract fractures in either group.

## Discussion

Computer-assisted TKA was first developed with the incorporation of preoperative computed tomographic (CT) scan images into the computer.<sup>8</sup> Surgeons had to register the anatomical landmarks defined by preoperative CT scans and match them with the computer intra-operatively. This could pose considerable irradiation to the patient and increase the cost of the operation. Imageless computer navigation was subsequently developed, so as to minimise radiation to the patient and costs. Swank<sup>9</sup> and B athis et al<sup>10</sup> found no difference in postoperative radiographic alignment between CT-based and imageless-guided TKA.

Imageless computer-assisted navigation could achieve a significantly better femoral AP alignment, tibial AP alignment, and overall AP alignment of the lower limb and femoral lateral alignment than the conventional TKA technique. There was a fine-tuning cutting jig available, so that the surgeon could make fine adjustments with the help of computer navigation before the bone cut was made (Fig 5). This greatly improved the accuracy of the final bone cut. Surgeons find it difficult to determine three planes (sagittal, coronal, and rotational plane) at the same time; computer navigation can help determine these three planes in the same setting.

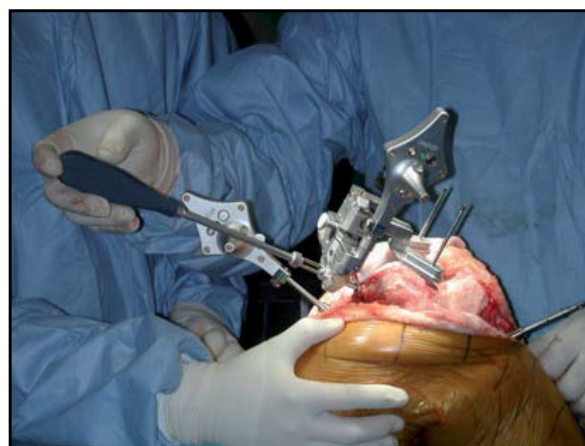


FIG 5. Finely adjustable extra-medullary tibial guide

Engh and Petersen<sup>11</sup> and Elloy et al<sup>12</sup> reported better accuracy with intra-medullary femoral guides than extra-medullary guides. They indicated that it was very difficult to locate the femoral head intra-operatively. The alignment was determined with the help of the computer. The femoral AP angle of the CAOS-TKA group (extra-medullary guide) had significantly less deviation from neutral alignment (1°) than the TKA group, using an intra-medullary guide (1.8°). The extra-medullary femoral guide with computer navigation was more accurate than the intra-medullary guide with the conventional technique. Moreover, the use of intra-medullary guides in TKA was reported to have a higher incidence of fat embolism.<sup>13,14</sup> The more accurate extra-medullary femoral guide in this study therefore can reduce the risk of fat embolism.

The femoral lateral flexion angle was also significantly improved with computer navigation. When using the conventional intra-medullary femoral guide, the pilot hole was determined by the surgeon with reference to an imaginary line along the femoral canal. This had the potential to produce a substantial error. Moreover, there was significant improvement in the deviation from neutral alignment by using computer navigation instead of the conventional technique (from 3.9° to 1.7°).

The tibial plate in the CAOS-TKA and TKA groups showed no significant difference in deviation from neutral alignment in the lateral tibial flexion angle. In both groups, the tibial plate was in a slightly extended position, which might be due to the registration of the mechanical axis of the tibia. If the registration is made too anterior, the tibial plate becomes extended and vice versa.

The results in this series were comparable to that of Sparmann et al's using the same computer navigation machine.<sup>15</sup> They reported that 34% tibial plates were in an extended position. In the current series however, 49% of the tibial plates were in an extended position. Chiu et al<sup>16</sup> reported that the posterior slope of tibia was increased in osteoarthritis of the knee in Chinese patients. This was greater than the normally quoted 5° to 10°.<sup>17,18</sup> The computer used the points mapped by the surgeon and matched them with the pre-stored models to calculate the sagittal mechanical axis of the tibia. The difference in posterior slopes among different racial groups may predispose the tibial plate in some of them to an extended position.

## References

1. Kumar PJ, Dorr LD. Severe malalignment and soft-tissue imbalance in total knee arthroplasty. *Am J Knee Surg* 1997;10:36-41.
2. Wasielewski RC, Galante JO, Leighty RM, Natarajan RN,

Rotational alignment of the tibia and femur were not studied in this series. A postoperative CT scan was necessary to study the final rotational alignment and correlate it with intra-operative findings. This exposed patients to excessive radiation. Moreover, there are controversies regarding the role of navigation in rotational alignment for TKA. Siston et al<sup>19</sup> reported that computer navigation did not provide a more reliable means of femoral alignment than traditional techniques, which was contrary to the claim by Stöckl et al<sup>20</sup> that imageless navigation improved rotational alignment in TKA.

The tourniquet time was significantly longer in the CAOS-TKA group, but the learning curve was quite steep. Surgeons using this technique must be familiar with the conventional TKA and make a judgement intra-operatively, as to whether the data provided by the computer is or is not valid. Moreover, installation of this computer navigation machine increases the cost of the procedure.

Before the advent of imageless computer navigation in TKA, surgeons worried about the accuracy of this technique, as all the landmarks were registered intra-operatively and there appeared to be a potential for error in locating them. Nevertheless, Yau et al<sup>21</sup> reported that there was no significant difference in postoperative alignment between low- and high-volume surgeons using computer navigation for TKA. Thus, computer navigation could produce an equally accurate and in certain respects more accurate alignment than the conventional technique, even by low-volume surgeons. The surgeon still needed to make judgements intra-operatively, as to whether to accept the alignment provided by the computer. Further studies to correlate the intra-operative and postoperative alignment can help elucidate the accuracy of computer navigation in TKA.

The potential space between the saw blade and the cutting jig can create discrepancy between the planned and final resection level and the alignment. Robotic surgery may be a solution to this problem.

## Conclusion

Computer navigation in TKA is a reliable aid for the surgeon to determine the alignment of the prosthesis. However, surgeons need to improve accuracy, and prolonged operating times and the costs of the machine are disadvantages.

- Rosenberg AG. Wear patterns on retrieved polyethylene tibial inserts and their relationship to technical considerations during total knee arthroplasty. *Clin Orthop Relat Res* 1994;299:31-43.

3. Stulberg SD, Loan P, Sarin V. Computer-assisted navigation in total knee replacement: results of an initial experience in thirty-five patients. *J Bone Joint Surg Am* 2002;84-A(Suppl 2):90S-98S.
4. Cheung KW, Yung SH, Chiu KH. Primary total knee replacement using constrained condylar prosthesis in knee with varus deformity. *Hong Kong J Orthop Surg* 2001;6:65-8.
5. Insall JN, Dorr LD, Scott RD, Scott WN. Rationale of the Knee Society clinical rating system. *Clin Orthop* 1989;248:13-4.
6. Carver E, Carver B, Brennan P. Medical imaging techniques, reflection and evaluation. Edinburgh: Churchill Livingstone; 2006: 107-10.
7. Ewald FC. The Knee Society total knee arthroplasty roentgenographic evaluation and scoring system. *Clin Orthop Relat Res* 1989;(248):9-12.
8. Perlick L, Bächis H, Tingart M, Perlick C, Grifka J. Navigation in total-knee arthroplasty: CT-based implantation compared with the conventional technique. *Acta Orthop Scand* 2004;75:464-70.
9. Swank ML. Computer-assisted surgery in total knee arthroplasty: recent advances. *Surg Technol Int* 2004;12:209-13.
10. Bächis H, Perlick L, Tingart M, Lüiring C, Perlick C, Grifka J. Radiological results of image-based and non-image-based computer-assisted total knee arthroplasty. *Int Orthop* 2004;28:87-90.
11. Engh GA, Petersen TL. Comparative experience with intramedullary and extramedullary alignment in total knee arthroplasty. *J Arthroplasty* 1990;5:1-8.
12. Elloy MA, Manning MP, Johnson R. Accuracy of intramedullary alignment in total knee replacement. *J Biomed Eng* 1992;14:363-70.
13. Dorr LD, Merkel C, Mellman MF, Klein I. Fat emboli in bilateral total knee arthroplasty. Predictive factors for neurologic manifestations. *Clin Orthop Relat Res* 1989;248:112-9.
14. Berman AT, Parmet JL, Harding SP, et al. Emboli observed with use of transesophageal echocardiography immediately after tourniquet release during total knee arthroplasty with cement. *J Bone Joint Surg Am* 1998;80:389-96.
15. Sparmann M, Wolke B, Czupalla H, Banzer D, Zink A. Positioning of total knee arthroplasty with and without navigation support. A prospective, randomised study. *J Bone Joint Surg Br* 2003;85:830-5.
16. Chiu KY, Zhang SD, Zhang GH. Posterior slope of tibial plateau in Chinese. *J Arthroplasty* 2000;15:224-7.
17. Kapandji IA. The knee. In: Kapandji IA, editor. *The physiology of the joints*. 5th ed. Vol 2. Edinburgh: Churchill Livingstone; 1987:74.
18. Clarke HD, Scott NW, Insall JN, et al. Anatomy. In: Insall JN, Scott NW, editors. *Surgery of the knee*. 3rd ed. New York: Churchill Livingstone; 2001:19.
19. Siston RA, Patel JJ, Goodman SB, Delp SL, Giori NJ. The variability of femoral rotational alignment in total knee arthroplasty. *J Bone Joint Surg Am* 2005;87:2276-80.
20. Stöckl B, Nogler M, Rosiek R, Fischer M, Krismer M, Kessler O. Navigation improves accuracy of rotational alignment in total knee arthroplasty. *Clin Orthop Rel Res* 2004;(426):180-6.
21. Yau WP, Chiu KY, Zuo JL, Tang WM, Ng TP. Computer navigation did not improve alignment in lower-volume total knee practice. *Clin Orthop Rel Res* 2008;466:935-45.