

# Pantothenate kinase–associated neurodegeneration in two Chinese children: identification of a novel *PANK2* gene mutation

KY Chan 陳國燕  
CW Lam 林青雲  
LP Lee 李麗萍  
SF Tong 湯瑞芳  
YP Yuen 袁月冰

Pantothenate kinase–associated neurodegeneration (formerly Hallervorden-Spatz syndrome), the most prevalent form of neurodegeneration with brain iron accumulation, is a rare degenerative brain disease characterised by predominantly extrapyramidal dysfunction resulting from mutations in the *PANK2* (pantothenate kinase 2) gene. Using DNA mutation analysis, the authors identified a novel missense mutation (P354L) in exon 4 of the *PANK2* gene in an adolescent with classic pantothenate kinase–associated neurodegeneration. DNA-based diagnosis of pantothenate kinase–associated neurodegeneration plays a key role in determination, and can make the diagnosis more simply, directly, and economically because it obviates the need for unnecessary biochemical tests. Once pantothenate kinase–associated neurodegeneration–like symptoms are identified, mutation analysis and target screening for the family of the proband can provide efficient and accurate evidence of pantothenate kinase–associated neurodegeneration inheritance.

## Introduction

Pantothenate kinase–associated neurodegeneration (PKAN) is an autosomal recessive degenerative brain disease characterised by brain iron accumulation due to *PANK2* gene mutation.<sup>1</sup> The *PANK2* gene, located at chromosome 20p13, is responsible for the encoding of the mitochondrial enzyme pantothenate kinase, essential for coenzyme A (CoA) biosynthesis, and fat and carbohydrate metabolism. It is uncertain as to how the lack of functional pantothenate kinase causes the symptoms of PKAN. Recent research has hypothesised that with the decrease in the amount of functional pantothenate kinase, phosphopantothenate falls, resulting in cysteine accumulation in the globus pallidus.<sup>2</sup> Cysteine, itself cytotoxic, will undergo rapid auto-oxidation in the presence of iron, resulting in free radical production causing extensive damage to the basal ganglia, the region of the brain with the highest relative amount of non-heme iron.<sup>3</sup> Conventionally, PKAN is categorised into two types—classic and atypical—by the age of onset, rate of disease progression, clinical and radiological features (Table).<sup>4</sup> Mutations identified to date in the *PANK2* gene include aberrant splicing, missense, and nonsense mutations. Over 100 mutations have been documented worldwide, and the correlation between the types and loci of mutations, and phenotypes of PKAN patients is now being extensively studied.<sup>5,6</sup> We report two children with a clinical diagnosis of Hallervorden-Spatz syndrome, one of whom was found to have a novel missense mutation of the *PANK2* gene.

### Key words

Hallervorden-Spatz syndrome; Iron/metabolism; Mutation, missense; Neurodegenerative diseases; Phosphotransferases (alcohol group acceptor)/genetics

## Case reports

### Case 1

This patient was the second child of non-consanguineous Chinese parents. The antenatal, perinatal, and developmental history was unremarkable. There was no family history of neurological disease. She presented to us at the age of 4.5 years with a 2-year history of frequent falling and a hand tremor. She progressively regressed with increasing generalised dystonia, spasticity, and loss of the ability to talk, stand, walk, and write by the age of 8 years. L-dopa and clonazepam were given with no effect. At the age of 9 years, generalised seizures developed after an episode of hypoxic ischaemic encephalopathy subsequent to cardiac arrest due to sputum retention and choking. She was profoundly handicapped with intractable seizures despite supportive treatment with carbamazepine, clonazepam, and phenobarbital. She had frequent episodes of aspiration pneumonia and subsequently died of septicaemia and acute renal failure at the age of 14 years in 1995. Magnetic resonance imaging (MRI) of the brain done in 1991 when she was 11 years of age reported hypointensity in T1- and T2-weighted images of the globus pallidus, probably due

*Hong Kong Med J* 2008;14:70-3

Princess Margaret Hospital, Laichikok, Kowloon, Hong Kong; Department of Paediatrics and Adolescent Medicine

KY Chan, FRCPC, FHKAM (Paediatrics)

LP Lee, MRCP, FHKAM (Paediatrics)

Department of Pathology

YP Yuen, MB, ChB, FRCPA

Department of Chemical Pathology, The Chinese University of Hong Kong, Prince of Wales Hospital, Shatin, Hong Kong

CW Lam, PhD, FRCPA

SF Tong, MSc

Correspondence to: Dr KY Chan  
E-mail: chanky1@ha.org.hk

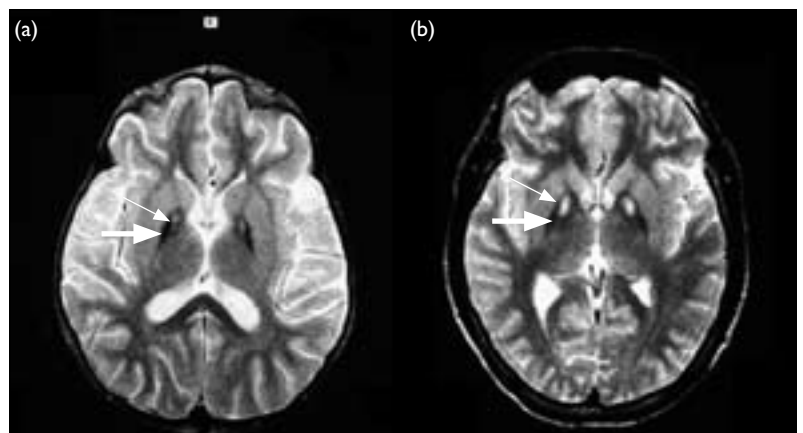
to increased iron deposition (Fig 1a). A retrospective review of the scan in 1995 confirmed the 'eye of the tiger' sign. No molecular studies were available.

**Case 2**

This patient was the third child of non-consanguineous Chinese parents. His developmental history was unremarkable. There was no family history of neurological diseases. His father died from lung cancer at the age of 50 years. He presented at the age of 12 years with a 2-year history of easy falling, tiptoe gait, slurring speech, and clumsiness along with poor handwriting and deterioration in his school performance. Mild upper limb dystonia was found during the initial examination. Investigations including a blood smear, liver and renal function tests, serum copper and ceruloplasmin levels, a lipid profile, serum uric acid, lactate and pyruvate levels; urine amino acids/organic acids were all normal. His cerebrospinal fluid was normal with no elevation in immunoglobulin G and no oligoclonal band. A computed tomographic scan and MRI of the brain were reported as normal. An ophthalmological examination showed no abnormalities. Severe dystonia gradually developed, affecting initially the upper limbs, then the lower limbs, neck, trunk, eyelids, mouth, and larynx in subsequent years. Choreoathetosis of the upper limbs and mouth was also present. Magnetic resonance imaging of the brain was repeated in 1995 when he was 16 years of age and it showed the 'eye of the tiger' sign in the globus pallidus (Fig 1b). A diagnosis of Hallervorden-Spatz disease was made. He was treated with a combination of various drugs including L-dopa, trihexyphenidyl, baclofen, benzodiazepam, and tetrabenazine with very little effect. He refused a therapeutic trial of intrathecal baclofen. At the age of 22 years, his mobility deteriorated rapidly and he became wheelchair-bound. He developed an acute left-sided hemiparesis as a result of cervical cord compression secondary to C4,5 intervertebral disc extrusion<sup>7</sup> so an anterior spinal fusion was performed. At the age

**兩名華裔兒童所患的泛酸激酶相關神經變性：確定一種新發現的*PANK2*基因突變**

泛酸激酶相關神經變性（前稱哈一斯二氏綜合徵），是腦內鐵沉積神經變性病最普遍的形式，也是罕見的退化性腦病，一個十分常見的特徵是由*PANK2*（泛酸激酶2）基因突變而導致的錐體外系功能受損。利用DNA突變分析，本文作者在一名患有經典的泛酸激酶相關神經變性的成年人體內，發現*PANK2*基因外顯子4上一種新的錯義突變。以DNA為基礎的診斷，對確定病人是否患上泛酸激酶相關神經變性具有關鍵作用，使整個診斷更簡單直接而化算，因為它能排除不必要的生化測試。一旦識別出與泛酸激酶相關神經變性相似的症狀，即可對淵源家系進行突變分析和標靶篩查，這兩種方法能針對泛酸激酶相關神經變性遺傳，提供有效率且準確的證據。



**FIG 1.** In case 1 (a) and case 2 (b), the T-2 weighted images of the proband, with the characteristic 'eye of the tiger' sign are shown. A region of hypointensity (thick arrow) is shown with central hyperintensity (thin arrow) in the globus pallidus.

of 24 years, he developed repeated vomiting with gastric distension and later developed a volvulus of the stomach. To relieve this, a gastro-jejunostomy was done in August 2003. Poor feeding and repeated vomiting continued and a barium swallow showed a dilated oesophagus with reduced oesophageal

**TABLE.** Features of classic and atypical pantothenate kinase-associated neurodegeneration (PKAN)

Feature	Classic PKAN	Atypical PKAN
Onset of symptoms	Early, within first decade after birth or early adolescence	Second or third decade after birth
Progression of disease	10 years after onset	15-40 years after onset
Neurological symptoms	Gait abnormalities, extrapyramidal dysfunction such as dystonia and choreoathetosis; corticospinal tract involvement	Speech disorders, extrapyramidal dysfunction such as dystonia and rigidity
Psychiatric disorders	Rare	Depression, personality splits (30% of cases), obtrusive obsessions and compulsions
Retinitis pigmentosa or optic atrophy	Often (68%)	Rare
Magnetic resonance imaging/radiographic evidence	'Eye of the tiger' sign: hypointensity with central hyperintensity in the globus pallidus	'Eye of the tiger' sign: hypointensity with central hyperintensity in the globus pallidus

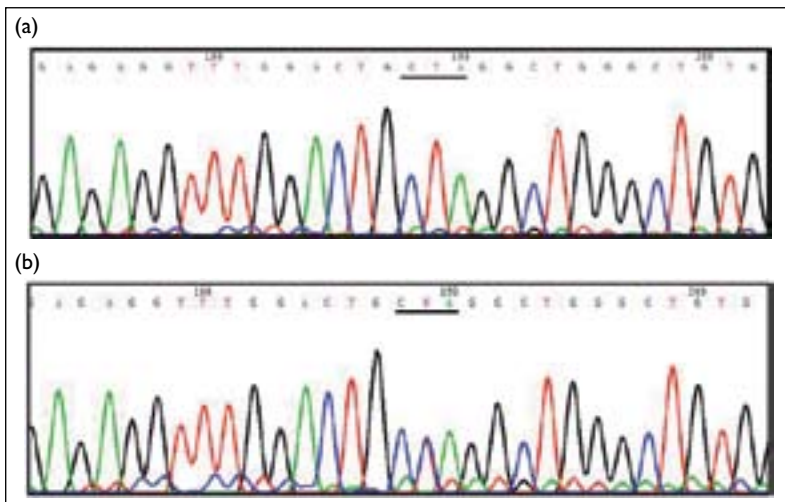


FIG 2. Electropherogram for (a) homozygous c.1391C>T, and (b) heterozygous c.1391C>T

The mutated codon is underlined

peristalsis. The patient died suddenly in November 2003, probably due to acute aspiration. A *PANK2* gene analysis done in 2003 showed a homozygous *PANK2* missense mutation.

Mutational analysis of the *PANK2* gene was performed as described in a previously published report.<sup>8</sup> Sequencing revealed that the proband was homozygous for a novel missense mutation in exon 4 of the *PANK2* gene (Fig 2a). The mutation, c.1391C>T, changed codon 464 of the *PANK2* gene from CCA to CTA. The corresponding amino acid change was P354L according to Zhou et al<sup>1</sup> or P464L according to conventional nomenclature. The amino acid change was a non-conservative change and this mutation was not identified in 100 normal chromosomes using direct DNA sequencing. The mother was heterozygous for c.1391C>T (Fig 2b). Pathogenicity of this mutation can be confirmed by in-situ mutagenesis, in-vivo expression, and functional analysis of the *PANK2* mutant.

## Discussion

Identification of the mutation in the *PANK2* gene of the proband is significant when trying to distinguish between common neurodegeneration with brain iron accumulation (NBIA) and PKAN. The latter is a form of NBIA seen in people with *PANK2* gene mutations. Hayflick et al<sup>9</sup> reported a striking one-to-one correlation between the MRI 'eye of the tiger' sign and the presence and absence of *PANK2* mutations. Baumeister et al,<sup>10</sup> however, found that the 'eye of the tiger' sign may not be a reliable disease marker over the course of the disease in PKAN. In a recent study, Hartig et al<sup>5</sup> also reported no strict correlation between the 'eye of the tiger' sign and

*PANK2* mutations. In case 2, the radiographic finding was not evident until a repeated MRI examination revealed the 'eye-of-the-tiger' sign 4 years after the onset of symptoms. The initially normal MRI finding, coupled with the absence of retinopathy, proves that ophthalmological and radiological signs of PKAN may not be conspicuous during the early stages. Perhaps clinical features are not sufficient for making an accurate diagnosis of PKAN, as people with common NBIA or hypoprebetaproteinaemia, acanthocytosis, retinopathy, pallidal degeneration (HARP) syndrome also display similar neurodegenerative signs and symptoms.<sup>11</sup> In our case, the diagnosis of PKAN could only be made after repeated MRI examinations and was confirmed by the DNA analysis. The HARP syndrome is known to be allelic with PKAN, hence the employment of tests for red blood cell acanthocytosis and serum lipoprotein profiles play a significant role in differentiating between these two diseases.

These two patients had very similar clinical features but differed significantly in the onset of motor dysfunction, the pace of progression, and their severity. Case 1 had a very early onset of symptoms at the age of about 2 years and lost all skills within 6 years. Her disease progressed rapidly and was further complicated by a hypoxic ischaemic brain insult. Case 2 had a later onset of symptoms, at the age of 10 years, with slow progression until the age of 22 years when he developed secondary complications due to severe dystonia.

Dystonia is a common clinical feature among PKAN patients. Its severity compounds the progression of the disease and often causes serious complications. In our cases, the administration of baclofen, trihexyphenidyl, L-dopa and tetrabenazine did not alleviate the dystonia. The patient in case 2 suffered from severe cervical myelopathy 9 years after the onset of symptoms. He also developed a volvulus of the stomach requiring surgical correction, after 12 years. While the myelopathy can be attributed to severe dystonic movements of the neck, no specific reason, or linkage, has been identified for the occurrence of the volvulus of the stomach. Nonetheless, it is worth noting that as the disease progresses, secondary complications varying in severity will appear, probably resulting from extrapyramidal dysfunction, suggesting the need for early detection and more aggressive treatment of complications. Both of our patients died eventually of the complications of neurodegeneration.

Pigmentary degeneration is said to be a common feature of PKAN. However, Egan et al<sup>12</sup> in his report on the neuro-ophthalmologic and electroretinographic (ERG) findings in genetic and neuroimaging confirmed cases of PKAN showed that only four of 10 examined patients had a pigmentary retinopathy, none had optic atrophy and all of them

showed some type of ocular motility disorder related to the tectal mid-brain. Of 16 patients, 11 had abnormal ERGs ranging from mild cone abnormalities to severe rod-cone dysfunction.

Due to the uncertainty surrounding the mechanism governing PKAN, medical treatments have so far only been aimed at palliation of the symptoms. In both our cases, baclofen, trihexyphenidyl and L-dopa were administered to relieve the dystonia, but to no avail. The patients showed no significant improvements and severe dystonia gave rise to feeding problems, repeated aspiration and choking, and even myelopathy and gastric volvulus. Therapies are based on hypotheses of pathogenesis, and potential therapies are aimed at addressing low levels of CoA in mitochondria, oxidative stress, and iron overload. Use of compounds such as phosphopantothenate and fatty acids have been experimented with to increase the CoA levels in mitochondria.<sup>3,13</sup> Possible therapies also include anti-oxidants (idebenone, coenzyme Q, alpha-tocopherol), which are believed to be able to relieve oxidative stress in the basal ganglia and retina. Nonetheless, drugs such as idebenone have been found to enhance superoxide formation and, in cases of atypical PKAN use of these has reportedly led to a worsening of symptoms.<sup>3</sup>

On retrospectively reviewing these cases, we have come up with the following recommendations regarding the diagnosis of PKAN. Vigilance in searching for radiological and ophthalmologic abnormalities is of the utmost importance for diagnosis, although these may be absent during the

early stages. Mutation analysis of the *PANK2* gene should also be done at an early stage in children and adolescents with typical clinical features of PKAN even in the absence of the 'eye of the tiger' sign. Family screening for the heterozygous state and prenatal diagnosis are recommended, as PKAN is a severe mutation-caused adolescent neurodegenerative disease. Finally, to rule out HARP, a full lipid test is recommended to distinguish between suspected cases of PKAN and HARP.

## Conclusion

While it is accepted that PKAN is caused by mutations in the *PANK2* gene, genotype-phenotype correlations have not been established due to the small number of comparable cases. Due to the difficulty in identifying PKAN, it is possible that many cases have either been overlooked or mistakenly classified as common NBIA or idiopathic neurodegenerative diseases. Nonetheless, with the known association between *PANK2* mutations and PKAN, and the list of clinical, radiographical, and molecular evidence available, the identification of PKAN should now be made more easily and more accurately.

## Acknowledgement

The authors would like to express their gratitude to Mr Simon Chow for his assistance in laboratory work on molecular studies and his participation in literature research.

## References

- Zhou B, Westaway SK, Levinson B, Johnson MA, Gitschier J, Hayflick SJ. A novel pantothenate kinase gene (*PANK2*) is defective in Hallervorden-Spatz syndrome. *Nat Genet* 2001;28:345-9.
- Perry TL, Norman MG, Yong VW, et al. Hallervorden-Spatz disease: cysteine accumulation and cysteine dioxygenase deficiency in the globus pallidus. *Ann Neurol* 1985;18:482-9.
- Hayflick SJ. Unraveling the Hallervorden-Spatz syndrome: pantothenate kinase-associated neurodegeneration is the name. *Curr Opin Pediatr* 2003;15:572-7.
- Hayflick SJ, Westaway SK, Levinson B, et al. Genetic, clinical, and radiographic delineation of Hallervorden-Spatz syndrome. *N Engl J Med* 2003;348:33-40.
- Hartig MB, Hortnagel K, Garavaglia B, et al. Genotypic and phenotypic spectrum of *PANK2* mutations in patients with neurodegeneration with brain iron accumulation. *Ann Neurol* 2006;59:248-56.
- Pellecchia MT, Valente EM, Cif L, et al. The diverse phenotype and genotype of pantothenate kinase-associated neurodegeneration. *Neurology* 2005;64:1810-2.
- Fung GP, Chan KY. Cervical myelopathy in an adolescent with Hallervorden-Spatz disease. *Pediatr Neurol* 2003;29:337-40.
- Lam CW, Xie J, To KF, et al. A frequent activated smoothened mutation in sporadic basal cell carcinomas. *Oncogene* 1999;18:833-6.
- Hayflick SJ, Hartman M, Coryell J, Gitschier J, Rowley H. Brain MRI in neurodegeneration with brain iron accumulation with and without *PANK2* mutations. *AJNR Am J Neuroradiol* 2006;27:1230-3.
- Baumeister FA, Auer DP, Hortnagel K, Freisinger P, Meitinger T. The eye-of-the-tiger sign is not a reliable disease marker for Hallervorden-Spatz syndrome. *Neuropediatrics* 2005;36:221-2.
- Ching KH, Westaway SK, Gitschier J, Higgins JJ, Hayflick SJ. HARP syndrome is allelic with pantothenate kinase-associated neurodegeneration. *Neurology* 2002;58:1673-4.
- Egan RA, Weleber RG, Hogarth P, et al. Neuro-ophthalmologic and electroretinographic findings in pantothenate kinase-associated neurodegeneration (formerly Hallervorden-Spatz syndrome). *Am J Ophthalmol* 2005;140:267-74.
- Yang Y, Wu Z, Kuo YM, Zhou B. Dietary rescue of fumble—a *Drosophila* model for pantothenate-kinase-associated neurodegeneration. *J Inher Metab Dis* 2005;28:1055-64.