

# Primary tuberculous glossitis in an immunocompetent patient

Prem P Gupta  
Sanjay Fotedar  
Dipti Agarwal  
Pradeep Sansanwal

Tuberculous glossitis is a rare entity that has been described sporadically. Primary tuberculous glossitis, as described in this case report, is still exceptional. A 25-year-old male with no known immunosuppressive disorder presented with a tuberculoma at the base of his tongue. This was confirmed by tongue biopsy and a positive polymerase chain reaction response to the mycobacterium. The patient had a favourable response to anti-tubercular treatment. This highlights the importance of considering tuberculosis in the differential diagnosis of chronic tongue lesions, even in the absence of pulmonary tuberculosis.

## Introduction

According to the World Health Organization (WHO), 2 billion people, or one third of the world's population, are infected with tuberculous bacilli, and the global tuberculosis incidence is growing at 1% a year.<sup>1</sup> Nevertheless, tuberculosis of the tongue is rarely described in the literature. In one series it occurred in only one of 5094 patients who were diagnosed with pulmonary tuberculosis, even though it is usually secondary to pulmonary tuberculosis.<sup>2</sup> Primary tuberculous glossitis is exceedingly rare.<sup>2,3</sup>

## Case report

A 25-year-old male presented at our institute in March 2006 with a 1-month history of a painful lesion on his tongue and discomfort while eating solid food. He had a low-grade intermittent fever and had lost weight. He had a history of smoking bidi (a sort of indigenous cigarette with no filter, frequently smoked in various parts of the world including South-East Asia) for the last 12 years and tobacco chewing for 7 years. There was no history of diabetes, hypertension, or any other significant disease including pulmonary tuberculosis. The patient had been married for the past 3 years and had an active sexual life with his wife only. He denied any extramarital or premarital sex. He was employed in a garment factory. He gave a history of close contact with a fellow factory worker who was diagnosed with smear-positive pulmonary tuberculosis.

On examination, his tongue had a nodular lesion (tuberculoma) on the dorsal surface near the base of the tongue (Fig 1). There was no cervical lymphadenopathy. No other pathology was found on examination of his other systems.

His full blood count, routine biochemical tests, and urine analysis were within normal limits. His serum was non-reactive for HIV-antigens as screened by an enzyme-linked immunosorbent assay. His chest radiographs were clear with no obvious lesion but the tuberculin test was positive with an induration of 18 mm. Sputum induction was done with hypertonic saline and the sputum specimens were negative for acid-fast bacilli. A tongue biopsy revealed a tuberculous granulomatous lesion (Fig 2). Specimens from the lesion were also tested for mycobacterial DNA using polymerase chain reaction (PCR) that detected *Mycobacterium tuberculosis*. The patient was diagnosed with tuberculous glossitis and was given anti-tubercular chemotherapy following the WHO Category-3 regimen (2H<sub>3</sub>R<sub>3</sub>Z<sub>3</sub>/4H<sub>3</sub>R<sub>3</sub>). This regimen was given thrice weekly and included isoniazid, rifampicin, and pyrazinamide for the first 2 months; after which pyrazinamide was stopped while the other two drugs (isoniazid and rifampicin) were continued for 4 months. The patient had a favourable response with complete healing of the tongue lesion along with clinical improvement at the completion of his anti-tubercular chemotherapy.

## Discussion

Tuberculosis of the oral cavity may be either primary or secondary. Secondary tuberculosis is more common among older patients and is usually a complication of pulmonary disease. Primary tuberculosis is unusual and is seen in younger patients; and may be associated with

### Key words

Antitubercular agents; Glossitis;  
Polymerase chain reaction; Tuberculosis

*Hong Kong Med J* 2007;13:330-1

Postgraduate Institute of Medical  
Sciences, Rohtak, India:  
Department of Respiratory Medicine  
PP Gupta, MD, FNCCP  
S Fotedar, MB, BS, DTCD  
Department of Physiology  
D Agarwal, MB, BS, MD  
Department of Pathology  
P Sansanwal, MB, BS, MD

Correspondence to: Dr PP Gupta  
E-mail: gparkas@yahoo.co.in

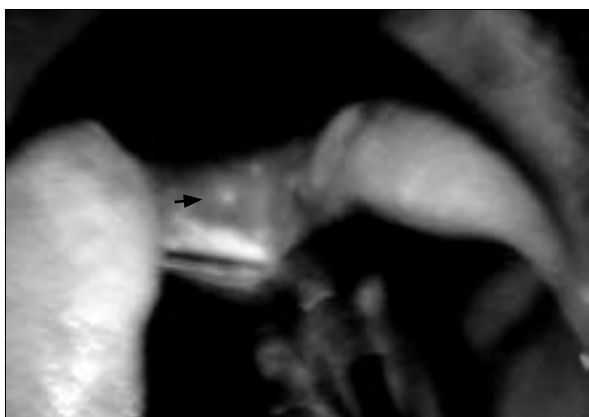

FIG 1. Photograph of the oral cavity showing the tuberculoma type tuberculous glossitis lesion at the dorsal surface near the base of the tongue

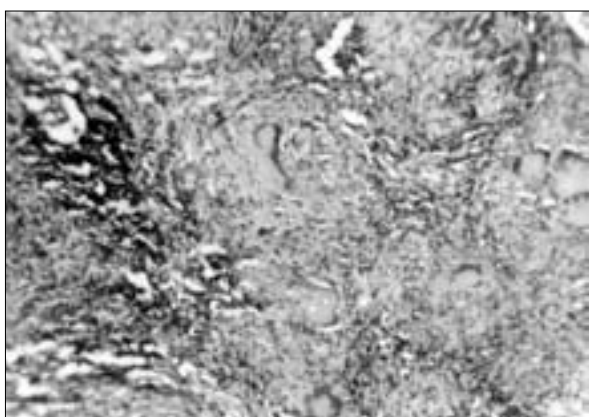


FIG 2. Photomicrograph of the lesion revealing the tuberculous granulomatous lesion

## 發生在免疫功能正常患者身上的原發性結核舌炎

結核舌炎頗為罕見，文獻的記述零散。本文所描述的原發性結核舌炎更是目前相當特殊的病例。患者25歲，男性，並無免疫抑制紊亂問題，在舌根生成結核瘤，經過舌活檢，以及對分枝桿菌呈陽性聚合酶鏈反應而證實。患者對抗結核療法反應良好。本例突顯了在對慢性舌瘤作鑒別診斷時，即使病人無肺結核，亦須考慮結核病的可能性。

and involves the tongue near the tip. The ulcers are shallow, oval, and indolent, have undermined margins and are painful due to intact nerve endings. Other tuberculosis lesions—diffuse glossitis, fissures, or tuberculomas—have also been reported but they are exceedingly rare. Although the dorsal surface is more commonly involved, involvement of the ventral surface has also been described.<sup>6</sup> The differential diagnosis of tongue tuberculous lesions includes malignancy, granulomatous disease, syphilis, traumatic and aphthous ulcers, and mycotic infections. Our patient had a tuberculoma as his tuberculous lesion, on the dorsal surface near the base of the tongue.

Though it is difficult to be certain, it is most likely that our patient acquired the infection from contact with a fellow factory worker who was diagnosed with smear-positive pulmonary tuberculosis. He has chewed tobacco for 7 years, which might have contributed towards the development of the tongue lesions. The definitive diagnosis of tuberculous glossitis often requires a biopsy of the lesion for histopathological examination and confirmation of the presence of mycobacterium or evidence of its DNA (by PCR). Patients with tuberculous glossitis respond well to anti-tubercular treatment because the tongue is highly vascular. In our patient, the tongue healed completely after completion of a course of anti-tubercular chemotherapy.

To conclude, although tuberculosis of the tongue is rarely observed, it should be taken into consideration in the differential diagnosis of chronic tongue lesions, even in the absence of pulmonary tuberculosis.

cervical lymphadenopathy. According to the medical literature, both primary and secondary tuberculosis of the tongue and oral cavity are rare and occur in less than 0.2% of all cases of tuberculosis.<sup>4</sup> The tongue is the most commonly affected structure in the oral cavity. Tongue tuberculosis is more common among males than females.

Three forms of oral tuberculosis have been described: acute miliary, chronic ulcerative, and lupus vulgaris.<sup>5</sup> The chronic ulcerating type is always secondary to advanced pulmonary tuberculosis<sup>6</sup>

## References

1. Tuberculosis—the global burden. Trends in TB incidence in 9 regions of the world (2005). WHO website: [www.who.int/entity/tb/publications/global\\_report/en/index.html](http://www.who.int/entity/tb/publications/global_report/en/index.html). Accessed 19 Mar 2006.
2. Gupta A, Shinde KJ, Bhardwaj I. Primary lingual tuberculosis: a case report. *J Laryngol Otol* 1998;112:86-7.
3. Iype EM, Ramdas K, Pandey M, et al. Primary tuberculosis of the tongue: report of three cases. *Br J Oral Maxillofac Surg* 2001;39:402-3.
4. Prada JL, Kindelan JM, Villanueva JL, Jurado R, Sanchez-Guijo P, Torre-Cisneros J. Tuberculosis of the tongue in two immunocompetent patients. *Clin Infect Dis* 1994;19:200-2.
5. Koksall D, Acican T, Kanat F, Durmaz G, Ataoglu O, Cobanlı B. Tuberculous ulcer of the tongue secondary to pulmonary tuberculosis. *Aust NZ J Med* 2000;30:518-9.
6. Arinç S, Arinç B, Bayal I, et al. Secondary lingual tuberculosis: a case report. *Turkish Respir J* 2003;4:25-6.