

EMC Chau 周慕慈  
 KYF Fan 范瑜茵  
 WH Chow 周榮興

## Cardiac sarcoidosis: a potentially fatal but treatable form of infiltrative heart disease

### 心臟結節病：一種可以致命但可治癒的入侵性心臟病

Cardiac sarcoidosis is a rare but important differential diagnosis in patients who present with progressive heart failure and arrhythmia. It may be diagnosed on endomyocardial biopsy. An excellent response can be achieved with steroid therapy in the early acute inflammatory stage. Progression of the disease may lead to end-stage heart failure that requires implantation of a permanent pacemaker, implantable cardioverter-defibrillator, or mechanical circulatory support as a bridge to heart transplantation. We present three Hong Kong Chinese patients with cardiac sarcoidosis.

心臟結節病是一種罕見病症，但如果病人出現漸進性心臟衰竭和心律失常，便有可能患上此病。此病可以透過心內膜活組織檢查來診斷。如果在急性發炎階段初期以類固醇治療，會有良好效果。病情惡化會引致末期心臟衰竭，病人需要植入永久心臟起搏器、植入性心律除顫器或在等候心臟移植期間使用機械性輔助系統。我們報告三名患有心臟結節病的香港華籍病人的情況。

#### Introduction

Sarcoidosis is a multi-system granulomatous disorder that mainly affects the lungs, skin, eyes, and lymphoreticular system. Myocardial involvement with sarcoid is found at autopsy in about 25% of patients with the disease<sup>1</sup> although only 5% of all sarcoid patients have clinically significant cardiac symptoms such as congestive heart failure, heart block, ventricular arrhythmia, or sudden death. We have treated three Hong Kong Chinese patients with cardiac sarcoidosis. They developed a low cardiac output with cardiogenic shock. One patient was diagnosed with cardiac sarcoidosis on endomyocardial biopsy and had an initially favourable response to steroid therapy. The other two patients had undergone heart transplantation with previously undiagnosed sarcoidosis.

#### Case reports

##### Case 1

A 34-year-old woman with a history of anterior uveitis, and parotid and lymph node swelling was referred to our unit in 1995 for further investigation of recent-onset congestive heart failure. Echocardiogram revealed impaired left ventricle (LV) contractility with an ejection fraction (EF) of 17%. Coronary angiogram was normal and right heart catheterization showed a cardiac index of 1.65 L·min<sup>-1</sup>·m<sup>-2</sup> and pulmonary vascular resistance of 1.7 Wood units. Endomyocardial biopsy demonstrated granulomatous inflammation with lesions varying from focal to large and confluent. The granulomas were non-necrotising and composed of histiocytes, giant cells, and lymphocytes, consistent with sarcoidosis. She was prescribed oral steroid therapy (prednisolone, 1 mg/kg per day) and following 8 weeks of therapy, there was haemodynamic improvement as shown by a cardiac index of 2.18 L·min<sup>-1</sup>·m<sup>-2</sup> on cardiac catheterization and reduced LV size and EF of 55% on echocardiogram. There was correspondingly reduced granulomatous inflammation on endomyocardial biopsy. The dose of prednisolone was slowly tapered to a maintenance dose of 5 mg per day and azathioprine was added. One year later, cardiac catheterization showed a cardiac index of 2.81 L·min<sup>-1</sup>·m<sup>-2</sup> and no evidence of inflammation on endomyocardial

#### Key words:

Arrhythmia;  
 Cardiomyopathies;  
 Heart transplantation;  
 Sarcoidosis

#### 關鍵詞：

心律失常；  
 心肌疾病；  
 心臟移植；  
 結節病

Hong Kong Med J 2006;12:65-7

Department of Cardiology, Grantham Hospital, Wong Chuk Hang, Hong Kong

EMC Chau, MB, BS, FRCP  
 KYF Fan, MB, ChB, FRCP  
 WH Chow, MB, BS, FRCP

Correspondence to: Dr EMC Chau  
 (e-mail: echau@hkucc.hku.hk)

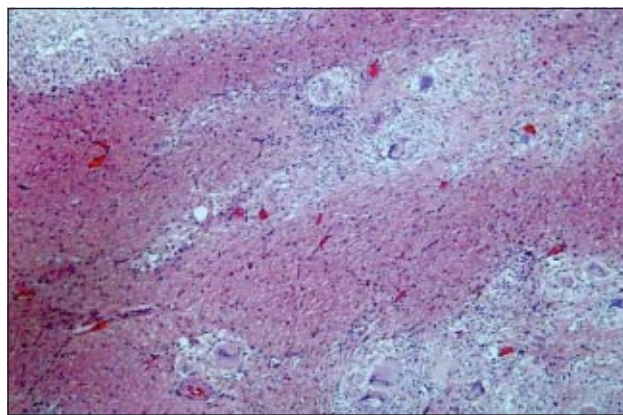
biopsy. She was weaned off all immunosuppression and maintained on angiotensin-converting enzyme inhibitor only. She remained well for about 4 years until 2000 when she again developed symptoms of heart failure and left ventricular EF fell to 20%. Electrocardiogram showed complete heart block and a biventricular pacemaker was implanted. Repeated endomyocardial biopsy showed no inflammation but, in view of the possibility of sampling error, she was treated empirically with a course of steroid therapy. There was little improvement in LV systolic function so steroid therapy was discontinued after 6 months. She remained in New York Heart Association functional class II to III until November 2004 when she was admitted with decompensated heart failure due to the development of atrial fibrillation. She required intravenous inotropic therapy and intra-aortic balloon pump (IABP) for 7 weeks. Heart transplantation was performed in May 2005 and histopathology of the explanted heart showed replacement-type fibrosis and no inflammatory cells or granulomas.

### Case 2

A 37-year-old man presented in 2000 with chest pain and palpitations. Coronary angiogram was normal and he was found to have impaired LV contractility and ventricular tachycardia. He was treated with routine heart failure therapy and implantation of a biventricular cardioverter-defibrillator. He was admitted to hospital in 2002 with recurrent episodes of ventricular tachycardia and cardiogenic shock. He was transferred to our unit with intravenous inotropic therapy and intravenous amiodarone. An IABP was inserted because of hypotension and peritoneal dialysis was commenced for treatment of his renal failure. After 9 days of IABP support, he underwent orthotopic heart transplantation. Pathology of the explanted heart showed severe fibrosis and florid inflammation with non-caseating granulomas (Fig) in both ventricles including the interventricular septum. Gallium scan revealed no sarcoidosis anywhere else and high-resolution computed tomography of the thorax showed no mediastinal lymphadenopathy. Following transplantation, he was maintained on long-term immunosuppression with cyclosporine, mycophenolate mofetil, and prednisolone. Routine post-transplantation endomyocardial biopsies revealed grade 3A rejection at 6 months and no recurrence of sarcoidosis up to 30 months after transplantation.

### Case 3

A 29-year-old man presented to his general practitioner in March 2003 with heart failure and ventricular tachycardia. Coronary angiogram was normal. Endomyocardial biopsy was not performed. He was prescribed medication appropriate for heart failure and underwent implantation of a single-chamber cardioverter-defibrillator. In July 2004, due to further deterioration in heart failure, the implantable cardioverter-defibrillator (ICD) was upgraded to one with cardiac resynchronisation therapy (biventricular ICD). Despite optimal medical therapy and oral amiodarone (300 mg per day), he continued to have non-sustained ventricular



**Fig. Staining of the myocardium showing multiple discrete non-necrotising granulomas with epithelioid cells and multi-nucleated giant cells (H&E, x10)**

arrhythmias of different morphologies and was admitted to our unit in January 2005 with low-output cardiac failure. He required insertion of an IABP and continuous infusion of intravenous dopamine, dobutamine, and levosimendan as well as intravenous amiodarone for control of ventricular tachycardia. Orthotopic heart transplantation was performed after 16 days of inotropic and IABP support. Histopathology of the explanted heart showed fibrosis and interstitial inflammation with non-caseating granulomas with epithelioid cells and multi-nucleated giant cells, compatible with a diagnosis of cardiac sarcoidosis. Gallium scan showed no increased uptake in other organs and bronchial biopsy was also negative for sarcoid.

## Discussion

### Racial difference

Sarcoidosis is a granulomatous disease of unknown aetiology that affects young patients. It has a predilection for certain ethnic groups such as the Afro-americans but is considered rare in Chinese population.<sup>2</sup> In western countries, pulmonary sarcoidosis is a significant cause of death in sarcoid patients, but in Japanese sarcoid patients, the main cause of death is cardiac sarcoidosis.<sup>3,4</sup> In a comparative study of cardiac sarcoidosis in Japanese, Afro-americans, and United States Caucasians, the incidences of cardiac sarcoid granulomas were 67.8%, 21.2%, and 13.7%, respectively.<sup>5</sup> This corresponds to a significantly higher rate of cardiac sarcoid deaths in the Japanese population.

### Difficulty in antemortem diagnosis of cardiac sarcoidosis

In cardiac sarcoidosis, the main causes of death are arrhythmia and progressive congestive heart failure. Common arrhythmias include premature ventricular beats, ventricular tachycardia, and complete heart block. Interestingly, most patients with cardiac sarcoidosis have little or no clinical evidence of extra-cardiac sarcoid involvement. Sudden death may be the first manifestation of cardiac sarcoidosis and it is therefore not surprising

that many cases of isolated cardiac sarcoidosis are only diagnosed postmortem. Transvenous endomyocardial biopsy may assist in making an antemortem diagnosis, as in our case 1, with the finding of non-caseating granulomas. Nonetheless a negative biopsy does not rule out cardiac sarcoidosis due to a patchy distribution of the pathology and predilection of granulomas for the cephalad portion of the septum that is less accessible to biopsy. The histological diagnostic rate of cardiac sarcoidosis using endomyocardial biopsy has a low sensitivity of 19.2%.<sup>6</sup>

Other proposed diagnostic tests for cardiac sarcoidosis include myocardial scintigraphy using thallium-201. This shows a decreased uptake in the fibrogranulomatous lesions in the presence of normal coronary anatomy and disappearance of these perfusion defects during exercise or administration of dipyridamole (so-called 'reverse distribution' phenomenon).<sup>7</sup> A small study revealed that the combination of thallium-201 and gallium-67 scintigraphy is useful not only in the diagnosis of cardiac sarcoidosis, but also in the prediction of response to corticosteroids.<sup>8</sup> Magnetic resonance imaging can be useful in the diagnosis and monitoring of response to treatment<sup>9</sup> but is contra-indicated in patients with a pacemaker or ICD.

### Response to treatment

Cardiac sarcoidosis should be treated with corticosteroid therapy with or without other immunosuppressive agents.<sup>10</sup> A recent study<sup>11</sup> showed that patients with mild-to-moderate impaired left ventricular function (EF, 30-54%) benefited most from steroid therapy, whereas those with a severely reduced left ventricular EF of less than 30% in the late stage of disease did not benefit probably because of irreversible myocardial damage and fibrosis. This is in keeping with our experience with case 1, which showed a dramatic response to corticosteroid therapy during the acute inflammatory stage but no response in the late stage of the disease.

Ventricular arrhythmias are common in cardiac sarcoidosis but are often refractory to anti-arrhythmic drugs including amiodarone,<sup>12</sup> as seen in cases 2 and 3. Implantation of an ICD is then indicated. With the progress in prevention and treatment of ventricular arrhythmias, the primary cause of death in cardiac sarcoidosis has changed from sudden death to congestive heart failure. Cardiac resynchronisation therapy, which may be beneficial to heart failure patients with left ventricular dyssynchrony, did not appear to benefit any of our three patients. There have been case reports of cardiac transplantation for undiagnosed cardiac sarcoidosis,<sup>13,14</sup> similar to our cases 2 and 3. Sarcoidosis can recur following heart transplantation and can be controlled with augmentation of corticosteroid therapy without affecting allograft function.<sup>15</sup> In patients in whom cardiac sarcoidosis progresses to cardiogenic shock, use of mechanical circulatory support, such as an intra-aortic balloon pump or ventricular assist device, should be considered a bridge to transplantation.

### Conclusion

Cardiac sarcoidosis should be considered a differential diagnosis in young patients who present with heart failure and arrhythmias, especially ventricular arrhythmias unresponsive to amiodarone. Unlike lymphocytic and giant cell myocarditis, which is rapidly progressive, cardiac sarcoidosis may run a more indolent but relentless course with worsening heart failure that leads to cardiogenic shock. Once the diagnosis is made or strongly suspected, aggressive treatment with corticosteroid should be commenced, especially when there is only mild-to-moderately impaired LV function and a favourable response can be achieved. Arrhythmias should be treated appropriately with implantation of a permanent pacemaker or ICD. In patients with heart failure that is refractory to conventional treatment, heart transplantation is a feasible option.

### Acknowledgement

We thank Dr Elaine Wang from the Department of Pathology, Grantham Hospital, for providing the histopathology slide.

### References

1. Silverman KJ, Hutchins GM, Bulkley BH. Cardiac sarcoid: a clinicopathologic study of 84 unselected patients with systemic sarcoidosis. *Circulation* 1978;58:1204-11.
2. Leung WK, Lei KI, Yim A, Sit YK, Lai CK, Leung R. Sarcoidosis in a Hong Kong Chinese woman. *Hong Kong Med J* 1998;4:333-6.
3. Iwai K, Tachibana T, Takemura T, Matsui Y, Kitaichi M, Kawabata Y. Pathological studies on sarcoidosis autopsy. I. Epidemiological features of 320 cases in Japan. *Acta Pathol Jpn* 1993;43:372-6.
4. Iwai K, Takemura T, Kitaichi M, Kawabata Y, Matsui Y. Pathological studies on sarcoidosis autopsy. II. Early change, mode of progression and death pattern. *Acta Pathol Jpn* 1993;43:377-85.
5. Iwai K, Sekiguti M, Hosoda Y, et al. Racial difference in cardiac sarcoidosis incidence observed at autopsy. *Sarcoidosis* 1994;11:26-31.
6. Uemura A, Morimoto S, Hiramitsu S, Kato Y, Ito T, Hishida H. Histologic diagnostic rate of cardiac sarcoidosis: evaluation of endomyocardial biopsies. *Am Heart J* 1999;138:299-302.
7. Tellier P, Paycha F, Antony I, et al. Reversibility by dipyridamole of thallium-201 myocardial scan defects in patients with sarcoidosis. *Am J Med* 1988;85:189-93.
8. Okayama K, Kurata C, Tawarahara K, Wakabayashi Y, Chida K, Sato A. Diagnostic and prognostic value of myocardial scintigraphy with thallium-201 and gallium-67 in cardiac sarcoidosis. *Chest* 1995;107:330-4.
9. Matsuki M, Matsuo M. MR findings of myocardial sarcoidosis. *Clin Radiol* 2000;55:323-5.
10. Chapelon-Abrie C, de Zuttere D, Duhaut P, et al. Cardiac sarcoidosis: a retrospective study of 41 cases. *Medicine (Baltimore)* 2004;83:315-34.
11. Chiu CZ, Nakatani S, Zhang G, et al. Prevention of left ventricular remodeling by long-term corticosteroid therapy in patients with cardiac sarcoidosis. *Am J Cardiol* 2005;95:143-6.
12. Tarantini G, Menti L, Angelini A, Martini B, Thiene G, Daliento L. Life-threatening ventricular arrhythmias associated with giant cell myocarditis (possibly sarcoidosis). *Am J Cardiol* 2000;85:1280-2.
13. Valantine HA, Tazelaar HD, Macoviak J, et al. Cardiac sarcoidosis: response to steroids and transplantation. *J Heart Transplant* 1987;6:244-50.
14. Donsky AS, Escobar J, Capehart J, Roberts WC. Heart transplantation for undiagnosed cardiac sarcoidosis. *Am J Cardiol* 2002;89:1447-50.
15. Oni AA, Hershberger RE, Norman DJ, et al. Recurrence of sarcoidosis in a cardiac allograft: control with augmented corticosteroids. *J Heart Lung Transplant* 1992;11:367-9.