

YM Wan 溫耀明
 KC Wong 黃家俊
 KH Ma 馬光漢

Endoscopic-guided adenoidectomy using a classic adenoid curette: a simple way to improve adenoidectomy

改進增殖體刮除術的簡單方法：利用傳統增殖體刮匙進行內窺鏡導引增殖體刮除術

A total of 13 adenoidectomies using a nasal endoscopic-guided transoral adenoid curette (not yet a published standardised method) were performed to treat snoring. Nasal endoscopy allows easy assessment of the size of the adenoids and improves the accuracy of the adenoidectomy. This technique is particularly useful for paediatric patients who have small oral cavities. The assessment and excision of the adenoids in these cases are often difficult. Using the nasal endoscope, the curette can be accurately inserted at the superior border of the adenoid, allowing the complete transoral removal of the main bulk of the adenoid tissue. All 13 patients showed considerably decreased snoring and improvements in the quality of sleep as reported by the parents and the patients. We believe that nasal endoscopic-guided transoral adenoidectomy is a viable alternative to classic adenoidectomy. This technique also has the advantage of using commonly available simple ear, nose, and throat instruments.

本文報告13個利用鼻內窺鏡導引的增殖體刮匙進行增殖體刮除術以治療打鼻鼾的病例（這種方法還未正式公佈為標準療法）。鼻內窺鏡易於估計腺樣增殖體的大小，並能提高增殖體刮除術的準繩度。這項技術對口腔細小的病童尤其適合。由於在評估他們腺樣增殖體的大小，以至進行切除術尤其困難，使用鼻內窺鏡可把刮匙準確置入腺樣增殖體的上緣並經口完整切除增殖體組織的主體。根據病童及病童家長報告，所有接受此項治療的病童皆有明顯改善打鼻鼾的情況，睡眠質量亦有所改善。我們相信，鼻內窺鏡導引增殖體刮除術是傳統方法外的另一選擇，而可使用普遍的耳鼻喉科醫療工具，亦是這項新技術的優異之處。

Key words:

Adenoidectomy;
 Airway obstruction;
 Curettage;
 Endoscopies;
 Snoring

關鍵詞：

增殖體刮除術；
 氣道阻塞；
 刮除術；
 內窺鏡；
 打鼻鼾

Hong Kong Med J 2005;11:42-4

ENT Department, Yan Chai Hospital, Tsuen Wan, Hong Kong

YM Wan, FRCS (Glasg), FHKAM (Otorhinolaryngology)
 KC Wong, MB, BS
 KH Ma, FRCS (Edin), FHKAM (Otorhinolaryngology)

Correspondence to: Dr YM Wan
 (e-mail: wanymsimon@graduate.hku.hk)

Introduction

Adenoidectomy is a common procedure for treating paediatric ear, nose, and throat (ENT) patients. Nowadays, it is used to treat enlarged adenoids that have not responded to conservative treatments, which are indicated in obstructive sleep apnoea, recurrent serous otitis media, and resistant rhinosinusitis.

Typically, the adenoids might not have been visualised during clinical examination in ENT clinics because the paediatric patient may not cooperate during a mirror or endoscopic examination. Furthermore, lateral radiographs of adenoids are not routinely investigated before an adenoidectomy. In many cases, the size of the adenoids is assessed by a transoral finger palpation or a mirror examination following the anterior

retraction of soft palate by a nasal catheter. We have previously used the adenoid curette technique transorally guided by an indirect mirror following soft palate retraction. Over the past 3 years, from March 2001 to April 2004, we performed 13 adenoidectomies by nasal endoscopic-guided transoral adenoidectomy (EGA). The adenoid curette was inserted transorally guided by transnasal endoscopy, and the main midline adenoid bulk was removed if the adenoid was enlarged.

Methods

Of the 13 cases, 12 were paediatric patients who had presented with snoring and were suspected of having obstructive sleep apnoea. The 12 (six male and six female) patients' age ranged from 4 to 11 years. The remaining adult female patient was 38 years of age. The follow-up duration ranged from 3 to 18 months. Preoperatively, the parents and patients were asked to grade the severity of the snoring using the visual analog scale—grade 0 denoting no snoring and grade 10 indicating marked snoring that would wake those sharing the room with the patient. Postoperatively, they were again asked to grade the snoring during follow-up after 3 to 6 months. Postoperative improvements in the quality of sleep (reduced apnoea and breathing difficulties) were also determined.

Nine patients had tonsillectomy and EGA, whereas the other four patients had only EGA. The operations were performed under general anaesthesia using orotracheal intubation. The adenoidectomy was performed prior to the tonsillectomy in those nine cases. The patients were operated on in a supine position with the neck extended. The nasal cavities and nasopharynx were examined with a zero-degree nasal endoscope (2.7 mm) without any vasoconstrictor packing. If the nasal cavity was congested, ribbon gauze soaked with 0.05% oxymetazoline solution was inserted for 5 minutes to shrink the nasal mucosa. A throat pack was also inserted to prevent any blood from entering the trachea.

An EGA was performed in the cases of nasal obstruction caused by enlarged adenoids. A Boyle-Davis mouth gag was inserted to open the mouth widely as during the classic adenoidectomy. A suitably sized Beckmann adenoid curette (Meddis, Downs, United Kingdom) was placed transorally into the nasopharynx. Under nasal endoscopic guidance, the blade of the adenoid curette was placed just above the superior border of the adenoid (Fig). The lateral ends of the blade should just be away from the Eustachian tube area on both sides. The nasal endoscope was then

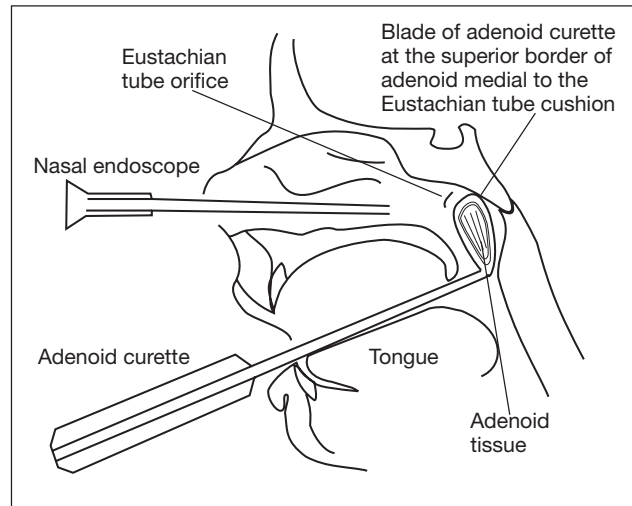


Fig. Transoral adenoidectomy using a nasal endoscopic-guided curette

taken out from the nose and the adenoid was curetted with a sustained force as in conventional curettage. Transoral packing gauze was used for 3 to 5 minutes to control any bleeding, which usually stopped spontaneously without the need to cauterise the adenoid area. A tonsillectomy was then performed if required.

In the initial four cases, the lateral part of the adenoid was first removed transnasally using nasal punch forceps and a straight nasal microdebrider (commonly used in the endoscopic sinus surgery). The midline adenoid bulk was then removed transorally by curettage as described previously. In the later nine cases including the adult patient, we found that prior removal of the lateral part using punch forceps and a debrider was not necessary, and a suitably sized adenoid curette was able to remove the main bulk, including the lateral part of the adenoids.

Results

All of the patients did not have any postoperative complications. Twelve patients attended the postoperative follow-up to complete the snoring and quality-of-sleep assessments. The other patient did not attend the follow-up but the parents agreed to answer the assessment questions by telephone. The snoring score and the quality of sleep indicated considerable improvements in all of the patients. The average snoring score improved from 8 preoperatively to 1 postoperatively. All the parents and patients were satisfied with the improvement in the quality of sleep with regard to apnoea and the sleep breathing difficulties. These improvements could be attributed to the tonsillectomy and adenoidectomy in nine cases,

and to the adenoidectomy in four cases. Two particular cases are interesting and are discussed below:

Case 1

The 5-year-old patient, with probable obstructive sleep apnoea, had a tonsillectomy and adenoidectomy by the conventional curettage method to treat the snoring 14 months previously. The operation was uneventful; however, the parent did not notice any subsequent improvement in the snoring. Radiographs of the adenoids 1 year later showed a marked adenoid shadow obstructing the choana. An EGA was performed on this patient and the snoring and sleep problems were successfully resolved.

Case 2

The 6-year-old patient had a history of bilateral serous otitis media and snoring which was treated with tonsillectomy, bilateral myringotomy, and grommet insertion. The surgeon, at that time, claimed that the adenoid was not enlarged when examined by palpation; hence, an adenoidectomy was not performed. The snoring improved only minimally as reported by the parent. However, approximately 20 months later, there was recurrent serous otitis media and considerable snoring. A radiograph of the adenoids showed the complete obstruction of the choana. An EGA was performed on this patient and the snoring completely subsided.

Discussion

Several adenoidectomy methods have been well described in the literature. Adenoid curette guided by an indirect transoral mirror and a headlight is a simple and quick procedure^{1,2} that has already been in use for a long time. This is a difficult technique to teach the ENT trainees and good results can only be achieved by experienced ENT surgeons. Modern special equipments, such as curved suction electrical coagulator^{1,3,4} and the curved microdebrider shaver transorally^{2,5-7} guided by a transoral indirect mirror or a 45-degree endoscope, have successfully been used. The combined method of the conventional transoral curette with a transoral curved microdebrider shaver, endoscopic transnasal forceps and microdebrider has also been described.⁷⁻⁹

Results of this study show that EGA has a number of advantages. Nasal endoscopy allows easy size assessment of the adenoid and improves the accuracy of the adenoidectomy via a transoral curette. This method is particularly important for younger paediatric patients with smaller oral cavities, because the size assessment of the adenoids by conventional

palpation and mirror examination is challenging, and the placement of the adenoid curette guided by the indirect mirror is difficult. All these problems can be solved by the use of a nasal endoscope, which allows accurate placement of the adenoid curette at the superior border of the adenoids. This positioning allows the complete transoral removal of the main bulk of the adenoid without the need for nasal punch forceps and a microdebrider. Teaching this method to trainee surgeons is much easier when combined with the video monitoring facilities. Furthermore, sophisticated instruments are not required, which can increase the cost-effectiveness.

In all cases, the EGA curettage method is sufficient to remove the main piece of the adenoids in one attempt. In contrast, the adenoid tissue is removed in multiple small pieces in the classic blind curette adenoidectomy method (according to our past experience and observation of adenoidectomy by other ENT surgeons). It is our impression that the adenoid tissue removed during EGA is more substantial and seems to be greater in total mass compared with the classic adenoidectomy. Therefore, the use of EGA allows a more complete removal of the adenoid and in a more precise manner compared with conventional methods. In our experience, there is only a minimal increase in the operating time. Although further studies might be required to confirm the above advantages, we believe EGA is a good alternative method for adenoidectomy.

References

1. Elluru RG, Johnson L, Myer CM 3rd. Electrocautery adenoidectomy compared with curettage and power-assisted methods. *Laryngoscope* 2002;112:23-5.
2. Stanislaw P Jr, Koltai PJ, Feustel PJ. Comparison of power-assisted adenoidectomy vs adenoid curette adenoidectomy. *Arch Otolaryngol Head Neck Surg* 2000;126:845-9.
3. Hartley BE, Papsin BC, Albert DM. Suction diathermy adenoidectomy. *Clin Otolaryngol* 1998;23:308-9.
4. Walker P. Pediatric adenoidectomy under vision using suction-diathermy ablation. *Laryngoscope* 2001;111:2173-7.
5. Koltai PJ, Chan J, Younes A. Power-assisted adenoidectomy: total and partial resection. *Laryngoscope* 2002;112:29-31.
6. Rodriguez K, Murray N, Guarisco JL. Power-assisted partial adenoidectomy. *Laryngoscope* 2002;112:26-8.
7. Ku PK, Pak MW, van Hasselt CA. Combined transoral and transnasal power-assisted endoscopic adenoidectomy by StraightShot[®] microdebrider and Endoscrub[®] device. *Annals of College of Surgery in Hong Kong* 2002;6:83-6.
8. Huang HM, Chao MC, Chen YL, Hsiao HR. A combined method of conventional and endoscopic adenoidectomy. *Laryngoscope* 1998;108:1104-6.
9. Becker SP, Roberts N, Coglianesi D. Endoscopic adenoidectomy for relief of serous otitis media. *Laryngoscope* 1992;102:1379-84.